

# Frequency of Intestinal Metaplasia in Dyspeptic Patients in Northern Iraq

Arkan A. Al-Esawi<sup>1</sup>, Haitham N. Al-Koubaisi<sup>2</sup>, Muhammed Tafash<sup>3</sup>

## *Abstract*

**Background:** Intestinal metaplasia is a paracancerous lesion affecting the gastric mucosa in patients with chronic gastritis. Prevalence of intestinal metaplasia is different from region to another; In Iraq there is no available data (at least by the Ministry of Health ) covering this subject.

**Objectives:** To estimate the frequency of intestinal metaplasia (IM) in dyspeptic patients in Northern Iraq. Also, to assess the age and sex distribution of IM. Further, to assess the presence of *Helicobacter pylori* organisms in gastric mucosa that got IM.

**Materials and Methods:** A total number of 476 antral gastric biopsies were collected in Al-Sulaymaniyah GIT-Centre and examined histologically to detect intestinal metaplasia and then these biopsies stained by Giemsa to detect *H.pylori* organisms.

**Results:** The frequency of intestinal metaplasia in the antral gastric mucosa of dyspeptic patients was 8.19 %. More than 90% of patients were above the age of 40 years and there was no significant gender predominance. *H.pylori* colonization in gastric mucosa is significantly decreased in case of IM.

**Keywords:** Intestinal metaplasia , dyspeptic ,chronic gastritis , Iraq.

---

<sup>1</sup> Al-Anbar University, College of Medicine , Pathology Department.

<sup>2</sup> Al-Anbar University , College of Medicine, Department of Medicine.

<sup>3</sup> Al-Anbar University , College of Medicine, Surgery Department .

## *Introduction*

Chronic gastritis is defined as presence of chronic mucosal inflammatory changes leading eventually to mucosal atrophy and intestinal metaplasia. In Western world the prevalence of chronic gastritis in the later decades of life is higher than 50%<sup>{1}</sup>.

Intestinal metaplasia refers to replacement of gastric epithelium with columnar and goblet cells of intestinal variety<sup>{2}</sup>.The most common cause of intestinal metaplasia is H.pylori associated chronic gastritis.<sup>{4}</sup>.These metaplastic changes may become dysplastic and constitute a background for development of gastric carcinoma<sup>{1}</sup> and some considered it as a precancerous lesion<sup>{5}</sup>;the risk for such tumor development is greatly increased in patients in whom mucosal inflammation progresses to multifocal mucosal atrophy and intestinal metaplasia<sup>{1}</sup>.

They thought that intestinal type gastric carcinoma "which presents in more than two thirds of gastric cancer" is to be arised from intestinal metaplasia of gastric epithelium, an assumption supported by electron microcopy and immunohistochemical studies<sup>{3}</sup>.

## *Material and Methods*

This study was performed in Iraq in Al-Sulaymaniyah GIT-center by collecting 476 endoscopic antral mucosa biopsies belong to dyspeptic patients came from Kirkuk , Irbil and Duhok in addition to Al-Sulaymaniyah, from Jan/2008-Jul/2008.

Each biopsy contained at least 2 mucosal pieces that submitted to a conventional histological processing and stained with hematoxylin-eosin stain to asses the presence of intestinal metaplasia , all biopsies were submitted to Giemsa stain (a special stain for H.pylori organisms). The age of patients ranged from 15-85 years, (179) were males and (297) were females.

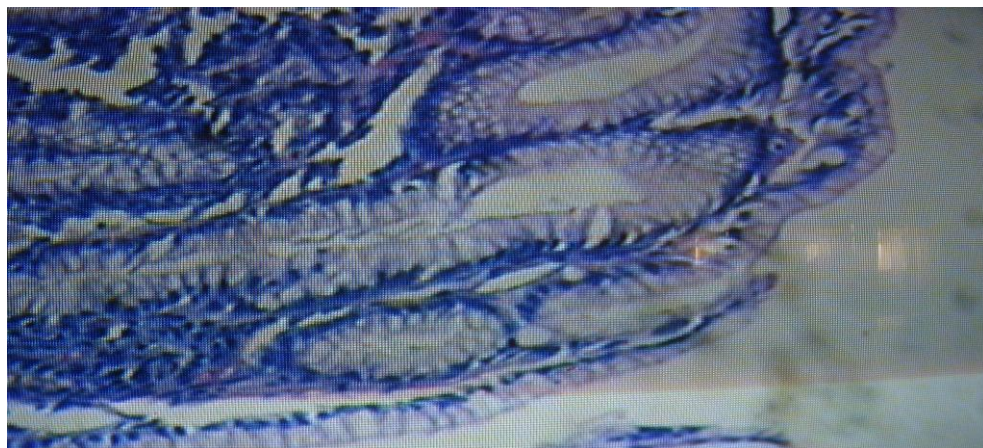

Fig. ( 1 ) A normal antral mucosa (by H&E stain).

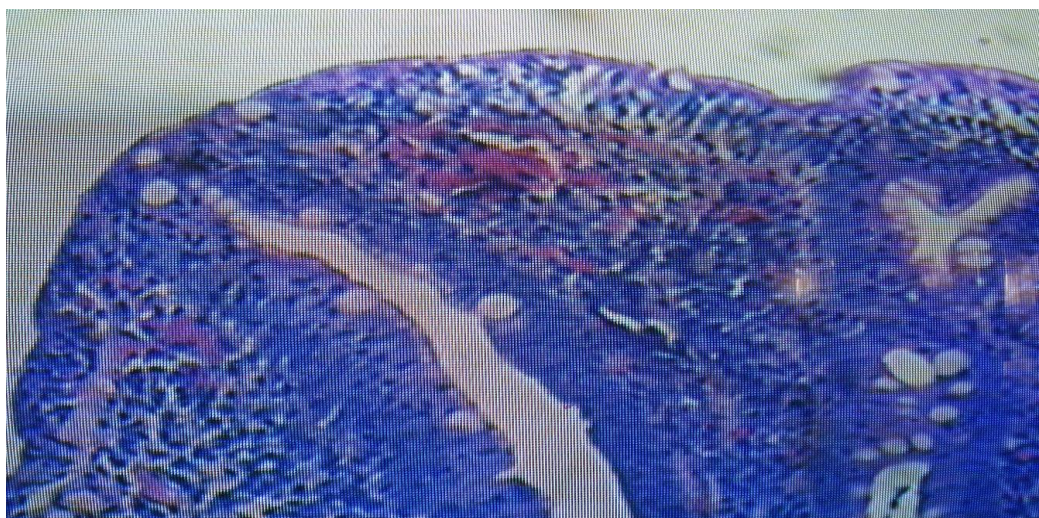


Fig. ( 2 ) Intestinal metaplasia in a background of H.pylori associated with chronic gastritis. (by H&E stain).

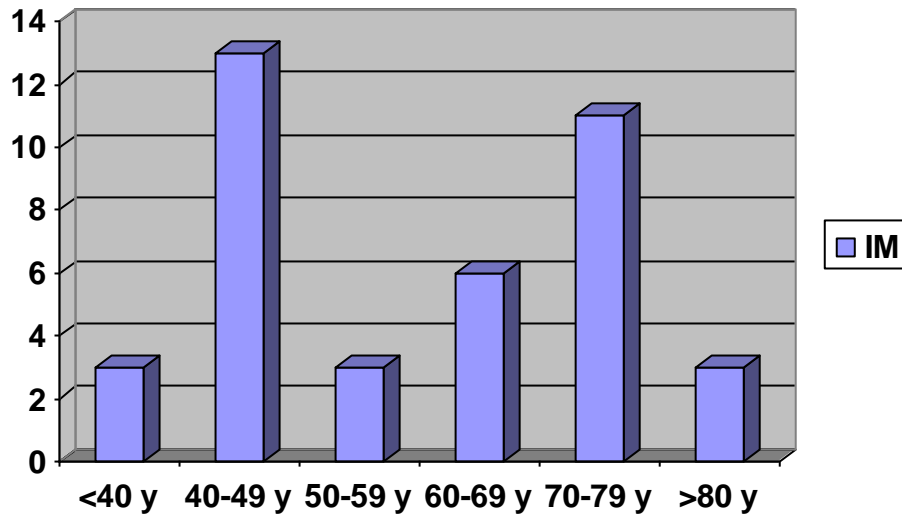
### *Results*

In this study intestinal metaplasia was present in 39 biopsies (14 males & 25 females) out of 476 (frequency = 8.19%). The frequency of intestinal metaplasia according to gender was 7.82% in male & 8.41% in female and by application of Chi-square test this difference was insignificant ( $P > 0.05$ ).

36 biopsies out of total 39 biopsies of intestinal metaplasia (92.31%) were present in patients above the age of 40 years.

The peak age distribution was between 40-49 years that included (33.33%) of cases.

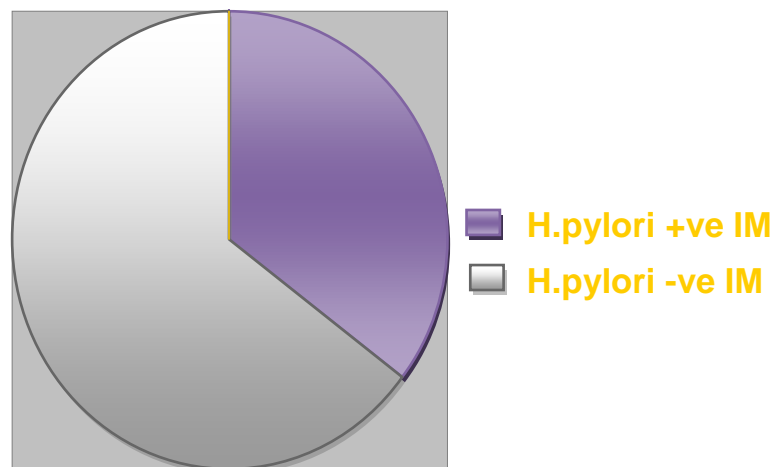
Giemsa stain for *Helicobacter pylori* organisms was positive in 323 cases out of 476 (68.85%) but it was positive only in 14 out of 39 cases of IM (35.89%).



**Chart 1: Age Distribution of Intestinal Metaplasia**

**Table 1. Relationship between H.pylori organisms and IM**

| Diagnoses           | Number of cases | %      |
|---------------------|-----------------|--------|
| IM with H.Pylori    | 14              | 35.89% |
| IM without H.Pylori | 25              | 64.11% |



## Discussion

In the present study the frequency of intestinal metaplasia in patients with dyspepsia was 8.19%, (7.82%) in males and (8.44)% in females, this rate is in agree with Carrilho et al study (8.3%)<sup>(6)</sup> and Hackelberger et al rate in the gastric corpus<sup>(7)</sup>. But it is significantly lower than Kim et al study in Korea(42.5% in males & 32.5% in females)<sup>(8)</sup> and Zhang et al,2005 study in China( 39.9%)<sup>(9)</sup>.These high rates of IM in the Kim HJ et al study in Korea and Zhang et al study in China are in keeping with the high prevalence of gastric carcinoma in these countries and this result gives a confirmatory evidence to the well known concept that considers IM as a premalignant lesion.

The frequency of IM in the present study puts Iraqi population in northern Iraq in the low prevalence area and this result does not differ from the result of a similar study that carried out in Saudi Arabia by Al-Kanawy et al , which reported that the prevalence of IM in Saudi Arabian was 15.2% (Saudi Arabia is considered as a low prevalence area for gastric carcinoma)<sup>(10)</sup> .

In agree with most of the other studies, the current study revealed no significant gender variation among patients with IM (P:>0.05) and the peak age distribution of IM was between 40-49 years.

It is known that *Helicobacter pylori* organisms are present in 90% of antral biopsies with chronic gastritis<sup>(1)</sup>.

In this study Giemsa stain for *Helicobacter pylori* organisms was positive in 68.85% of the antral biopsies and this lower rate of positivity is mostly because not all the studied cases (dyspeptic patients) were having chronic gastritis.

Giemsa stain was positive in 35.89 % (and negative in 64.11% ) of biopsies with IM.

This relative high rate of *H.pylori* negative cases (64.11%) is probably because *H.pylori* colonization is usually absent in areas of IM<sup>(1)</sup>.

## References

- 1-Vinyy Kumar , MBBS, MD, frcpath, ABUL K. ABBAS, MBBS, NELSON FAUSTO, MD . Robbins and Cotran pathologic basis of disease ,7<sup>th</sup> edition ,2004. P.813-823.
- 2- Vinyy Kumar ,Ramzi S. Cotran, MD. Stanley L. Robint, MD. Basic pathology, 7<sup>th</sup> edition , 2002, P.555-557.
- 3-Juan Rosi ,MD. Rosi and Ackerman's Surrigical Pthology, 9<sup>th</sup> edition, 2004, Vol.1,P.663.
- 4-Meining A, Mogner A, Miehler S, Byerdroffer E, Stotte M, atrophy-metaplasia-dysplasia-Carcinoma sequence in stomach , Best practice and research .Clinical Gastroenterology ,2001Dec;15(6):983-98.
- 5-Kang KP, Lee HS, Kim N, Kang HM, Park YS, Lee DH, Choe G, Kim JS, Song IS. Role of intestinal metaplasia subtyping in the risk of gastric cancer in Korea. Journal of Gastroenterology & Hepatology. 2009Jan;24(1):140-8.
- 6-Carillho C, Modcoicar P, Cunha L, Ismail M, Guissive A, Lorinzoni C, Fernandes F ,Pelteiro B, Almeida R, Figueirido C, David L, Lunet N. Prevalence of *H.pylori* ,chronic gastritis and intestinal metaplasia in Mozambican dyspeptic patients . International Journal of pathology. 2008 Dec; 20.
- 7-Hackelsberger A, Guther T, Schultze V, Labenz J, Roessner A, Malfertheiner P. Prevalence and pattern of *H.pylori* gastritis in gastric cardia. American Journal of gastroenterology. 1997Dec; 92(12):2220-4.

- 8-Kim HJ, Choi BY, Byun TJ, Eun CS, Song Kim YS, Han DS. The prevalence of Atrophic gastritis and intestinal metaplasia according to gender , age and H.pylori infection in a rural population. *Journal of preventive medicine and public health*. 2008Nov; 41(6):373-9.
- 9-Zhang C, Yamada N, Wu YL, Wen M, Matsuhisa T, Matsukura N. H.pylori infection glandular atrophy and intestinal metaplasia in superficial gastritis , gastric erosion , erosive gastritis , gastric ulcer and early gastric cancer, *World Journal of gastroenterology* . 2005Feb.14;11(6): 791-6.
- 10-Al-Kanawi B, Mordan N, Jamal A, Mirdad S, Abol Fotouh M, Ahemd ME, Sayadain G, Seidi O, Shatoor A. H.pylori and intestinal metaplasia with its subtyping in gastric antrum in a Saudi population. *Scandinavian Journal of gastroenterology* .1999Jun;34(6):562-5.