

## EFFECT OF DIFFERENT CONCENTRATIONS OF CADMIUM CHLORIDE ON SOME STRUCTURAL CHANGES OF TESTES IN ADULT MALE RABBITS

Ammar A. AL-Haddad, Bara N. AL-Okaily and Sahib M. Hussein

Department of Physiology and Pharmacology, College of Veterinary Medicine, University of Baghdad  
Baghdad, Iraq.

(Received 5 August 2008, Accepted 16 November 2008)

**Keywords:** Cadmium chloride, Testes, Seminiferous tubules.

### ABSTRACT

This present study was designed to investigate the effects of two levels of cadmium chloride (30 and 40 part per billion (ppb)) in drinking water on body weight, relative weight of testes and epididymus (head, body, tail), diameter and thickness of seminiferous tubules. Eighteen mature male rabbits were randomly divided into three equal groups; the control group (GI) were given ordinary tap water and animals in the first treated group (GII) were received 30 part per billion (ppb) of cadmium chloride in drinking water; while animals in the second treated group (GIII) were given 40 ppb of cadmium chloride in drinking water. Weight of animals were taken at the pre-treated period and every three weeks during the treated period. At the end of experiment the animals were killed, testis and epididymus were taken in order to measuring their weight. Samples testis were taken for histological study and for measuring the diameter of the seminiferous tubules and the thickness of the cells lining their. The results showed a significant increase ( $p < 0.05$ ) in the mean body weight of animals in the groups including the control (GI). The results also pointed to occurrence of a significant decrease ( $p < 0.05$ ) in the relative weight of testis and epididymus of both cadmium treated groups. Besides a significant decrease ( $p < 0.05$ ) in the mean of diameter the seminiferous tubules and the thickness of the cells lining them were occur after exposure to cadmium chloride. Concerning the histological study of the testis the results showed presence of acute necrotic changes modified by vaculation of cytoplasm of sertolli cells with decrease in number of spermatogenic cells, GIII group were more affected than GII group. On conclusion, cadmium chloride in drinking water (30 and 40 ppb) caused functional change in spermatogenesis in adult male rabbits.

### INTRODUCTION

Cadmium is a naturally occurring non essential and toxic heavy metal commonly found in stabilizers in polyvinyl chloride products, color, pigment, several alloys and, most commonly, in rechargeable nickel cadmium batteries (1).

Cigarette smoking may cause significant increase in the blood cadmium level, and it has been reported that smokers have 4-5 times higher level of cadmium in the blood than non smokers (2,3). Inhalation of cadmium through tobacco smoking will directly affect the respiratory system and an elevated blood level of cadmium may be a factor immunodepression system in smokers (4).

Cadmium apoptotic cell death in rat testicular tissue (5) and human T-cell line (6) and in marine macrophages (7).

The gonads is considers the main target for environment toxins (8). Cadmium among them, is very dangerous to testicular function (9). It has been found that route of administration of cadmium, frequency and time of exposure have prominent effect on testicular weight, where (10) and (11) recorded significant decrease in testicular weight in rats and rabbits, respectively after different period

of exposure to cadmium chloride. (12) pointed to the effect of different concentration of cadmium acetate on testicular weight in rats.

Besides both of cadmium, and lead are linked with an increase in testicular oxidative stress (13,14), and resultant increase in sperm DNA oxidation (15).

Little researches have been illustrated the deleterious effect of cadmium on male and female gonads in animals and human (16). According to the importance of this, the following study has been designed to explore the effect of exposure to two different doses of cadmium chloride on some testicular and epididymal functions of adult male rabbits.

## MATERIALS AND METHODS

Four to five months old male rabbits were randomly divided into three groups each of six rabbits and were treated for three months as follows: Group I were received tap water and served as control group; group II were 30 part per billion (ppb) of cadmium chloride (cdcl<sub>2</sub>) in drinking water and group III were subjected to ad libitum supply of drinking water containing 40 ppb.

Body weight of animals were measured pre and during treatment. At the end of experimental period rabbits were killed and weight of the right testes, head, body and tail of epididymus were measured. For histological studies pieces of testes were removed and preserved in 10% neutral formalin buffer solution, and histological section were stained with hematoxyln and Eosin stain(17). Besides, diameter of seminiferous tubules and thickness of epithelial layer lining them were measured using eye piece with micrometric division, the division were corrected using micrometer slid.

Differences between experimental groups were evaluated using one-way and two-ways analysis of variance (ANOVA). For all analysis, a P value of < 0.05 was considered to significant (18).

## RESULTS

The effect of exposure to two different doses of cadmium chloride on some testicular functions in male adult rabbits were shown in tables (1,2 ,3).

Table(1) illustrate the absence of statistical differences ( $P > 0.05$ ) in body weight of animals in both treated groups II and III at 3<sup>rd</sup> and 6<sup>th</sup> weeks of treatment as compared to control group. However, cdcl<sub>2</sub> causes a significant decrease ( $P < 0.05$ ) in body weight of rabbits in group II at 9<sup>th</sup> and 12<sup>th</sup> weeks of treatment as compared to group III and control. Moreover, within groups significant differences ( $P < 0.05$ ) were detected in three groups during treatment period comparing with pretreatment period.

The results in table (2) reveled the presence of a significant decrease ( $P < 0.05$ ) in mean value of relative testicular weight in both treated group II and III compared to control. Besides, there were no significant differences ( $P > 0.05$ ) in this parameter between the two treated groups when compared with each other. The results also showed that exposure of animals to cadmium chloride in drinking water (group II and III) caused a significant decrease ( $P < 0.05$ ) in mean value of relative epididymal weight in both treated groups compared to control. Such decrement were detected relative weight of epididymal head in both treated groups (G I and G II) and tail of epididymus in group III compared to control ( $P < 0.05$ ). On the other hand, non significant differences ( $P > 0.05$ ) in relative weight of epididymal tail in both treated groups were observed comparing to control (table-2). Besides, significant decrease ( $P < 0.05$ ) in the diameter of seminiferous tubules (table-3) and the thickness of cell lining them there occur after exposure to cadmium (group T1 and T2).

Histological studies of the testis of rabbits in 1<sup>st</sup> treated group revealed presence of degenerative changes in cell lining seminiferous tubules characterized by vaculation of cytoplasm of sertolli cell with significant decrease ( $P < 0.05$ ) in spermatogenic cells (fig-2) comparing to control group(fig-1). Besides, histopathological changes were more sever in second treated group (fig-3).

**Table (1) Effect of cadmium chloride in drinking water on body weight (gm) of male rabbits.**

(Mean values with stander error for six rabbits per group)

group		Control (G I)	Group II received cdcl2 30 ppb	Group III received cdcl2 40 ppb
weeks				
Pre-treat m-ent	0	1165.83 ± 14.3 A a	1165.33 ± 10.7 A a	1177.33 ± 20.3 A a
	3	1240 ± 14.0 A b	1248 ± 12.9 A b	1237 ± 13.9 A b
	6	1288.66 ± 8.3 A c	1295.5 ± 20.8 A c	1280.33 ± 11.7 A c
	9	1313.16 ± 5.3 A c	1319 ± 21.8 A c	1223.33 ± 23.8 B b
Treatment period	12	1335.66 ± 6.2 A c	1310.5 ± 16.1 A c	1190.16 ± 12.5 B ab

A,B,C mean values between groups with unlike superscript letter were significantly different ( $P < 0.05$ ).a,b,c mean values with column with unlike superscript letter were significantly different ( $P < 0.05$ ).

**Table (2) Effect of cadmium chloride in drinking water on relative weight of testes and head, body and tail of epididymus (gm/100gm of B.w)**  
(mean values with stander error for six rabbits per group)

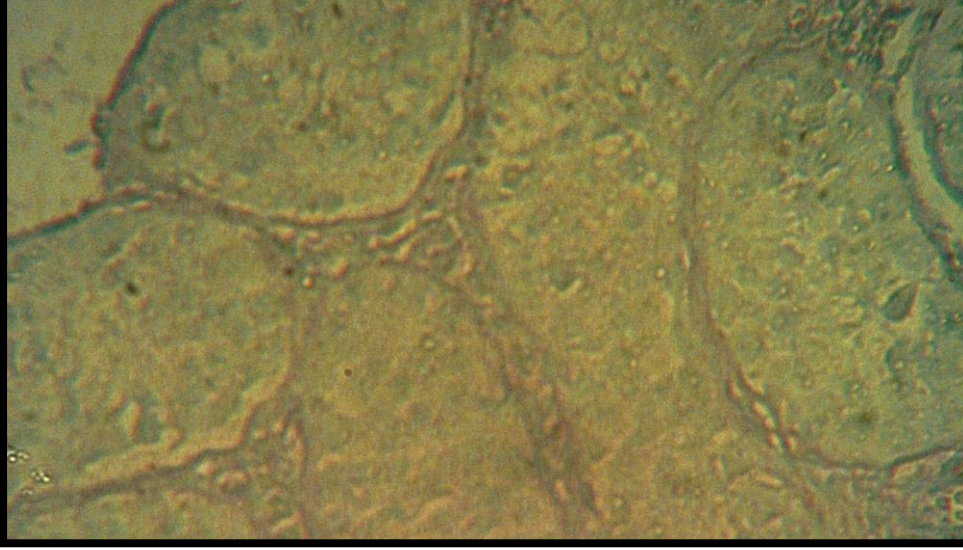
group weeks	Control (G I)	Group II received cdcl2 30 ppb	Group III received cdcl2 40 ppb
Testis	0.0497 ± 0.0008 A	0.0429 ± 0.0004 B	0.0394 ± 0.002 C
Epididymus	0/0161 ± 0.0003 A	0.0143 ± 0.0007 B	0.0135 ± 0.0005 B
Head of epididymus	0.0072 ± 0.00001 A	0.0061 ± 0.0003	0.0063 ± 0.0002 B
Body of epididymus	0.0031 ± 0.0001 A	0.0029 ± 0.0001 AB	0.0024 ± 0.0001 B
Tail of epididymus	0.0058 ± 0.0002 A	0.0051± 0.0005 A	0.0051±0.0002 A

A,B,C mean values between groups with unlike superscript letter were significantly different (P < 0.05).

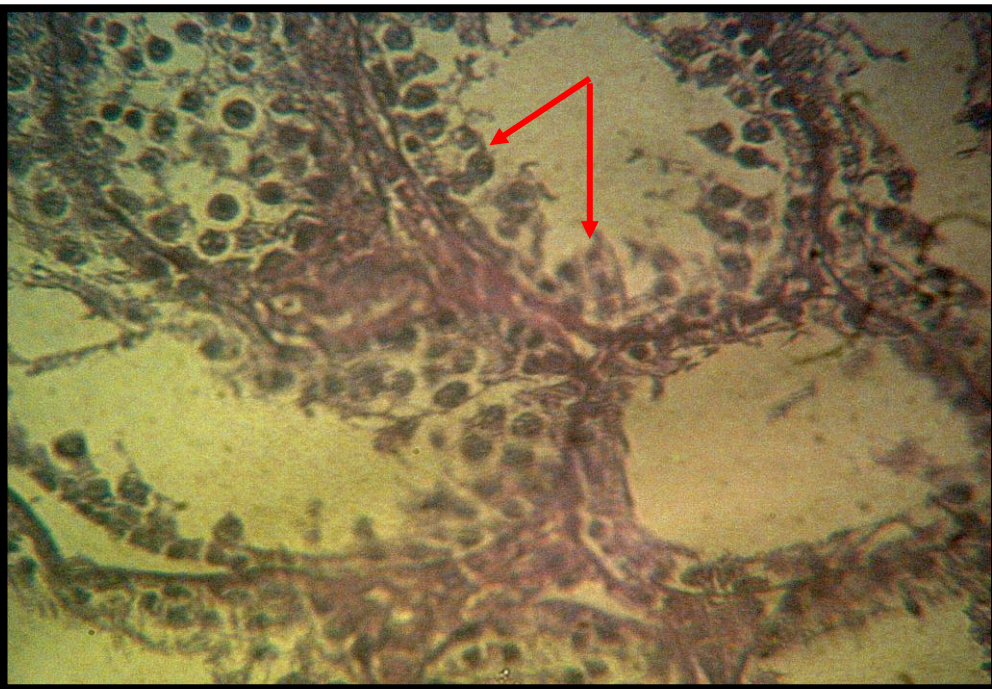**Table (3) Effect of cadmium chloride in drinking water on diameter and thickness of seminiferous tubules (micrometer) in male rabbits**  
(Mean values with stander error for six rabbits per group)

group weeks	Control (G I)	Group II received cdcl2 30 ppb	Group III received cdcl2 40 ppb
Diameter of seminiferous tubules	168.74 ± 2.22 A	139.72 ± 8.44 B	112.08 ± 1.6 C
Thickness of cell lining of seminiferous tubules	55.6 ± 1.29 A	32.1 ± 2.5 B	24.06 ± 0.82 C

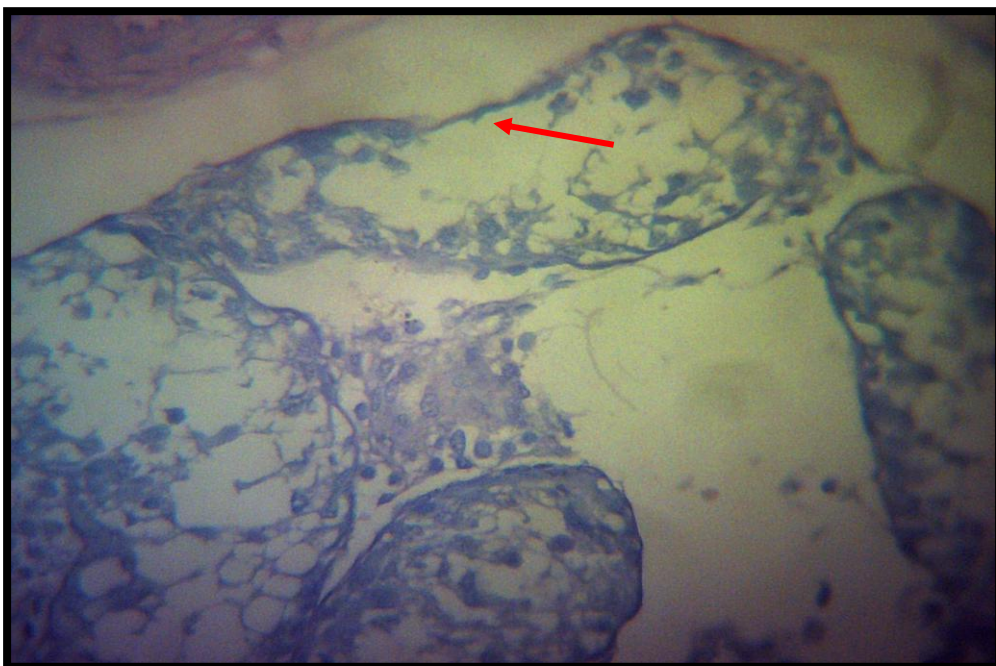
A,B,C mean values between groups with unlike superscript letter were significantly different (P < 0.05).



**Fig (1) testes of untreated rabbits (control), note complete layer of seminiferous tubule and spermatogenesis (H & E. 400X)**



**Fig (2) section in testes from cadmium treated rabbits (group II), note vacuolation of cytoplasm of Sertoli cells and degeneration of spermatogenic cells (H & E. 400X)**



**Fig (3) section in testes from cadmium treated rabbits (group III), showing degeneration of spermatogenic cells, with a basement membrane only and few number of sertolli cells (H & E. 400X)**

## DISCUSSION

The present study pointed that exposure of male rabbits to different doses (30,40 ppb) of cadmium chloride caused significant increase ( $P < 0.05$ ) their body weight (table 1). Such increment may be due to the reduction of testosterone concentration (19), besides chronic exposure to cadmium chloride caused significant decrease in thyroid hormones, triiodothyronine (T3) and thyroxin (T4) concentration (20). Such hormones related inversely to body weight, so we can concluded that suppression of T3 and T4 concentration by cadmium exposure may cause decrease in basal metabolic rate, loss of hair and increase in body weight due to accumulation of mucopolysaccharide in subcutaneous tissue (21) or precipitation of mucoprotein in the intracellular space and subcutaneously leading to increase body weight (22).

The present study pointed suppression of relative testicular weight in cadmium treated groups (T1 and T2) with subsequent degeneration and vaculation of spermatogenic cells (fig 2,3). Such results were in agreement with (23) in their study on golden hamster. The results also was in agreement with Albeuroti (24), where different concentrations of  $cdcl_2$  (75,100,150) cause significant decrease in testicular weight.

A significant suppression in relative weight of head and body of epididymus were recorded after treatment with cadmium. Such depression may be due to vaculation of interstitial cells and presence of oedematous fluid after exposure to cadmium leading to widening of interstitial tissue and congestion of blood vessels supplying epididymus with subsequent atrophy of cell lining epididymus (24,25), besides, subsequent decrease in blood flow to about 70% or deficiency of  $O_2$  due to increase permeability of blood vessels and return of blood to interstitial cells as a result of cadmium treatment may be of considered (10).

A histological studies of seminiferous tubules of this investigation revealed presence of significant depression in mean value of diameter of seminiferous tubules and thickness of cells lining

seminiferous tubules with subsequent degenerative changes in spermatogenic cells which may be due to accumulation effects of cadmium in testes as result of prolong exposure (26). Besides the suspected depression in testosterone level in serum due to cadmium may be another speculation (27).

Meanwhile, such histological changes could be attributed to testicular ischemia occurred due to cadmium exposure, ischemia occurred in the testes, because it contains a fibrous tunica, which act as structural barrier to dispersion of interstitial fluid. The increased fluid builds up and causes an increase in interstitial pressure, which compresses the vascular supply and leads to ischemia (28).

It has been shown that cadmium cause alkalinization of fluid of seminiferous tubules and epididymus in adult male rats through the loss of functional  $H^+$ - pumping ATPase (from the cell apical membrane) of epididymus, which maintained the acidity of the epididymal luminal fluid (29,30). Such impaired in acidification in the epididymus might result in deficient sperm maturation and motility, leading to lower male fertility (31).

### تأثير تراكيز مختلفة من كلوريد الكاديوم على بعض التغيرات التركيبية للخصى في ذكور الأرانب البالغة

عمار احمد الحداد ، براء نجم العقيلي و صاحب محمد حسين  
فرع الفلسفة والأدوية ، كلية الطب البيطري، جامعة بغداد، بغداد، العراق

#### الخلاصة

استهدفت هذه الدراسة معرفة تأثير تركيزين مختلفين من كلوريد الكاديوم مع ماء الشرب على وزن الجسم، الوزن النسبي للخصى والبربخ واجزائه، قطر النبيبات المنوية وسمك طبقة الخلايا المبطنة للنبيبات المنوية في ذكور الأرانب، تم استخدام ثمانية عشر ارنبا من الذكور، قسمت عشوائيا الى ثلاثة مجاميع متساوية عشوائيا كالاتي:- مجموعة السيطرة (GI) أعطيت ماء الشرب الاعتيادي، اما مجموعة المعاملة الأولى (GII) أعطيت ماء الشرب المضاف اليه كلوريد الكاديوم بتركيز (30 جزء بالبلليون (ppb))، بينما اعطيت مجموعة المعاملة الثانية (GIII) ماء الشرب المضاف اليه كلوريد الكاديوم بتركيز (40 جزء بالبلليون). تم اخذ اوزان الحيوانات قبل المعاملة وخلالها وفي نهاية التجربة قتلت الحيوانات وأخذت الخصية والبربخ لغرض وزنها كما أخذت عينات من الخصية لغرض الفحص النسيجي. أظهرت النتائج حصول ارتفاع معنوي ( $P < 0.05$ ) في معدل أوزان أجسام الحيوانات في مجموعات التجربة الثلاث (GI, GII, GIII)، كما اشارت النتائج الى حصول انخفاض معنوي ( $P < 0.05$ ) في الوزن النسبي للخصى والبربخ للمجموعتين المعاملتين بكلوريد الكاديوم، إضافة إلى ذلك فقد ادت المعاملة بكلوريد الكاديوم الى حصول انخفاض معنوي ( $P < 0.05$ ) في معدل اقطار النبيبات المنوية وسمك طبقة الخلايا المبطنة للنبيبات. اما فيما يخص الفحص النسيجي للخصى فقد اشارت النتائج إلى حدوث تغيرات تنكسية حادة في الخلايا المبطنة للنبيبات المنوية تميزت بتفجي هولي خلايا سرتولي مع قلة الخلايا المولدة للنطف، ولقد كانت هذه التغيرات المرضية على أشدها في مجموعة المعاملة الثانية (GIII). يستنتج من هذه الدراسة بان تعريض ذكور الارانب البالغة الى كلوريد الكاديوم وبتركيزين 30 و 40 جزء بالمليون مع ماء الشرب ادى الى حدوث تغيرات وظيفية في عملية تكوين النطف.

#### REFERENCES

- 1- Jarup,2003 Jarup, L.(2003).Hazards of heavy metal contamination. Br. Med. Bull. 68,176-180.
- 2- Jarup et al.(1998). Jarup, L. Bergland, M.; Elinder, C. G.; Norberg, G.; and Vahter, M. (1998).Health effects of cadmium exposure – A review of literature and a risk estimate. Scand . J. Work Environ. Health 24 (supl 1), 1- 51.
- 3- ATSDR, (2007) (Agency for Toxic Substance and Disease Registry). (2007). Health effects of cadmium. In:- Encyclopedia of Earth, Eds,Clerland, C. J.

- 4- IARC. (International Agency for Research on Cancer, (1993). Cadmium, Mercury, and exposure in the glass manufacturing industry. Working group views and expert opinions. Monoger. Eval. Carcinog. Risks Hum.58, 41-117.
- 5- Xu, C.; Johnson, J. E.; Singh, P. K.; Jone, M. M.; Yan, H.; and Carter, C. E. (1996). In vivo studies of cadmium – induced apoptosis in testicular Tissue of the rats and its modulation by chelating agent. Toxicology 107: 1-8.
- 6- Iroy, Y.; Matsuok, M.; Wisprinyono, B.; sugiura, T.; and Igisa, H. (2000). Involvement of extracellular signal – regulate protein kinase (ERK) Pathway in the induction of apoptosis by cadmium chloride in CCRE – CEM cells. Biochem. Pharmacol. 60, 1875-1882.
- 7- Kim, J. and Sharman, R. P.(2004). Cadmium – mediated action of C – Jun NH<sub>2</sub> – Terminal kinase (JNK) and apoptosis in response to cadmium in murine macrophages. Tox. Sci. 81 (2): 518-527.
- 8- Sokol, RZ. (1997) The hypothalamic-pituitary-gonadal axis as a target for toxicants.. In : Comprehensive Toxicology. Sipes I. C.; McQueen C.A.; and Gandolfi A.J.; Eds. Oxford: Elsevier Science, vol. 10: pp87-98.
- 9- Laskey, J. W.; and Phelps, P. V. (1991). Effect of cadmium and other metal cations on vitro leydig cell testosterone production. Toxicol. App. Pharmal. 10: 296-306.
- 10- Gouveia, M. A.(1988). The testes in cadmium intoxication: Morphological and vascular aspects. Andrologia, 20(3): 225-231 .
- 11- Foote, R. H.(1999).Cadmium effects testes and semen of rabbits exposed before and after puberty. Reprod. Toxicol. 13(4): 269-277 .
- 12- AL- Azawi, E. N. (1989). Effect of different doses of cadmium on male reproductive of mice. MSc. Thesis. College of Sci. University of Baghdad.
- 13- benoff, S.; Jacob. A.; and Hurley, I. R. (2000). Male infertility and environmental exposure to lead and cadmium. Human Reproduction, 6: 107-21.
- 14- Hsu, R. C.; and Gue, Y. L.(2002). Antioxidant nutrients and lead toxicity. Toxicology. 180: 33-44.
- 15- Xu, D. X.; Shen, H. M.; Zhu, Q. X.; Chua, L.; Wang, Q. N.; Chia, S. E. and Ong, C. N. (2003). The association among serum quality, oxidative DNA damage in human spermatozoa and concentration of cadmium, lead and selenium plasma. Mutat Res. 534: 155-163.
- 16- Zeng, X.; Jin, T.; Zhou, Y. and Nordberg, G.F.(2003). Changes of serum sex hormone levels and MT mRNA expression in rats orally exposed to cadmium. Toxicology 186: 109-118 .
- 17- Humason, G. L.(1967). Animal Tissue Techniques.2nd ed. Freeman, W. H.Co. U.S.A. pp. 114-130 .



- 18- Sendecore, G. W. and Cochran, W. G. (1973). Statistical Methods. 6<sup>th</sup> ed. Iowa State University Press.
- 19-Rolf, C.; von Eckardstein, S.; Koken, U. and Nieschlag, E.(2002).Testosterone substitution of hypogonadal men prevents the age-dependent increases in body mass index, body fat and leptin seen in healthy ageing men: results of a cross-sectional study. *European Journal of Endocrinology*. 146: 505–511.
- 20-Cheyad, S. M. (2005). Effect of Cadmium Chloride in Drinking Water on some Structural and Functional Aspects of Thyroid Gland in Mature male Rabbits. MSc. Thesis. College of Vet. Medicine. University of Baghdad.
- 21- Kobia-chi, N. and Cin, W. W.(2000). Thyroid hormone action and brain development. *Trend. Endocrinol. Metab*. 11: 123-128.
- 22- Lima, F. R. S.; Gervais, A. and Colin, C.(2001). Regulation of microglial development: A Novel role for thyroid hormone. *J. Neuro. Sci*, 21: 2028-2038.
- 23- Wlodarczyk, B.; Biernacki, B.; Minta, M.; Kozaczynski, W. and Juszkiewicz, T.(1995). Male Golden hamster in male reproductive toxicology testing: Assessment of protective activity of selenium in acute cadmium intoxication. *Bull. Environ. Contam. Toxicol.*; 54: 907-912
- 24- AL-Beuroti, J. A. (2001) Functional and Spermatogenic Changes accompanied with cadmium Treatment in mice. MSc. Thesis. College of Education /Ibn Al-Haitham. University of Baghdad.
- 25- Al-Wachi, S.; Kadhim, A. H. and Wahid, I. N.(1994). Histopathological Changes in the epididymus of mice injected with cadmium acetate. *Al-Mustansiriya J. Sci.*; 5(1): 7-10
- 26- Waalkes, M. P.; Rehm, S. and Devor, D.; E. (1997). The effect of continuous Testosterone exposure on spontaneous and cadmium – induced tumors in the male fischer (F344/Ncr) rat. *Toxicol. Appl. Pharmacol*. 142(1): 40-6.
- 27- Lafuente, A.; Márquez, N.; Pérez-Lorenzo, M.; Pazo, D. and Esquifino, A. I.(2001).Cadmium Effects on Hypothalamic-Pituitary-Testicular Axis in Male Rats. *Experimental Biology and Medicine* 226: 605-611.
- 28- King, L. M.; Blank, W.A.; and Georg, W. J. (1999). Differences in cadmium Transport to the testis, Epididymus, and Brain in Cadmium – sensitive and Resistant murine strains 129 / J and A / J. *J. Pharmacol. Eper. Therapeutics*. Vol.289, Issue 2, 825-830.
- 29- Berton, S.; Hammar, K.; Smith, P. J. S. and Brown, D. (1998). Proton secretion in reproductive tract: involvement of Cl<sup>-</sup> - independent HCO<sub>3</sub><sup>-</sup> transport. *Am. J. Physiol. Cell Physiol*. 275; C1134 – C1142.

- 30- Harak-Kramberger, C. M.; Saboli, I.; Blanusa, M.; Smith, P. J. S.; Brown, D. and Berton, S. (2000). Cadmium inhibits Vacuolar H<sup>+</sup> ATPase – mediated acidification in the rat epididymus. *Biology of Reproduction*. 63,599 – 606.
- 31- Tas, S.; Lauweys, R. and Lison, D. (1996). Occupational hazards for male reproductive system. *Crit. Rev. Toxicol.* 26: 261 – 307.