

---

## Treatment of Recurrent Ingrowing Toe Nails by Electrosurgical Matricectomy

Jamal Khalil Al-Qaisy

MBBS, DGS, FICMS

---

### ABSTRACT:

**Background:** Ingrowing toenails (ITN) is a common problem in surgical clinic which seen frequently among adults with male predominant, resulting from pressure on the toe.

**Objective:** To evaluate the management of recurrent ITN by electrocautery.

**Patients & Methods:** An interventional study was carried out from April 2005 to April 2009 on 112 patients with 120 recurring ITN, eight patients with medial and lateral border diseases treated with different surgical procedures were included in this study.

**Results:** One hundred and twenty ITNs could be followed for one month, 112 ITNs could be followed for three months, 102 ITNs could be followed for six months, and 96 ITNs could be followed for twelve months. Complete healing takes a mean time of 1.8 week, only six patients developed infection, two patients developed spicule, three patients presently with severe pain required strong analgesia for three days, four patients were unsatisfied of the appearance of their big toe.

**Conclusion:** The surgical technique of lateral nail avulsion plus electrical cautery matricectomy is effective in the treatment of recurrent ITN with high success rate and minimal complications compared with other procedures.

**Key words:** Recurrent ingrowing toe nail; Chemical treatment of ingrowing toenail; CO<sub>2</sub>Laser for ingrowing toenail; onychocryptosis.

---

### Introduction:

ITN is a common problem seen in surgical clinic, frequently seen in young adult with a male predominance of 3:1<sup>(1,2)</sup>, it may result from excessive pressure on the toes, poorly fitting foot wear, and improper nail trimming techniques, too short or leaving rounded edge.<sup>(3,4)</sup> conservative treatments can be successful in stage I<sup>(5)</sup> disease when there is only slight erythema, edema and pain on pressure, but in stage II, symptoms are increased, and local infection and drainage are added. In stage III, all of the symptoms and signs are amplified with formation of granulation tissue and lateral wall hypertrophy.<sup>(6)</sup>

Surgical procedures including avulsion, wedge resection or total nail bed ablation are required, many of these procedures described in the literature that show moderate success rates and significant morbidity<sup>(6,7)</sup>. In the last decades, phenol cauterization matricectomy had been widely used with high success rates, but unpredictable tissue damage, infection, prolonged healing time<sup>(8,9)</sup>.

Sodium hydroxide is an alternative chemical agent that had provided high success rates with less morbidity<sup>(10,11)</sup>. Treatment of ITN with a carbon dioxide (CO<sub>2</sub>) laser has been reported since 1980<sup>(12,13)</sup>. CO<sub>2</sub> laser has been described to reduce the recurrence rate, shorten the treatment period, relieve post operative pain, and improve post operative appearance<sup>(14,15,16,17)</sup>.

No previous attempts were conducted and reported for using this procedure in management of ITNs in Iraq. Therefore, this study was carried out to evaluate the electrocautery procedure in the management of recurrent ITNs.

### Patients and Methods:

Hundred twelve patients with hundred twenty sides recurrent ITNs after different surgical procedure were included in this prospective study which was carried out from the period of April 2006 to April 2009 at Baghdad in my private clinic. All those patients were treated previously by different surgical procedures as shown in figure 1.

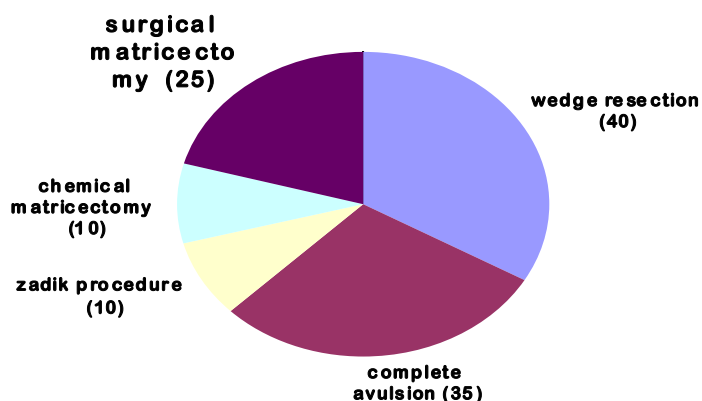


Figure (1): Number of surgical procedures done before recurrence.

Table (1): Socio-demographic information of the study sample.

Sociodemographic information	No.	%
Sex		
Female	77	69
Male	55	31
Nail Stage		
I	16	13.3
II	32	26.7
III	72	60.0

Their ages ranged between 16 and 38 years with a mean+SD of (26±10.3years). Seventy seven patients were females, six of them had both sides disease and thirty five males, two of them had both sides disease. Sixty percent were in stage- III, 27% were in stage- II and 13% were in stage- I (table 1). Under local anesthesia, a rubber band is applied to the big toe as a tourniquet, 1/5<sup>th</sup> of the lateral nail plate is removed. The matrix area is exposed by performing a 1/2 cm incision at the corner of the affected nail. Any granulation tissue is curetted and cauterized and so the matrix area, using a Cordless pencils electrical cautery.(MEDI Choice-Owen and Minor Richmond, VA). The incision is sutured with 3(0) silk and the procedure is terminated by removal of the tourniquet, dressing is done with Chlorhexidine sterile Gauze impregnated with white soft paraffin and covered by povidone- iodine Soaked gauze wrapped by bandage.

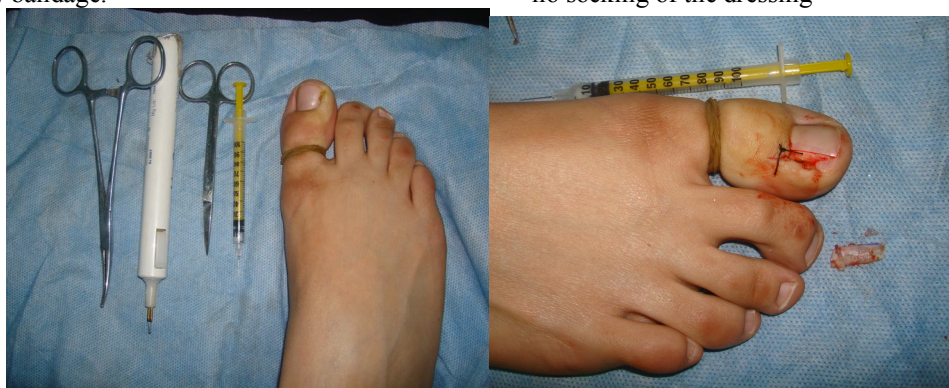

Figure No.1-A: Before surgery

1-B: After surgery

### Results:

After forty eight hours check up post operatively 58 patients were dry, 48 patients present with mild discharge, 10 patients moderate discharge, 6 patients with severe discharge, most patients present with mild pain and only few patient presented with moderate and severe pain. One week post operatively 114 edges were dry and 6 edges presented with mild discharge, stitch is removed and wound left opened, those 6 edges with mild discharge becomes dry after 5 days of oral antibiotics. One month post operative visit only 102 edges could be seen, all were normal. Three months post operative visit only 96 edges could be seen, two patients developed a spike; no treatment was required as it cause no pain. All patients' mobile

Postoperatively, antibiotics ( Ampiclox capsule 500 mg 1x4 for one week or cephalaxine capsule 500mg 1x4 for penicillin sensitive patients) ,analgesics and foot elevation for 48 hours in addition to daily dressing twice after sitz bath, then the stitch is removed by the end of a week.

As shown in photo 1 and 2, the patients were examined 48 hours postoperatively and seen after one week for removal of stitches and follow up was done for one month, 3 month, 6 months and at one year. Patients were followed up for local complications and recurrence. All patients' mobile number was taken and helped me in the follow up periods.

Lastly, we verify the pain as mild, moderate and severe according to the amount of analgesics needed. And the criteria used for classification of the drainage into mild, moderate, severe according to socking of dressing whether partial, complete or no socking of the dressing

number was taken. 6 months visit, 80 edges could be seen all were normal. The remaining 16 patients were normal as inquired by telephone. 12 months, 76 edges could be seen all were normal as well as the remaining 20 edges as inquired by telephone (table 2).

### Discussion:

ITN is a common painful condition of foot, in stage I conservative management help, by warm soaks, antibiotics, elevation of the foot, but once paronychia developed and pointing spicula under the nail fold developed, surgical procedure is required<sup>(18)</sup>.

### Table (2): Postoperative Complications

Signs & symptoms	degree	48hours						1 week				1 month				3months				6months				12months			
		No. ♂ ♀ %						No. ♂ ♀ %				No. ♂ ♀ %				No. ♂ ♀ %				No. ♂ ♀ %							
Pain	Mild	10	34	6	85.8	0	0	0	0	0	0	0	0	0	0	0	0	0	0	0	0	0	0	0	0		
	Moderate	3	1	9	5	0	0	0	0	0	0	0	0	0	0	0	0	0	0	0	0	0	0	0	0		
	Severe	6	0	5	2.5	0	0	0	0	0	0	0	0	0	0	0	0	0	0	0	0	0	0	0	0		
Drainage	Non	3		3	48.3																						
			30	2	40	0	0	0	0	0	0	0	0	0	0	0	0	0	0	0	0	0	0	0	0		
	Mild	58	20	8	8.3	6	0	6	5	0	0	0	0	0	0	0	0	0	0	0	0	0	0	0	0		
Spike	Moderate	48	2	2	5	0	0	0	0	0	0	0	0	0	0	0	0	0	0	0	0	0	0	0	0		
	Severe	10	0	8	0	0	0	0	0	0	0	0	0	0	0	0	0	0	0	0	0	0	0	0	0		
		6		8	0																						
Recurrence		0	0	6	0	0	0	0	0	0	0	0	0	2	0	2	1	0	0	0	0	0	0	0	0		
		0	0	0	0	0	0	0	0	0	0	0	0	0	0	0	.	0	0	0	0	0	0	0	0		
																	8										
																	0										

### Discussion:

ITN is a common painful condition of foot, in stage I conservative management help, by warm soaks, antibiotics, elevation of the foot, but once paronychia developed and pointing spicule under the nail fold developed, surgical procedure is required<sup>(18)</sup>.

All surgical procedures aim to remove lateral nail plate combined with lateral matricectomy which gives the best chance of eradication<sup>(18)</sup>.

Simple partial or total nail avulsion has been used but has resulted in high recurrence (42% to 83%) as germinal matrix is not destroyed in this procedure<sup>(19,20)</sup>. The Zadik procedure has recurrence rates ranging from (14% to 28%). Historically, phenol has been used for matricectomy, but it produce irregular tissue destruction and can result in significant inflammation and discharge<sup>(21)</sup> and prolong healing are reported to be the drawbacks of this technique. It occurs due to the coagulation necrosis of the surrounding tissue and inflammation response<sup>(22)</sup>. Matrix cauterization with phenol has a low recurrence rate of (0% to 11%) and it has been the preferred method of treatment for ITN in the last years<sup>(23-24)</sup>. Complications arise from phenol cauterization to the matrix prompted surgeon to try another chemical agent, which is safer and also effective, sodium hydroxide is a slow – acting caustic agent, and it's destructive effect depends on it concentration and duration of contact, sodium hydroxide causes an alkaline burn and liquefaction necrosis but not coagulation necrosis as in the case of phenol. This may be the reason that sodium

hydroxide causes less post operative drainage and faster healing<sup>(25)</sup>. In one study by Brown 50 cases had been treated by applying 10% sodium hydroxide for 20 – 25 second, he followed most of the patient and report a 2% re-growth of a spicule and the time for healing was approximately 10 days<sup>(26)</sup>. Another study using 10% sodium hydroxide, reported time needed for complete healing by an average of 40 day<sup>(27)</sup>. Comparing our study with chemical cauterization by phenol or 10% sodium hydroxide, recurrence was less than 2%, healing takes 1-3 weeks, average 14 days. By one week 114 edges were dry and by 2 weeks, 120 edges were dry, pain were mostly mild, 4 patients were unsatisfied of narrow appearance of their toes, all were already told that their toes will becomes narrow. Treatment of ITN with a CO<sub>2</sub> laser has been reported since 1980<sup>(13,12)</sup>, various surgical techniques employing, CO<sub>2</sub> laser have been applied to reduce the recurrence rate, shorten the treatment period, relieve post operative pain, reduce post operative treatment, improve post operative appearance, and reduce complication. In one study<sup>(28)</sup>, a higher cure rate of 94.8% (18 of 19) was obtained, the mean time until healing was 12.5 days without infection because the CO<sub>2</sub> laser does not delay wound healing, no hemorrhage( because it seals minute bleeders in addition it has a bactericidal properties), and less post operative pain( because it coagulates the exposed nerve endings) (table 3).

Advantages & disadvantages of various methods of matricectomy according to reported studies

**Table 3: Different surgical procedures that are conducted for the patients & their associated signs, symptoms, recurrence & costs.**

Procedure	Pain	Drainage	Recurrence	Appearance	Cost
Zadik <sup>(21)</sup> procedure	Sever	Moderate	14 – 28%	Poor cosmetic	Costly
Phenol <sup>(23)</sup> matricectomy	Sever	Moderate	0 – 11%	Not acceptable	Cheap
10% sodium <sup>(25)</sup> hydroxide matricectomy				Acceptable	
CO <sub>2</sub> laser <sup>(15)</sup> matricectomy	Mild	Mild	2%	Acceptable	Cheap
Electro cautery Matricectomy <sup>(29,30)</sup> (present study)	Mild	Nil	1%		Expensive
	Mild	Mild	0%		Cheap

**Conclusion:-**

This study reports a new experience in practicing surgical approach to ITN that gives us a good result in the management comparing to other procedures in term of simplicity, economy, and availability. My recommendation is to start this procedure rather than others in the management of ITNs.

**References :-**

- 1- Fulton GJ; O Donohoe MK; Reynolds Jv; Keane FBV, et.al. Wedge resection alone or combined with segmental phenolisation for the treatment of ingrowing toe nail. Br J Surg .1994; 81:1074-5.
- 2- Ikard Rw; et.al. Onychocryptosis. JAM Coll Surg .1998; 187:96-102.
- 3- Scher Rk; et.al. Toenail disorders, Clin Dermatol .1983; 1:114-24.
- 4- Yang KC; Li YT; et. al. Treatment of recurrent ingrown great toenail associated with granulation tissue by partial nail avulsion Dermatol surg. 2002; 28:419-21.
- 5- Reijnen JA; Goris RJA; et. al. Conservative treatment of ingrowing toenail Br J Surg .1989; 76:985-7.
- 6- Siegle RJ; Stewart R; et al. Recalcitrant ingrowing nails, J Dermatol Surg .Oncol 1992; 18:744-52.
- 7- Persichetti P; Simone P; Li Vecchi G; Wedge excision of the nail fold in the treatment of ingrown toenail. Ann Plast Surg.2004; 52(6):617-20.
- 8- Sugden P; Levy M; Rao GS; et.al. Onychocryptosis-phenol burn fiasco.Burns.2001; 27:289-92.
- 9- Aksakal AB; Atahan C; Oztas P; Oruk S; et al. Minimizing post operative drainage with 20% ferric chloride after chemical matricectomy with phenol. Dermatol Surg. 2001; 27:158-60.
- 10- Kocyigit P; Bostanci S; Ozdemir E; Gurgey E; Sodium hydroxid chemical matricectomy for the

treatment of ingrown toenails. Dermatol Surg.2005; 31(7); 744-7.

11- Gem MA; Sykes PA; et al. Ingrowing toenails studies of segmental chemical ablation. Br J Clin Pract .1990; 44:562-3.

12- Apfelberg DB; Mas er MR; Lash H; et al. White DN. Efficacy of carbon dioxide laser in hand surgery. Ann Plast Surg 1984; 13:320-6.

13- Wright G; et al. Laser matricectomy in the toes. Foot. Ankle1989; 9:246-7.

14- Lin Yc; Su HY; et al. A surgical approach to ingrown nail: partial matricectomy using Carbon dioxide laser. Dermatol Surg.2002; 28:578-80.

15- Orenstein A; Goldan O; Weissman O; Tamir J; Winkler E; et al. A comparison between Carbon dioxide laser surgery with and without lateral fold vaporization for ingrowing toenails. J Cosmet laser Ther.2007; 9(2):97-100.

16- Takahashi M; Narisawa Y; et al. Radical surgery for ingrown nail by partial resection of the nail plate and matrix using a carbon dioxide laser J Cutan laser ther 2000; 2:21-5.

17- Serour F; Recurrent ingrown big toenails are efficiently treated by CO<sub>2</sub> laser. Dermatol Surg 2002; 28:509-12.

18- Zuber TJ; P Fenninger JL. Management of ingrown toenails. Am, Fam physician 1995; 52:181-90.

19- Lareig JD; Andersons JH; Ireland AJ; Anderson JR;et al. The surgical treatment of ingrowing toenails, J Bone Joint Surg .1991; 73:131-3.

20- sykes PA; Kerr R; et al. Treatment of ingrowing toenails by surgeons and chiropodists. Br med J 1988; 297:335-6.

21-Shaath N; Shea J; Whiteman; Zarugh A; at el. A prospective randomized comparison of the zadik procedure and chemical ablation in the treatment of

ingrown toenails. Foot Ankle Int. 2005; 26(5):401-5.

22- Kimata Y; Uetake M; Tsukada S; Harii K; et al. Follow –up study of patients treated for ingrown nails with the nail matrix phenolisation. Plast Reconstr Surg.1995; 95:719-24.

23- Bostanci S; Ekmeleci P; Gurgey E; et al. Chemical matricectomy with phenol for the treatment of ingrowing toenails. A review of the literature and follow-up of 127 treated patients. Acta Derm venereol .2001; 81:101-3.

24- Ozdemir E, Bostanci S, Ekmeleci P, Gurgey E; et al. Chemical matricectomy with phenol for the treatment of ingrowing toenails. Dermatol Surg 2004; 30:26-31

25- Bostanci S; Kocyigit P; Gurgey E; et al. Comparison of phenol and sodium hydroxide chemical matricectomies for the treatment of ingrowing toenails Dermatol Surg 2007; 33(6):680-5

26- Aksakal AB; Atahan C; Oztas P; Oruk S; et al. Minimizing postoperative drainage with sodium hydroxide. Dermatol Surg.2001; 27:158-60.

27- Gem MA; Sykes PA; et al. Ingrowing toenails: studies of segmental chemical ablation. Br J Clin Pract 1990; 44:562-3.

28- Toshlyuki Ozawa MD; Kensuke nose MD; Teruichi harada, MD; et al. partial matricectomy with a CO<sub>2</sub> laser for ingrowing toenail. Dermatol Surg. 2005; 31:302-305.

29- Heidelbaugh J; Lee H. Management of the ingrown toenail. Am Fam physician.2009; 79(4):303-8.

30- Thomas J. Zuber M.D., Saginaw Cooperative Hospital, Am Fam physician, treatment of ingrown nails by basic soft tissue surgery and electrosurgery experience. 2002; 65:2547-50.

\* Department of General Surgery, Al-Anbar University, College of Medicine, Iraq.