

ISSN: 1991-8941

## **Histological study of the effect of Piroxicam on testes of albino mice *Mus musculus***

**Ali K. Obeys \***

**Abdul Karim S. Mahood\*\***

**\* Foundation of technical Institute Aldour Technical Institute**

**\*\* Tikrit University - College of Medicine**

**Abstract:** Non- Steroidal Anti Inflammatory Drugs (NSAIDs) are the most frequently prescribed therapeutic agents, used for the treatment of rheumatic diseases, because they have analgesic, antipyretic and anti inflammatory action. Piroxicam is a well-known member of family NSAIDs use to reduce inflammation, pain associated with arthritis, osteoarthritis and ankylosing spondylitis. The objective of the present study is to evaluate the effect of different doses of Piroxicam upon testis tissue in mice. Twenty four male albino Swiss mice were randomly divided into control (n = 6) and experimental (n = 18) groups. The experimental groups are subdivided into three groups of six mice. Each received (0.29, 1.428, 2.857)mg/kg/day for fourteenth days, respectively; however the control group just received distilled water. In fifteenth day, mice were killed and testes tissue was prepared for light microscopic study. All animals exposed to drug were served to have a depletion of germ cells, germinal cell necrosis, especially in Spermatogonia and Leydig cells which had an abnormal fibroblast like appearance, abnormal space between neighboring Sertoli cells, thickness in seminiferous tubules basement membrane and wall arteries, therefore it is recommended that usage of this drug have harmful side effects on male fertility.

**Keywords :** Histological study, Piroxicam, testes, albino mice *Mus musculus*

### **Introduction**

Non steroidal anti inflammatory drugs (NSAIDs) are the most frequently prescribed therapeutic agents used for treatment inflammation because they have analgesic, antipyretic and anti inflammatory action [1], which are mediated by inhibition synthesis of prostaglandin. It has been involved as a regulator of several physiological processes in human body such as inflammatory process -es in immune response, vasodilator, vasoconstriction, pain perception and fever. Prostaglandins are produced in every tissue of the body (brain, lung, kidney, intestinal digestive system, male and female reproductive system) [2].

Prostaglandins play substantial roles in regulating reproductive system, are abundantly found in male reproductive tract [3]. Prostaglandin E & prostaglandin F are playing an important role in sperm metabolism and its function & also increase contractility of the epididymal tubule [4].

Conventional NSAIDs act as nonspecific inhibitors of the cyclooxygenase COX which act on arachidonic acid pathway that leads of various eicosanoid messengers molecules. Therefore in addition reducing the production of prostaglandin (PGH, PGE, PGF) they reducing the production of leukotrienes and thromboxan [5]. The COX enzymes have two distinct isoforms termed to COX1 & COX2 [6], the COX1 enzyme described as being constitutive and is expressed continuously in many tissues (brain, lung, intestinal digestive system, kidney, liver, platelets, testes, and ovary), it is involved various protective haemostatic mechanism in contrast COX2 enzyme that described as being inducible such that it is not normally in any appreciable quantity in tissue and its production is induced in sites of inflammation and tissues injury [7,2]. NSAIDs work to reduced inflammation by inhibition COX2 enzyme, which is a key enzyme in catalyzing the conversion of arachidonic acid to prostaglandin [8,9].

Piroxicam (feledin) is a member of oxicam family from NSAIDs group, it's the most

popular NSAIDs [10]. Piroxicam is well established in the treatment of rheumatoid arthritis and osteoarthritis. This drug seems to be highly effective the treatment of acute goat. It is useful in the management of ankylosing spondylitis, acute musculoskeletal disorders, dysmenorrhoea and as an analgesic [11]. The unwanted effect of NSAIDs is the inhibition of cyclooxygenase enzyme (COX) pathway. Inhibition prostaglandin (PG) by NSAIDs prevents ovulation in rat [12]. The recent studies show that Piroxicam have many side effects on intestinal digestive system, ulcer, gastritis [13], and kidney dysfunction [14]. NSAIDs cause pregnant mice abortion and congenital anomalies in mice fetuses [15,16], the post treatment by indomethacin can caused many histological alterations in rats testis [17]. Diclofenac drug causes many physiological disorders in rats' testis [18]. COX2 inhibitor causes germ cells apoptosis in rat epididymis due to prostaglandin E2 production [19]. The aim of this study was to evaluate the histological alterations that induced by Piroxicam in male mice testis.

#### Material & method

This study was done in medical laboratory department institute. Twenty four mature (70 days old) albino Swiss mice *Mus musculus* Balb/c were employed, weighing ( $25 \pm 3$  gm) obtained from college of medicine, Tikrit university. They were maintained on 12:12 light: dark bases, and  $24 \pm 2^\circ\text{C}$  with mouse pelleted food and water ad libitum. Male mice were housed in group not bigger than five animals (all from the same experimental group) in plastic cages with metal cover ( $13 \times 16 \times 30$ ) cm, with wood shavings as bedding material. Twenty four male albino mice were randomly divided into control ( $n = 6$ ) and experimental ( $n = 18$ ) groups. The experimental groups are subdivided into three groups of six mice that divided into four groups, each once is injected Intra Peritoneum. with different doses of Piroxicam once daily for 14 consecutive days.

#### Drug administration

Piroxicam ampule 20 mg/2ml (ZMC Import Export GmbH Germany). Male were injected daily Intra Peritoneum (I.P.) administrated in three doses: Therapeutic dose, over dose 1 and over dose 2 (0.29, 1.428 and 2.857) mg/kg for 14 days respectively [17], and Control group were injected with normal saline 0.9 mg/L.

#### Surgical procedure

In fifteen days, the male were anesthetized by chloroform, and the peritoneal cavity was opened through a lower transverse abdominal incision. The testis was immediately removed and kept in normal saline. At the end the

experimental animals were killed by decapitation.

#### Histological preparation

The collected tissues were fixed in 10% formalin, dehydrated through graded alcohol series (30-100%), cleared in xylene and embedded in paraffin wax. Sections of five microns thickness were prepared and stained with Haematoxylin & Eosin (H&E) [21]. Photomicrographs of stained slides were taken using light microscope (Leica, Germany) attached to digital camera (Pixelink, Canada).

#### Results

##### Control group

Testis of control mice showed normal features of testicular tissue as illustrated in fig (1). The testis is enclosed by a thick fibrous capsule, the tunica albuginea. The Seminiferous tubules are ensheathed by basal lamina which was lined with stratified germinal epithelium, involved Sertoli and germ cells in various stages of spermatogenesis. Sertoli cells exhibit typical irregular pale nuclei and well define cytoplasm. Spermatogonia are oval in shape, rest on the basal lamina of seminiferous tubules directly above them are spherical primary spermatocytes, recognized by copious cytoplasm and large nuclei, containing coarse clump chromatin. Secondary spermatocytes are not seen in this section due to rapid division processes. Therefore above the primary spermatocytes, there are large cluster of elongated Spermatids which undergo a dramatic shape changes, forming spermatozoa. Between the seminiferous tubules the interstitium that contain a distinct Leydig cells and blood vessels.

##### Therapeutic group

Sections of this group showed an increase in the thickness of seminiferous tubules and tunica albuginea, fibrosis in Leydig cell and in interstitium which showed vacuolation in some regions of it, fig (2,3,4). Seminiferous tubules showed sloughed areas in its epithelium, with vacuolation and degeneration also, depletion in germinal layer in some seminiferous tubules and return of Spermatids downward to the seminiferous tubule wall was also reported in this group fig (3,4,5).

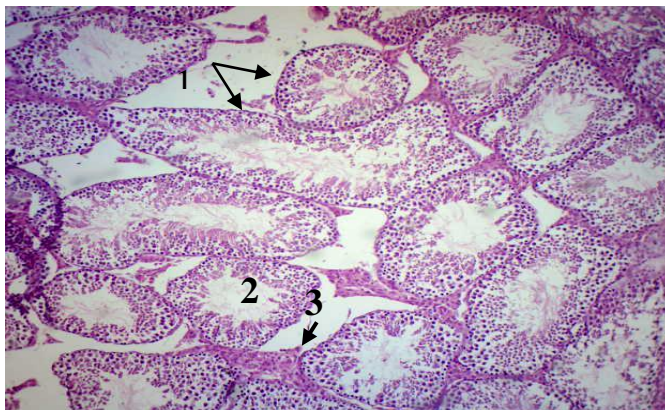
##### T2: Over dose 1

This group showed an increase in the shrinkage of the whole seminiferous tubules, with fibrosis, necrosis, and vacuolation in interstitium. Vacuolation in tunica albuginea and interstitium also was seen. The space between seminiferous tubules was increased, fig (6,7,9,10). Degeneration and apoptosis was seen in all cells within the seminiferous tubule. Increased in the space between neighboring

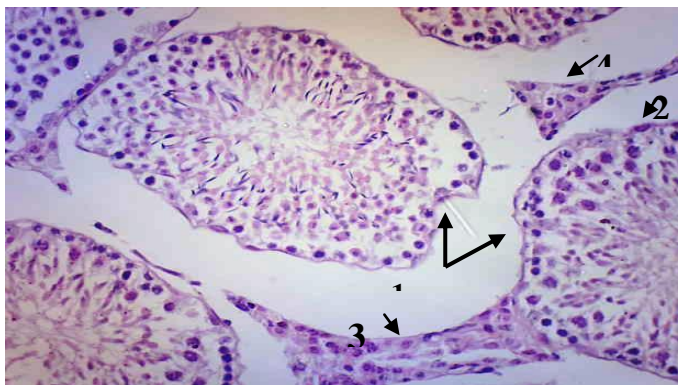
Sertoli cells, with fibroses like appearance was also reported. Some Seminifer -ous tubules appeared empty from germinal & sertoli cells, sometimes these cells were aggregate in the lumen of Seminiferous tubules fig (6,8, 10,11,12).

T4 : Over dose2

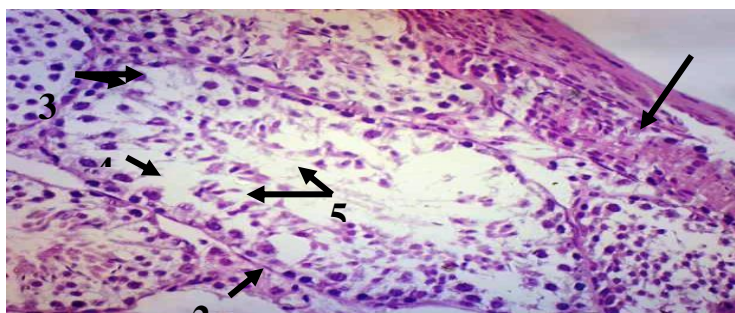
This group showed an increase in the fibroses of interstitium and seminiferous tubules fig (13). Aggregation of the germinal cells in the lumen of seminiferous tubules. On the other hand many seminiferous tubules appeared empty from germinal cells, fig (14, ,15.16.17).



**Fig (1) :**Section through the Testis of control mice showing normal Seminiferous tubules (1) .normal lumen of Seminiferous tubules & germinal layers(2).normal Interstitium (3), H&E, 40X .

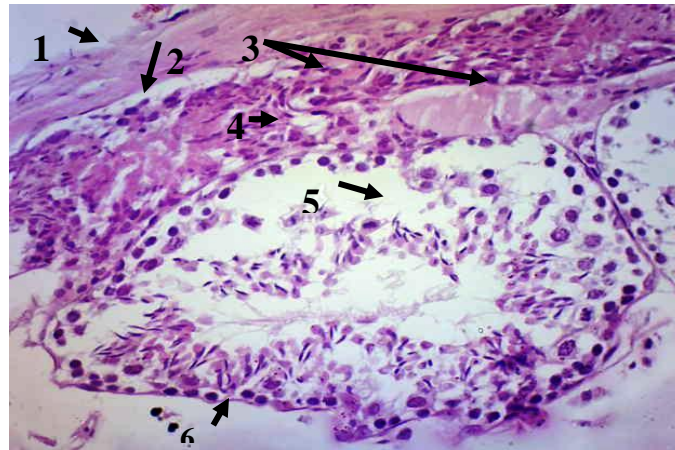


**Fig (2):** Section through the Testis of Therapeutic group showing , Shrinkage of Seminiferous tubules & increased space between it(1). Increased thickens the wall of Seminiferous tubules(2). degeneration of Leydig cells & the interstitium(3)&(4). H&E, 40X.

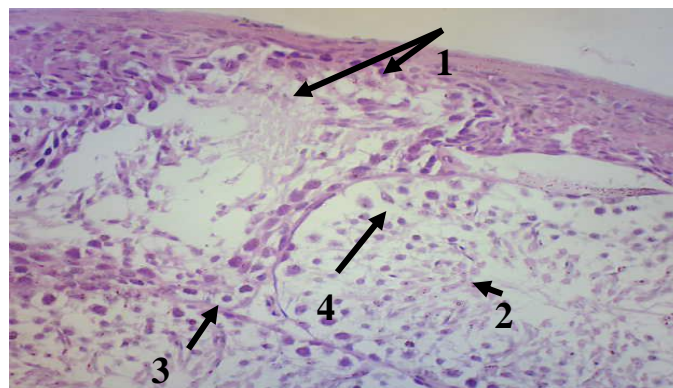


**Fig (3):** Section through the Testis of Therapeutic group showing , fibroid like appearance in interstitium & Leydig cells(1). degeneration in Sertoli cells(2). vacuolation in germinal layers(3) . increase the space between the germinal layers( 4). degeneration in primary Spermatocytes & Spermatids (5) .H&E, 40X.

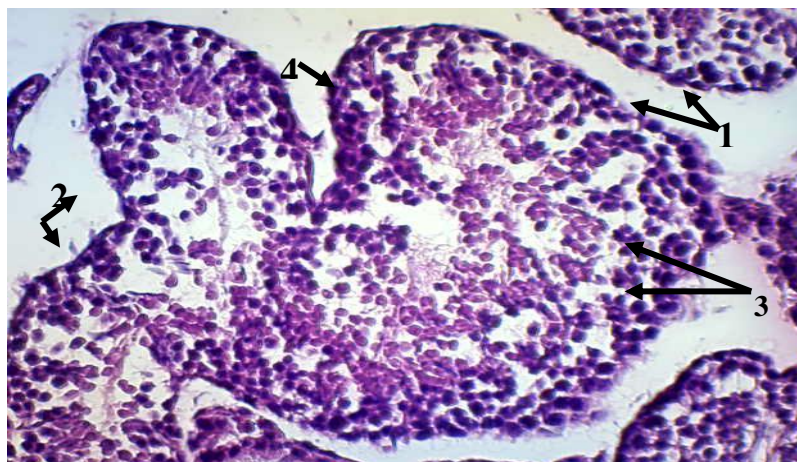




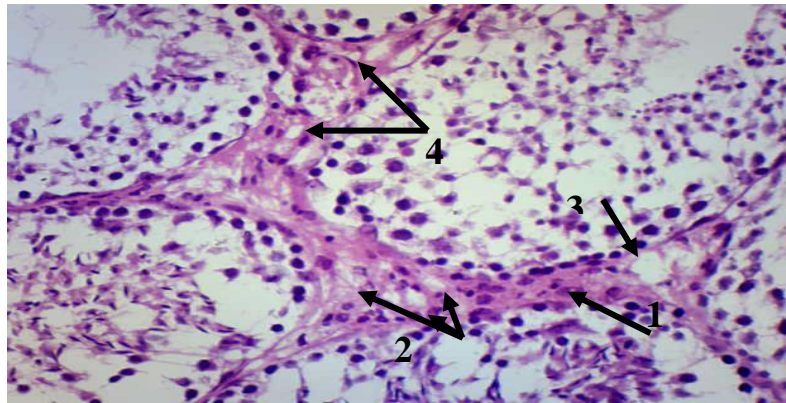
**Fig (4):** Section through the Testis of Therapeutic group showing increased thickness of tunica albuginea(1),degeneration in interstitium (2). fibroses like appearance in interstitium & Leydig cells(3). vacuolation in interstitium(4). sloughing in germinal layers (5). reflect of Spermatids downward to the wall of Seminiferous tubules(6).H&E, 40X. .



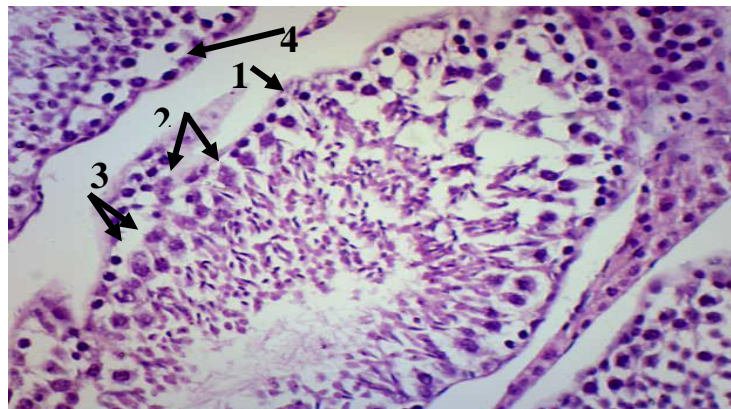
**Fig (5):** Section through the Testis of Therapeutic group showing, fibroses like appearance in germinal cell& Sertoli cells(1). apoptosis in germinal cell (2). Degeneration in Spermatogonial cells(3).increased the space between the Sertoli cells(4). H&E, 40X..



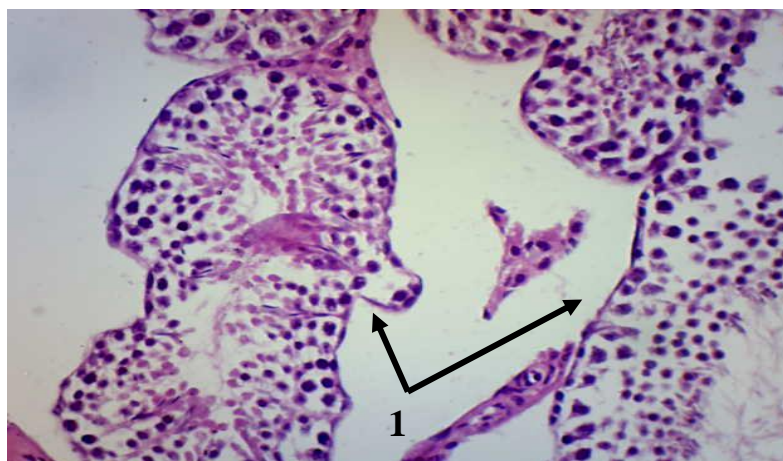
**Fig (6):** Section through the Testis of Over dose1 group showing ,increased the space between the Seminiferous tubules(1).Shrinkage of Seminiferous tubules(2).apoptosis in primary spermatocytes & increased the space between the germinal cells (3). Increased thickens the wall of Seminiferous tubules (4). H&E,40X.



**Fig (7):** Section through the Testis of Over dose1 group mice showing ,fibroses like appearance in interstitium & Leydig cells(1). degeneration in Leydig cells(2).necrosis in interstitium (3).vaculation in interstitium (4) . H&E,40X.

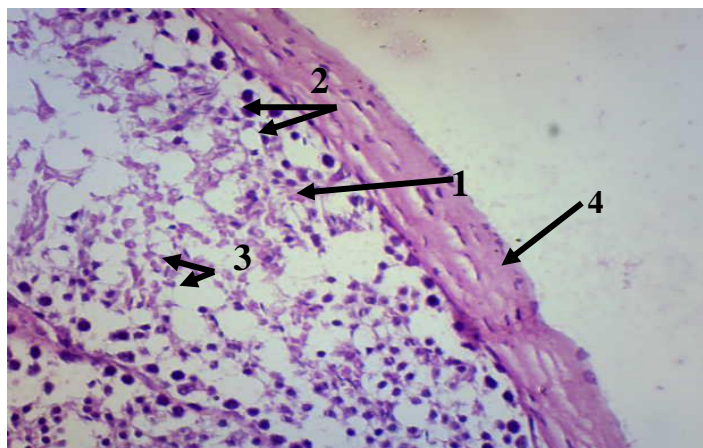


**Fig (8):** Section through the Testis of Over dose1 group mice showing , reflect of Spermatids upward to the wall of Seminiferous tubules (1). fibrosis like appearance of Sertoli cells (2). degeneration in Primary Spermatogonial cells(3), (4). H&E,40X.

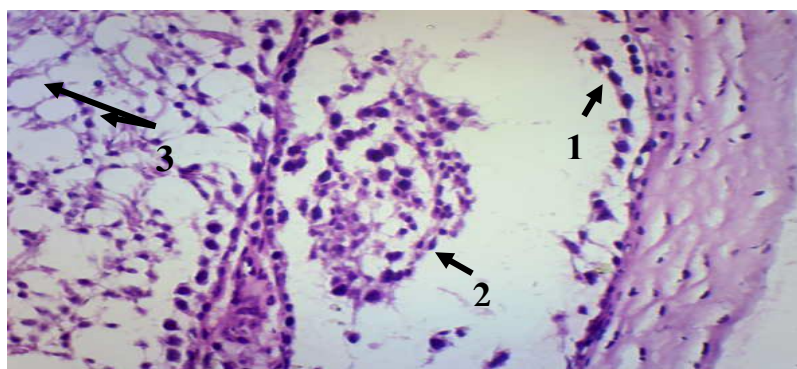


**Fig (9):** Section through the Testis of Over dose1 group showing ,Shrinkage in Seminiferous tubules & increased the space between it. H&E ,40X.

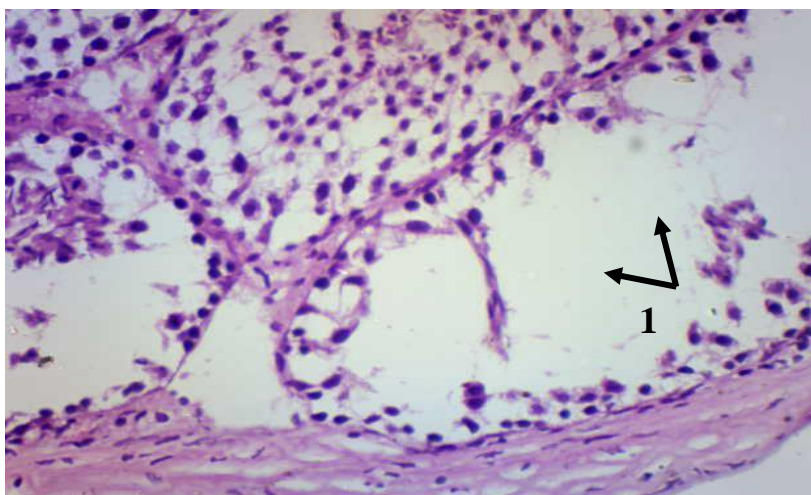




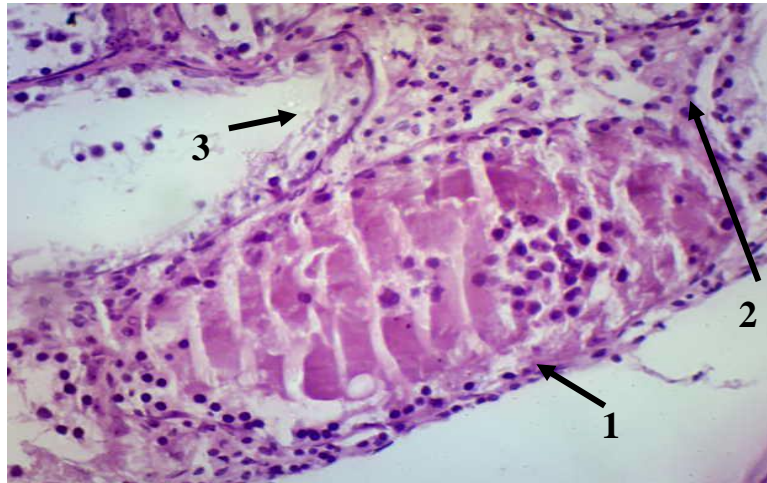
**Fig (10):** Section through the Testes of Over dose1 group mice showing , degeneration in Spermatogonia cells(1). vacuolation in Primary Spermatocytes (2). apoptosis in Spermatids (3). increase in the thickness of tunica albuginea (4). H&E,40X.



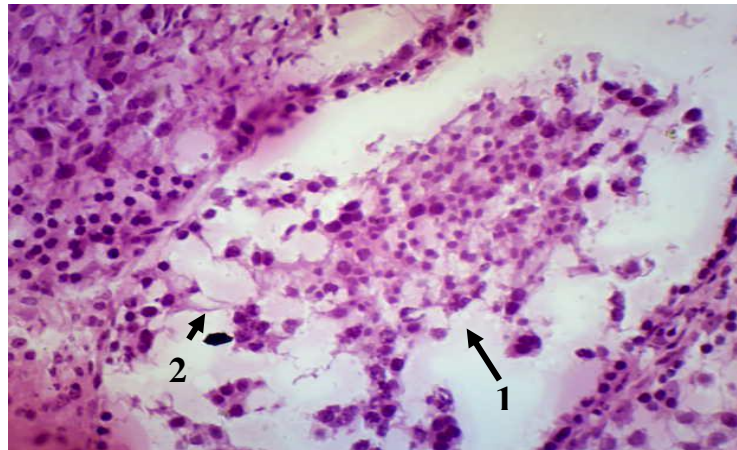
**Fig (11):** Section through the Testis of Over dose1 group showing ,sloughed Spermatogonia (1).aggregate the germinal cells in the lumen of Seminiferous tubules(2). vacuolation in germinal cells(3) . H&E,40X.



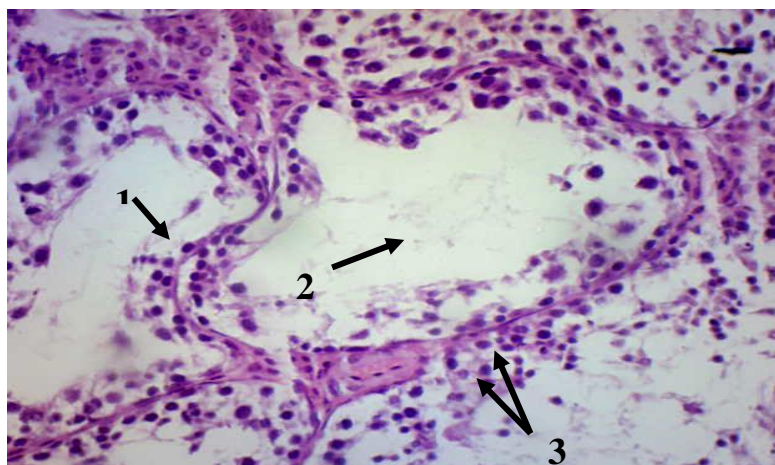
**Fig (12):** Section through the Testis of Over dose1 group showing , Empty the Seminiferous tubules from germinal cells. H&E,40X.



**Fig (13):** Section through the Testis of Over dose2 group showing , fibroses like appearance in Seminiferous tubules (1) .fibroses like appearance in interstitium & Leydig cells (2).Degeneration & fibrosis in primary spermatocytes (3).H&E,40X.

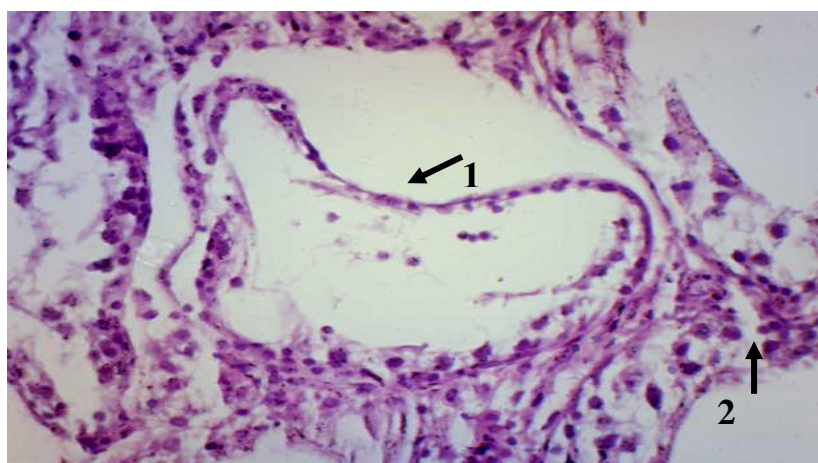


**Fig (14):** Section through the Testis of Over dose2 group showing , fibroses like appearance in Seminiferous tubules & aggregate the germinal cells in lumen of Seminiferous tubule(1). vacuolation in germinal layer (2).H&E,40X.

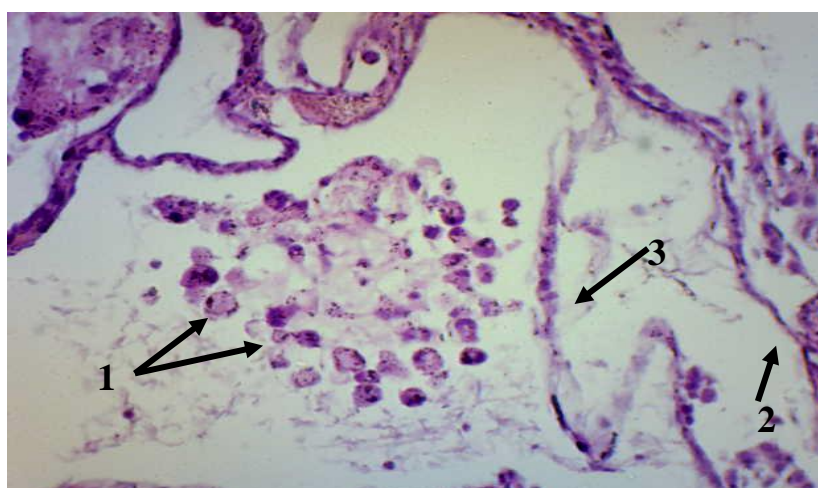

**Fig (15):** Section through the Testis of Over dose2 group showing , folding in Seminiferous tubules wall(1). empty the tubules from germinal layer cells(2). degeneration in interstitium (3).H&E,40X..





**Fig (16):**Section through the Testis of Over dose2 group showing, increased folding in Seminiferous tubules wall(1). degeneration the wall of Seminiferous tubule( 2) .H&E,40X.



**Fig (17):** Section through the Testis of Over dose2 group showing , apoptosis & degenerated the germinal cells in lumen of Seminiferous tubules(1). degeneration the wall of Seminiferous tubules(2).sloughed the Spermatogonia(3).H&E,40X

## Discussion

The testis is considered to be the most important organ in male reproductive system. It characterized by two main functions, synthesis of steroid hormones and production of spermatozoa [22]. Various affect in spermatogenesis, among these factors are chemical agents such as drugs and toxic elements in environmental pollution [23]. The results of the present study revealed many histological alterations of testicular tissue. Some of these alterations are the thickening of tunica albuginea and seminiferous tubules walls and shrinkage of it with irregular wavy appearance. The basal lamina plays an important role in maintaining substances transportation between interstitial tissue and spermatogonic epithelium and in maintaining the structural and functional integrity of tissue [24]. Many

testicular disordered are associated with thickened of the tubular wall of the seminiferous tubules , which impairs the relationship between the inner tubular population and the interstitium. With increased thickness of seminiferous tubules many pathological signs appear inside of it, sertoli cells function will disturbed and finally affect the differentiation of germ cells and arrest spermatogenesis .The disturbance of basem -ent membrane of seminiferous tubules subsequently affect on oxygen , nutrition and hormones transport [25].The over expres -sion of IV collagen fibers that cause thickening of seminiferous tubules are related with dysfunction of spermatoge -nesis since the IV collagen fibers are secreted by sertoli cells [26]. The present results showed that post treatment with Piroxicam drug has an effect on Leydig cells and interstitium, degeneration, vacula -tion, necrosis and



fibrosis like appearance were showed in Leydig cells and interstitium. In normal testicular function, Leydig cells are the center of fertility regulation and reproductive health by producing testosterone<sup>[27]</sup>. Leydig cells are induced by LH to produced arachidonic acid and testosterone, the post treatment by indomethacin drug will affect Leydig cells secretion. Sperm maturation is a complex processes and PG plays an important role in regulating luminal environment<sup>[17]</sup>. There is also a relationship between Leydig cells and blood vessels suggested that these cells are at high risk of exogenous toxicants<sup>[28]</sup>. The degeneration of Sertoli cells, and dilated intercellular space between germ cells, the sloughing of the germ cells and aggregation in the lumen of seminiferous tubules, all these signs are due to defect in the function and structure of Sertoli cells. Sertoli cells disturbance lead to lose of germ cells and finally lead to disturbance of testicular tissue<sup>[29]</sup>. Sertoli cell has also an important role in the development of the germ cells by forming blood testis barrier that protect germ cells, and by supply nutrient and hormones to germ cells<sup>[30]</sup>.

Degeneration, vaculation, and apoptosis in Spermatogonia, primary spermatocytes and Spermatids which increased with high doses, may reflect the disturbance of microenvironment of the Sertoli cells, that affect the protein synthesis machinery essential for differentiation of germ cells. These proteins are secreted in highest level in normal testis during Spermatids elongation and spermatation<sup>[31]</sup>. The post treatment by indomethacin can causes germ cells apoptosis, degeneration, deplete -on in number in seminiferous tubules due to ability of the drug in inhibiting PG synthesis<sup>[20]</sup>. The downward movement of Spermatids within the wall of seminiferous tubules, is an alert of toxicity in the testis by the drugs<sup>[32]</sup>. Post treatment by indomethacin affect fatty acids, lipids level in testicular tissues which are necessary for cell signaling, hormones production, proliferation and differentiation of germ cells, and it may cause cell injury due to ability to bind covalently with the macromolecules, in situation where intracellular levels of NADH, NADPH, GSH are very low<sup>[18]</sup>. The results of the present study are in accordance with the previous studies such as that reported by Yano *etal*, 2002<sup>[23]</sup>, Saeed *etal*, 2009<sup>[17]</sup>, Mogliner *etal*, 2006<sup>[18]</sup> and Subramanian, 2009<sup>[18]</sup>. Who used parace -tamo -l, indomethacin, Diclofenac drugs in the treatment of rats.

### **Conclusion:**

In conclusion data from the present study showed that Piroxicam caused a clear histological alterations in testicular tissue, including thickening of tunica albuginea and seminiferous tubules. Degeneration, necrosis, fibrosis like appearance in interstitium and Leydig cells. Degeneration

,necrosis, vaculation ,sloughing and deplete -on in germ cells. Therefore it is recommen -ded that usage of this drug have harmful side effects on male fertility.

### **Reference**

- 1.Steinmeyer, J. (2000). Pharmacological basis for the therapy pain and information with NSAIDs . *Arthritis Res.*, 2:379-385.
- 2.Modi,C.M.;Mody,H.B.;Patel,G.B.;Dudhatra,G. B.;Kumar,A. and Avale,M. (2012). Toxicopathological overview of analgesic anti inflammatory drug in animals. *J. of Applied pharmaceutical Science*,2(1):149-157.
- 3.Song,H.;Lim,H.;Das,SK.;Paria,B.C. and Dey, S.K. (2000). Dysregulation of EGF growth factor during COX2 in the uterus during reattachments reaction of blastocysts with the luminal epithelium correlates with implantation failure in life deficient mice. *Mol. Endocrinol.*, 14: 1147-1161.
- 4.Wang,P.;Chan,H.C.;Leung,PS.;Chung,YW.;Wong,YL.;Lee,WM.;Ng,V. and Dun, NJ. (1999). Regulation of anion secretion by cyclooxygenase and prostanoids in culture epididymal epithelia from rat. *J.Physiol* ,514 : 809-820.
- 5.Beak,S.G.;Willson,L.G.;Lee,C. and Eli ng,TE. (2002). Dual function of NSAIDs in inhibition cyclooxygenase and induction NSAIDs – activated gene. *J.P.E.T.*, 301: 1126 -1131.
- 6.Olivier,P.;and Riendeau, . (2005). Cyclooxygenase-2 contributes to constitutive prostanoid production in rat kidney and brain. *Biochem. J.* ,391:561-566.
- 7.Vane, J.R.; Bakhle, Y.S. and Botting, R.M. (1998). Cyclooxygenase 1&2 . *Annu . Rev.Pharmacol.Toxicol.*,38:97-120.
- 8.Thompson,T.W.; Tee, L.; McBride, D. ; Quency, D. and Liddiar, G.S. (2005). Long term NSAIDs use in primary care :changes over decade and nice risk factor for gastrointe -stinal adverse event. *Rheumatolog -y*,44(10): 1308-1310.
- 9.Jak,C. and Kretz,J. (2006). Thorasic surgery in children pain control after surgery . *Anasthe -siol Intensivemed Notfallmed Schmerzther*, 41(10):666-8.
- 10.Siddiqui,A. (2007). Synthesis of piroxica -m related heterocyclic molecular and evaluation of their biological activity . Thesis, Science collage, Lahore univ.
- 11.Karim A, Noveck R, McMahon FG, Smith M, Crosby S, Adams M, and Wilton J. (1997).Oxaprozin and piroxicam, nonst - eroidal anti- inflammatory drugs with long half-lives: effect of protein binding differences on steady state pharmacokinetic -s. *J Clin Pharmacol*.37(4);267-78 Apr.

12. Elivin, J.; Yang, C. and Matzuk, M. (2000). Growth differentiation factor -9 stimulates progesterone synthesis in granulosa cell via Prostaglandin E2 receptor pathway. *Proc. Natl. Acad. Sci. USA.*, 97 : 10288 - 93.
13. Gattego Sandan, S.; Novalbos, J.; Rosado, A.; Gisber, J.; Galves, Mugica, M.; Garcia, A.; Pajares, J. and Francesco, A. (2004). Effect of Ibuprofen on COX and Nitric oxide Synthase of Gastric mucosa : correlation with endoplasmic lesions and adverse reaction. *Digestive diseases and sciences*, 49:1538- 1544.
14. Ebiad, H.; Dkhil, M.; Danfour, M.; Tohamy, A. and Gabry, M. (2007). Piroxicam induced hepatic and renal histopathological changes in mice. *L.J.M.*, 2(2):82-89.
15. Burdan, F.; Rozylo, K.; Szumilo, J.; Dub -ka, J. and Kelracz. (2008). Cyclooxygenase inhibitor affected bone mineralization in rat fetuses. *Cell Tissue Org.*, 187 (3):221-232.
16. Burdan, F. (2004). Developmental toxicity of Ibuprofen and tolemin administration in triple daily doses to wistar rats. *Birth Defects Res.*, 71:321-330.
17. Saeed, S.; Anwar, N.; Khan, M. and Sarfras, N. (2009). Effect of chronic treatment with cyclooxygenase inhibitor on reproductive male rat. *J. Aub. Med .Coll .Abottabad*, 21(3):66-71.
18. Subramanian, S. (2009). Diclofenac induced toxic manifestation on adjuvant induced arthritic rats peripheral and reproductive organ of male wistar rats *rattus norvegicus*. *J. of Toxicology & Environmental Health Sciences*. 1(1):12-21.
19. Cheuk, B.; Chew, S.; Fiscus, R. and Wong, P. (2002). Cyclooxygenase-2 Regulates Apoptosis in Rat Epididymis through Prostaglandin D2. *Biology of Reproduction*, 66:374-380.
20. Mogliner, J.; Lurie, M.; Coran, A.; Nativ, O.; Shiloni, E and Sukhotnik, I. (2006). Effect of diclofenac on germ cells apoptosis following testicular ischemia – reperfusion injury in rat. *Pediatric Surgery Int.* 22:99-105.
21. Bancroft, J. and Stevens, C. (1982). Theory and practice of histological techniques .2nd edition .Churchill Livingstone. 113-114.
22. Carreau, S.; Bouguibas, S.; Lambard, S.; Galeraud Denis, I.; Genissel, C. and Levallet, J. (2002). Reproductive system : aromatase and estrogen .*Mol. Cell .Endocrinol.* , 139: 137-43.
23. Yano, C.L and Dolder, H. (2002). Rat testicular structure and ultrastructure after paracetamol treatment .*Contraception*, 66 : 463 -67.
24. Richardson, L.L.; Kleinman, H.K and Dym, M. (1998). Altered basement membrane synthesis in testis after tissue injury. *J. Androl.*, 19:145-55.
25. Zheng, Y.; Zhang, X.; Zhong, J.; Cheng, F.; Rao, T. and Yao, Y. (2008). The effect of artery-ligament and artery preserving varicocele on the ipsilateral testis in rat. *Urology* , 72:1179-84.
26. Mattias, H. Kinga, G and Alexander, N. (2005). Laminin (alpha)1 chain male infertility caused by absence of Laminin (alpha)2 chain. *A.M.J. Pathol.* 167P823-33.
27. Dharia, S.; Slane, A.; Jian, M., Conley, A.J and Parker, C. (2004). Colocalization of P450c17 and cytochrome b5 in androgen synthesizing tissues of human. *Biol. Repro.* , 71:83-88.
28. Boekelheide, K. (1993). Sertoli cell toxicant In: Russel LD, Griswold MD. The sertoli cell Clearwater, Florida: Academic Press, P. 552-75.
29. Monsees, T.K.; Franzin, M.; Gebhardt, S.; Witertstein, U.; Schill, W.B and Hayatpour, J. (2002). Sertoli cell as a target for reproductive hazard . *Andrologia*, 32:239-46.
30. Richburg, J.H, (2000). The relevance of spontaneous and chemical – induced alteration in testicular germ cell apoptosis to toxicology. *Toxicology letters*: 79-86.
31. Manivannan, B.; Mittal, R.; Goyals, S.; Ansari, A.S & Lohiya, N.K (2009). Sperm characteristics & ultrastructure of testis after long-term treatment with the methanol sub fraction of carica papaya seeds . *Asian J. Androl.*, 11:583-99.
32. Foley, G. (2001). Mechanism of male reproductive organ toxicity. *Toxicologic Pathology* , 29(1):49-63.

## دراسة نسجية عن تأثير عقار البايروكسيكام على خصى الفئران البيض *Mus musculus*

علي خضير عبيس      عبد الكريم سالم ماهود

E.mail: [dean\\_coll.science@uoanbar.edu.iq](mailto:dean_coll.science@uoanbar.edu.iq)

### الخلاصة:

العقاقير غير الستيرويدية المضادة للالتهابات من أكثر العقاقير التي توصف كعلاج في أمراض الروماتزم لأنها تمتلك فعالية مسكنة للألم، مخفضة للحرارة ومضادة للالتهابات. وأن عقار البايروكسيكام ينتمي إلى هذه المجموعة، ويستخدم في كبح الالتهابات، والآلام المصاحبة لالتهاب المفاصل الرثواني، والتهاب المفاصل العظمية و اعتلال الفقرات. الهدف من هذه الدراسة هو لتقييم تأثير العقار على نسيج الخصية في الفئران السويسرية. أستخدم في الدراسة أربع وعشرون من ذكور الفئران البيض، حيث قسمت بصورة عشوائية إلى مجموعتين، المجموعة الأولى هي مجموعة السيطرة (عدد 6) والمجموعة الثانية هي المجموعة التجريبية (عدد 18) والتي قسمت إلى ثلاثة مجاميع ثانوية (عدد 6 لكل منها)، حقنت بتراكيز (0.29: 1.428 و 2.857) ملغ/كغ من وزن الجسم يوميا بالترتيب لمدة أربعة عشر يوما، وفي اليوم الخامس عشر قتلت الفئران واستخرجت الخصى ومن ثم تم تهيئة المقاطع النسجية. أظهرت النتائج ما يلي أن جميع الحيوانات المختبرية التي تعرضت للعقار أظهرت انخفاضا في أعداد الخلايا الجرثومية، وحدثت تنخر في الخلايا الجرثومية، وخصوصا في سليفات النطف و خلايا ليدج إضافة إلى حدوث ترسب الألياف البيض فيها، وزيادة المسافات البينية بين خلايا سرتولي في النبيب المنوي الواحد، وزيادة سمك الغشاء القاعدي في بطانة النيبات المنوية و بطانة جدران الشريينات الصغيرة، لذلك يوصى بأن الاستخدام المستمر للعقار سيكون له تأثيرات جانبية على خصوبة الذكور.