

## Topical Application to Mixture of Honey with Cod Liver Oil as a Novel Therapy to Treat Contaminated Skin Wounds in Rabbits Model

Jihad Abdulameer Ahmed<sup>1</sup>; Jinan A. Bannai<sup>2</sup>; Rana K. Abdulsamad<sup>2</sup>

1. Pathology & poultry diseases Dept., College of Veterinary Medicine, Uni. of Basrah, Iraq.

2. Surgery and theriogeniology Dept., College of Veterinary Medicine, Uni. of Basrah, Iraq.

E-mail: dr.jihad.vet@gmail.com

### Abstract

Contaminated wounds are common in all animals and human being; their treatments may complicated and need for prolong duration, therefore the current study aimed to investigate an alternative way to treat the contaminated wounds by using natural compounds that accelerate wounds healing; these study achieved on 30 local rabbits that exposed to surgical excision and contaminated by *Staphylococcus aureus* then divided into 5 groups in which 6 animals of each and treated for 14 days as the following: the first group treated with honey, second group treated with cod liver oil, third group treated with mixture of honey and cod liver oil, fourth group treated with fucidin while the fifth group contaminated with bacteria only. The results showed moderate ( $1.55 \pm 0.11$ ) wound contraction and healing in first group, while the second group showed ( $1.77 \pm 0.10$ ) was delayed in wound contraction and healing, the third group showed ( $1.0 \pm 0.13$ ) which regarded the excellent and optimal wound contraction and healing, the fourth group showed ( $1.77 \pm 0.12$ ) which delayed wound healing and contraction, finally the fifth group showed ( $3.07 \pm 0.11$ ) in which no signs of wound contraction and healing. In conclusion, the using of mixture of natural compounds like honey and cod liver oil may accelerate wound contraction and healing and keep the wounds sterile.

**Key words:** Pathological, honey, cod liver oil, mixture, contaminated wounds.

### (التطبيق الموضوعي لخليط من العسل مع زيت كبد الحوت كعلاج جديد للجروح الجلدية الملوثة في نموذج الارانب)

جهاد عبدالامير احمد<sup>١</sup> ، جنان عبد العزيز بناي<sup>٢</sup> ، رنا خلف عبد الصمد<sup>٢</sup>  
١. فرع الأمراض وأمراض الدواجن ، كلية الطب البيطري ، جامعه البصرة ، العراق.  
٢. فرع الجراحة والتوليد ، كلية الطب البيطري ، جامعه البصرة ، العراق.

### الخلاصة

الجروح الملوثة تحدث بصورة عامه في كل الحيوانات وحتى الإنسان وعلاجها يكون معقدا ويحتاج إلى وقت طويل لذلك تهدف هذه الدراسة للكشف عن طريقه بديله لعلاج الجروح الملوثة باستخدام مواد طبيعيه لتسريع عمليه التئام الجروح، أجريت الدراسة على 30 أرنب محلي عرضت لجروح ولوثت بجرثومه الكوريات العنقوديه

الذهبية وبعد ذلك تم تقسيم هذه الارانب الى 5 مجموعات متساويه حيث كل مجموعه احتوت على 6 ارانب وعولجت لمدته 14 يوم وكالتالي: المجموعه الاولى عولجت بالعسل، المجموعه الثانيه عولجت بزيت كبد الحوت، المجموعه الثالثه عولجت بمزيج العسل وزيت كبد الحوت، المجموعه الرابعه عولجت بعلاج الفيسوسيدين، اما المجموعه الخامسه فتركبت بدون معالجه واعتبرت مجموعته سيطره سالبه. اظهرت النتائج حدوث تقلص جرحي والتئام متوسط الشده وبمعدل  $(0.11 \pm 1.55)$  في المجموعه الاولى، اما المجموعه الثانيه فقد تاخر تقلص الجروح والتئامها وبمعدل  $(0.10 \pm 1.77)$ ، بينما لوحظ في المجموعه الثالثه تقلص والتئام مثالي وممتاز للجروح الملوته وبمعدل  $(0.13 \pm 1.0)$ ، اما المجموعه الرابعه فقد تاخر تقلص والتئام الجروح فيها وبمعدل  $(0.12 \pm 1.77)$ ، واخيرا لوحظ في المجموعه الخامسه عدم وجود علامات للتقلص الجرحي والتئام وكان بمعدل  $(0.11 \pm 3.07)$ . نستنتج من هذه الدراسه ان استخدام مزيج من المواد الطبيعيه مثل العسل وزيت كبد الحوت ممكن ان يعجل من التئام الجروح وكذلك يبقي الجروح نظيفه سريريا.

**الكلمات المفتاحيه:** مرضيه، العسل، زيت كبد الحوت، مزيج، جروح ملوته.

## Introduction

In veterinary medicine, the wounds are frequently managed as open wounds; therefore, the healing of such wounds may rely on granulation tissues formation, wound contraction, and epithelization to achieve the wound closure (1).

The contamination of wound with *Staphylococcus aureus* pathogens which regarded as adaptable in which the opportunistic pathogen has an ability to persist and multiply in a variety of environments, hence it causes wide spectrum of diseases in both human and animals (2). It responsible a major pathogen for skin wound infections, toxic shock syndrome, arthritis, endocarditis, osteomyelitis, and food poisoning (3). Moreover, staphylococcal infections resulting in substantial economic losses in livestock industry worldwide (4). In rabbits, these pathogens infect dermal lesions and invade subcutaneous tissues causing different lesions including pododermatitis, multisystemic abscessation and mastitis (5). In humans showed nearly one third of the population was currently colonized by *S. aureus* (6).

On other hand, high osmolarity has been considered a valuable tool in the treatment of infections because it prevents the growth of bacteria and encourages healing (7). Moreover, the use of sugar to enhance wound healing had been reported for several hundred

patients (8). High osmolarity can safely be achieved topically by using sugar paste or honey, though honey has additionally been regarded as having specific antibacterial properties, for example honey diluted seven to fourteen-fold beyond the point where osmolarity ceased to be completely inhibitory still prevented growth of *Staphylococcus aureus* (9). Honey has a biological plausibility because inhibition of bacterial growth has been shown using impregnated honey discs (10), or incorporating honey into agar plates, but how much of this inhibition is due to inherent antimicrobial properties or to its hyperosmolar nature is unknown (11).

In addition, honey having anti-inflammatory activity, there have been numerous observations reported of honey reducing edema and exudate, minimizing scarring and having a soothing effect when applied to inflamed wounds and burns, moreover, direct evidence of an anti-inflammatory activity showed histologically in observation of reduced numbers of inflammatory cells present in biopsy samples (12).

Cod liver oil is a nutritional supplement derived from liver of cod fish, it has high levels of omega 3 fatty acid, vitamin A and vitamin D. also, it was reported the cod liver oil had a beneficial in wound healing as it enhances epithelization and revascularization (13). Wound healing

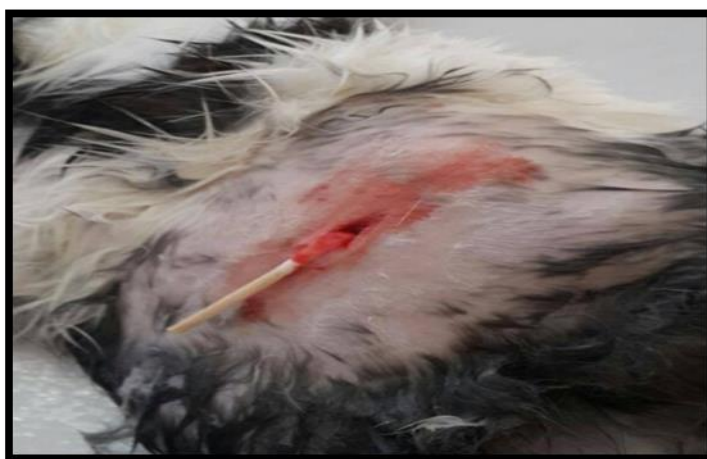disorders are therapeutic problem of extensive clinical importance as wound healing involves multiple complicated events. Even in modern times wound healing agents continue to puzzle medicals scientists. Thus it is reasonable to search for simple and easily available or otherwise treatment to establish novel therapeutic approaches, on other hand, the current study designed to investigate the beneficial effects of the mixture of honey and cod liver oil in healing of staphylococcal contaminated wounds focusing in the pathological basis of these effects.

#### Materials And Methods

In order to know the whole effects of the mixture of cod liver oil and honey on the healing of staphylococcal contaminated wounds and its pathological events, these study performed in 30 rabbits. The rabbits (local domestic rabbits weighted  $1500 \pm 150$  grams) were randomly divided into five groups of six animals each. The rabbits were shaved on the dorsal aspect of their skin after clipping the dense hair. An area of about  $3\text{cm}^2$  in diameter was defined wounds of each animal in the experiment as shown in (Figure.1).

with marker, the previously marked sites were anesthetized using 2% lidocaine taken in 1.0 cc syringes having needle gauge of 29. Each site of proposed incision was injected with this local anesthetic subcutaneously taking precaution that none of the deeper structures or blood vessels was penetrated. The animals were allowed 10 minutes for the drugs to take effect. Surgically induced wounds were made on a limited area measured  $3\text{cm}^2$  in diameter in the back of the animals. Incision full thickness skin wounds were made surgically with scalpels in the closely shaved dorsal skin of rabbits under conditions of local anesthesia.

The bacterial strain was prepared from fully confirmed culture of *Staphylococcus aureus* in microbiology laboratory of College of Veterinary Medicine at University of Basrah, in which the experimental infection by *Staphylococcus aureus* made with 0.5ml of bacterial suspension with density equal to  $8 \times 10^8$  cfu / ml as described by (14). This bacterial concentration was inoculated into the surgically excised



**Figure (1):**Inoculation of surgical wound by *Staphylococcus aureus* to induce contaminated wound.

The experimental design of the study as the following:

**1. First group:** It was treated daily for 14 days by 2ml of honey (pure raw untreated commercially honey obtained from College of Agriculture at University of Basrah) which applied on the staphylococcal contaminated wound.

**2. Second group:** It was treated daily for 14 days by 2ml of cod liver oil (Hansel / Germany) which applied on the staphylococcal contaminated wound.

**3. Third group:** It was treated daily for 14 days by a mixture of 2ml of honey and 2ml of cod liver oil that applied on the staphylococcal contaminated wound.

**4. Fourth group:** It was treated daily for 14 days by fucidin ointment (Sodium fusidate 2% ointment) obtained from (Leo pharmaceutical company/Denmark) that applied on the staphylococcal contaminated wound which served as positive control group.

**5. Fifth group (G5):** It was inoculated only by *Staphylococcus aureus* suspension, which regarded as negative control.

At the end of experiment, the gross pathological wounds lesions were examined and then the biopsies taken from each animals to made the histopathological processing and sectioning then stained by hematoxyline and eosin according to method of (15) to investigate the microscopical features of each group. The percentage of wound healing areas in the contaminated incised wounds on day 14 was measured according to methods of (16) and modified by (17) as following:

$$X = 100 - \frac{\text{wound length or area}}{\text{wound length}} \times 100.$$

The statistical analysis was applied by one-way ANOVA and the mean differences were significant at the level of  $P < 0.05$  in using statistical package for social science SPSS program.

## Results

### I. Wound contraction results:

The wounds contraction were expressed as a reduction in percentages of the original wounds size at day 14 of treatments, which showed the rapid and optimal wound healings with excellent re-epithelization in the third group (Honey + Cod liver oil) which obvious of no infection, cleanness, healthy surfaces and observable decrease in the wound surface after 14 days of treatment (Figure.4), the healing wound contraction score showed reduced ( $1.0 \pm 0.13$ ) per centimeter compared with other groups in the experiment (Table.1). While the first group (Honey) showed ( $1.55 \pm 0.11$ ) per centimeter of wound healing contraction score which regarded the second rapid area of healing and re-epithelization compared with other groups (Table.1), in which the wound appeared bright red in color, dry and didn't elevate above the wound edges after 14 days of treatment (Figure.2).

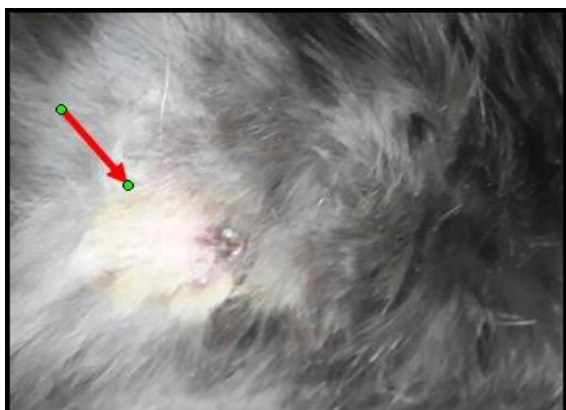
The healing area of the second group (Cod liver oil) and the fourth group (Fucidin positive control) showed ( $1.77 \pm 0.10$ ) and ( $1.77 \pm 0.12$ ) per centimeter wound healing contraction scores respectively which regarded the slowest areas of wounds healing and re-epithelization among other treated groups in the experiments (Table.1), in which the wounds showed slight increase in the center with marked granulation tissue formation and edema (Figure.3,5).

**Table (1): The percentage of wound healing and contraction score in the contaminated wounds after 14 days of treatments.**

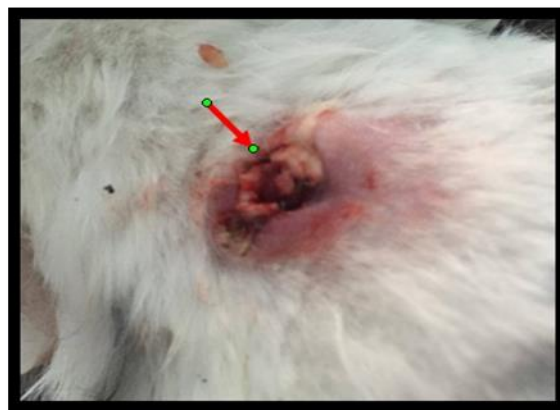Groups	Mean $\pm$ SD
G1 (Honey)	1.55 $\pm$ 0.11 b
G2 (Cod liver oil)	1.77 $\pm$ 0.10 c
G3 (Honey + Cod liver oil)	1.0 $\pm$ 0.13 a
G4 (Fucidin) Positive control	1.77 $\pm$ 0.12 c
G5 (Negative control)	3.07 $\pm$ 0.11 d

\*Different letters vertically refers to presence a significant difference between groups at level  $P \leq 0.05$ .

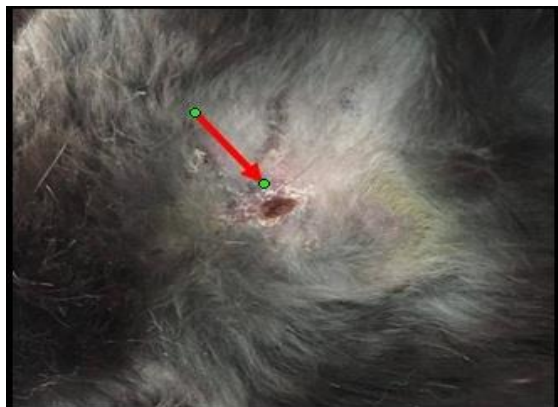In addition, the negative control group (Fifth group) showed (3.07  $\pm$  0.11) per centimeters of wounds healing contraction score (Table.1), which showed no improvement of wound healing, with inflammatory swelling, signs of bleeding and elevated margins in addition to width of wound area and delayed re-epithelization



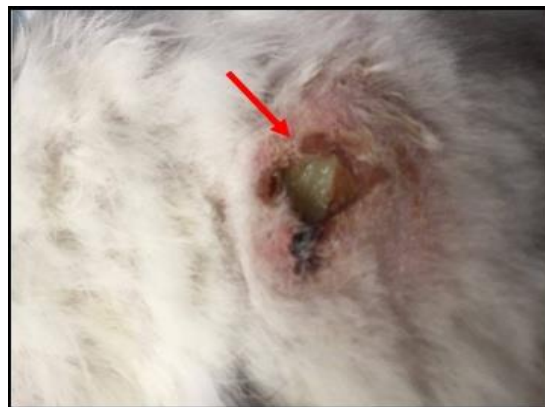
**Figure (2):** Wound healing of the first group, showed the width of wound contraction area and scab formation with marked delayed re-epithelization.



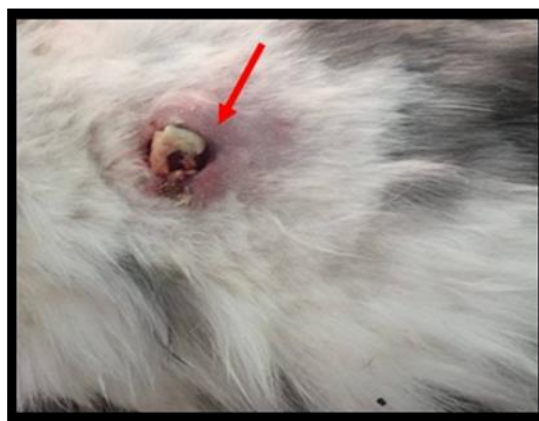**Figure (3):** Wound healing of the second group, the wound showed slight increase in wound center and elevated margins with marked granulation tissue formation.



**Figure (4):** Wound healing of the third group, showed no infection, cleanness, healthy surface and observable decrease in the wound surface.



**Figure (5):** Wound healing of the fourth group, showed poor wound contraction area and healing with delayed re-epithelization.



**Figure (6):** Wound healing of the fifth group, showed inflammatory swelling with sign of bleeding and elevated margins, also width of wound area and delayed re-epithelization.

## II. Histopathological results:

The histopathological results after 14 days of treatment revealed many microscopical features, in which the first group (honey) showed circumscribed area of re-epithelization and scab formation with marked area of re-keratinization and fibroplasia, which led to complete closure of wound (Figure.7,8).

The second group (cod liver oil) showed inflammatory cell infiltration mainly macrophages and few

neutrophils beneath and around the opened wound region, also there was a scab formation in the margins of the wound with proliferation of fibroblasts in the dermis, the healing was delayed that obvious from microscopical features which revealed poor epithelization mechanism led to delayed healing (Figure.9,10).

The microscopical features of third group (honey and cod liver oil) showed complete area of re-epithelization and re-keratinization, also presence of

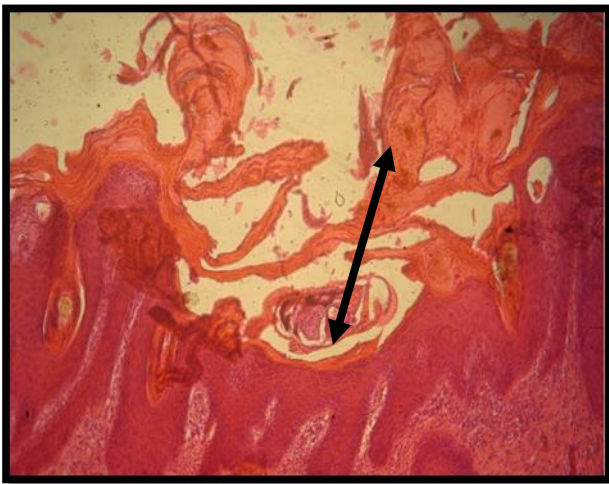


collagen bundles and inflammatory cells infiltration with fibroplasia in the dermis region, which regarded the optimal and excellent wound healing group among other groups (Figure.11,12).

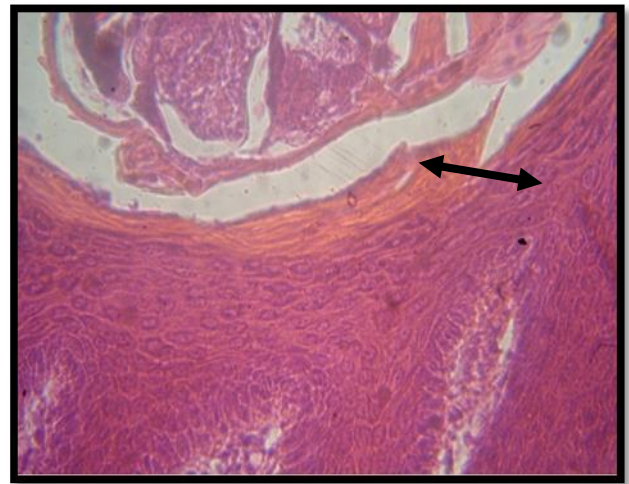
The fourth group (Fucidin) showed wide margins of wound with poor area of re-epithelization and healing, also presence of few collagen bundles in the dermis, with area of bleeding in the surface of the wound, also presence of few inflammatory cells around the

wound, the healing was delay in this group resulted in patent wound closure (Figure.13,14).

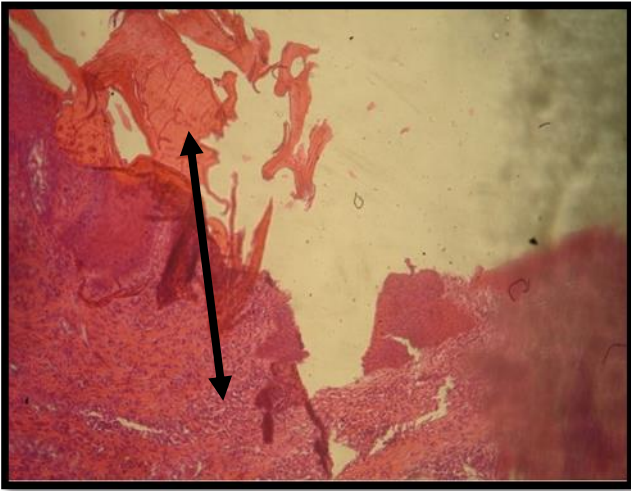
The fifth group (negative control) showed inflammatory cells infiltration mainly macrophages and neutrophils with area of hemorrhage and congested blood vessels, fibroplasia, micro-absession also present, in addition there was no sign of healing that obvious from delayed healing and persistent the wound opened and inflamed (Figure.15,16).



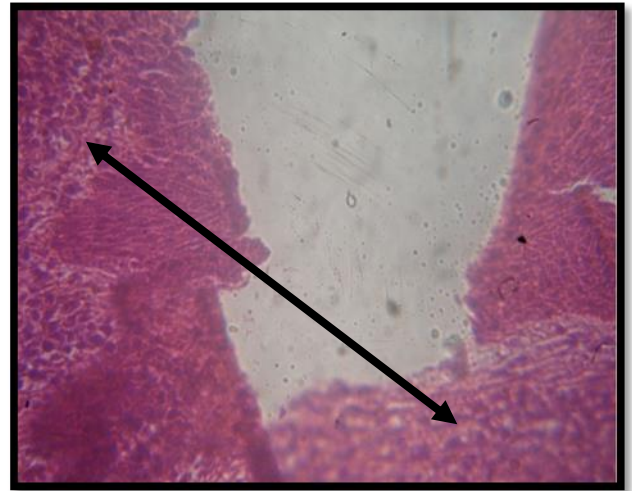
**Figure (7):** Histopathological section of first group showed circumscribed area of re-epithelization and scab formation (↔). H&E stain. 10X.



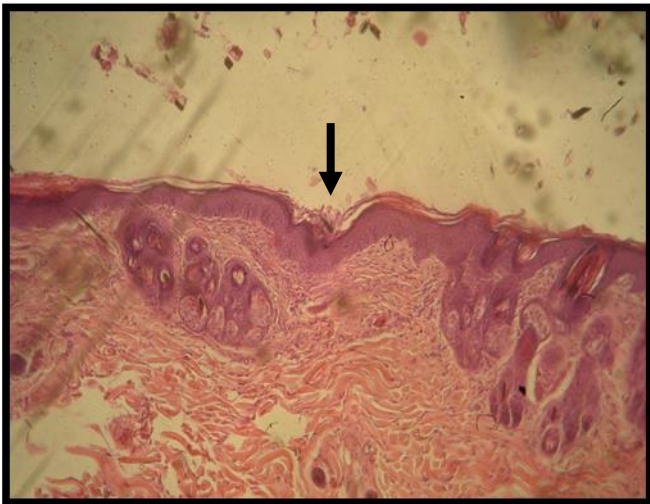
**Figure (8):** Histopathological section of first group showed marked area of re-epithelization and re-keratinization with fibroplasia and scab formation (↔). H&E stain. 40X.



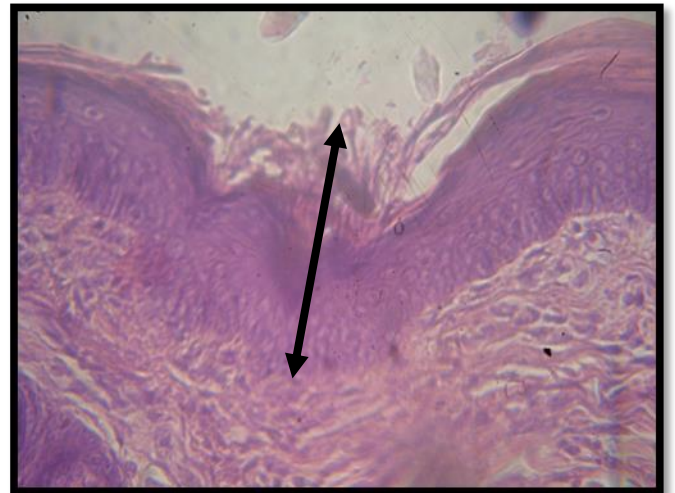
**Figure (9):** Histopathological section of second group showed inflammatory cell infiltration beneath the open wound, also there was scab formation in the margins of the wound (↔). H&E stain. 10X



**Figure (10):** Histopathological section of second group showed mononuclear cell infiltration and few neutrophils around the wound (↔). H&E stain. 40X

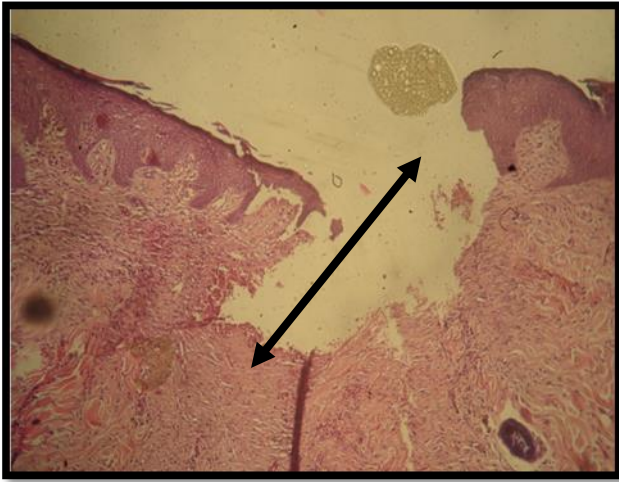


**Figure (11):** Histopathological section of third group showed complete area of re-epithelization and keratinization (→) H&E stain. 10X.

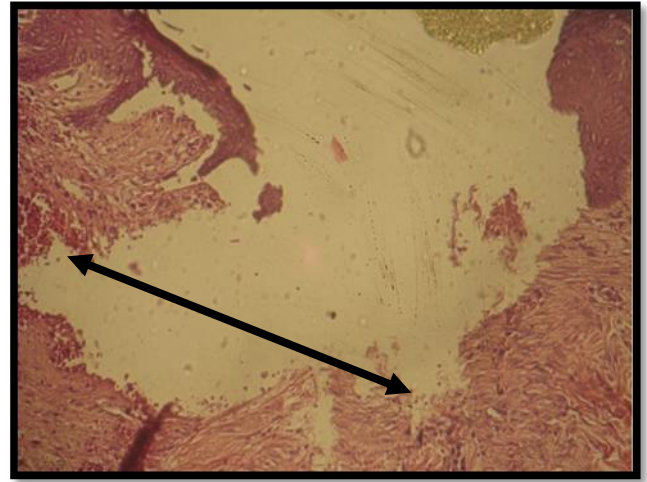


**Figure (12):** Histopathological section of third group showed complete re-epithelization, also presence of collagen bundles and inflammatory cells with fibroplasia in the dermis (↔). H&E stain. 40X.

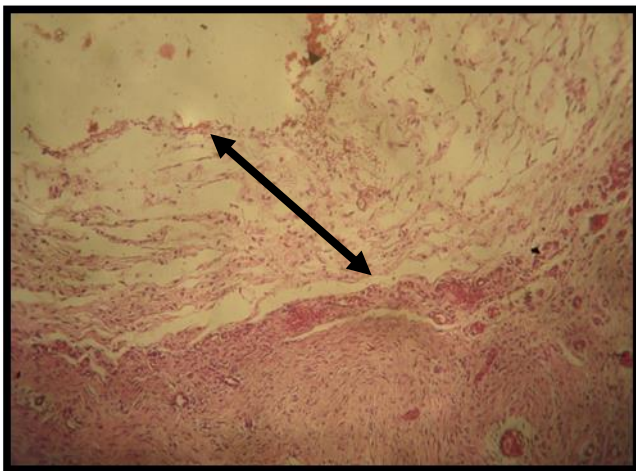




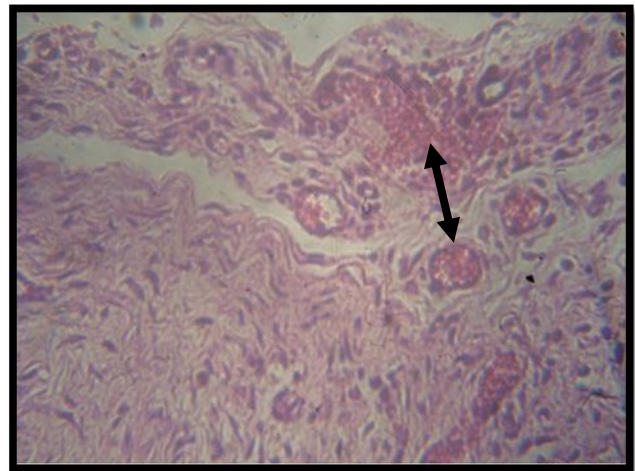
**Figure (13):** Histopathological section of fourth group showed wide margins of wound, also presence of few collagen bundles in the dermis (↔). H&E stain. 10X.



**Figure (14):** Histopathological section of fourth group showed area of bleeding in the surface of the wound, also presence of few inflammatory cells around the wound (↔). H&E stain. 40X.



**Figure (15):** Histopathological section of fifth group showed infiltration of inflammatory cells mainly macrophages and neutrophils, no presence of sign of healing (↔). H&E stain. 10X.



**Figure (16):** Histopathological section of fifth group showed inflammatory cells infiltration, area of hemorrhage, congested blood vessels, fibroplasia and micro-abscessation (↔). H&E stain. 40X.

## Discussion

Open wounds healing are still a complex and continuous dramatic processes, therefore, the histopathological evaluation of such wounds has divided into three histologically overlapping stages those are: the inflammatory, the repair or proliferative, and the remodeling stages.

The current results of the first group (honey) regarded the second most hasten of the wound healing, that obvious from the fast mechanism of wound contraction and scab formation, also it was evidenced histologically by granulation, collagen deposition and lack of infection or abscess formation as well no edema at the site of wounds, these facts may due to the antimicrobial action of the honey which cure the contaminated pathogens in addition to enhance the effects of fibroblasts in order to collagen deposition then hasten the closure of the opened wounds by accelerate re-epithelization mechanism, these ideas may agreed with (18) who mentioned that honey able to decrease inflammatory edema, hasten sloughing of devitalized tissue, attract macrophages which cleanse the contaminated wounds, provides a local cellular energy source and protectively covers the wound, in addition the a high osmolarity, acidity and hydrogen peroxide content confer honey with antibacterial properties.

The results of second group (cod liver oil) showed marked granulation tissue formation with few events of wound contraction also appeared histologically with inflammatory cells infiltration and delayed the processes of re-epithelization, these may due to the cod liver oil have low effects as direct antibacterial agent to cure of contaminated pathogens at site of wound that may delayed the mechanism of wound contraction and

re-epithelization as a result of inflammatory response against the bacteria, these facts may similar to these mentioned by (19) when reported the cod liver oil may act to reduce the infection indirectly by stimulating the activity of leukocytes in order to proliferation of lymphocytes and monocytes to release its cytokines, which are activators of the immune response to infection, also cod liver oil showed accelerated both the epithelial and vascular component of healing in the site of sterile and cleaned wound.

The our results of wound contraction showed excellent with fast healing and re-epithelization in the third group (honey and cod liver oil) that may due to the mixture of honey and cod liver oil leaded to accelerate the process of inflammatory scavenging of contaminated bacterial pathogen, also hasten the repair and proliferation of fibroblasts and enhanced collagen deposition in the site of injury that caused the rapid mechanism of healing and wound closure in these group, this idea may agreed with (20,21) they mentioned that in addition to antimicrobial effects of honey it has anti-inflammatory and antioxidant properties promotes open wound healing and facilitate debridement, moreover, the cod liver oil has high levels of omega 3 fatty acid, vitamin A and vitamin D, therefore, it has a beneficial role in wound healing as it enhances epithelization and revascularization.

The synergistic effects of the mixture of honey and cod liver oil which seemed that the cod liver oil attributed to complete epithelization by induce fibroblasts activation and proliferation in order to produce collagen and then hasten the closure of opened wound, these investigation may similar to idea mentioned by (22), therefore, surgically-induced full thickness dermal wounds resulted in faster

epithelization because of the cod liver oil contain of vitamins A and D seemed to be responsible of these effects with synergism of antibacterial action of honey; on other hand that found honey increased epithelization in wounds that may due to accelerate the proliferation of keratinocytes and / or fibroblasts at the site of injury, these facts may agreed with the observation of (23) they mentioned that honey increased metalloproteinase-9 in cultured human keratinocytes, and these factor was observed to degrade type IV collagen in the basement membranes then further facilitate migration of keratinocytes to the site of injury.

The result of fourth group (fucidin) showed delayed the process of healing and re-epithelization, these might due to the prolong time of it action as antibiotic that may take a time to cure the staphylococcal pathogen of contaminated wound that may inhibit or delay the proliferation of fibroblast to signaling the collagen deposition at the site of injury, then the healing process was delayed, these facts may similar to facts mentioned by (24) in which the topical fusidic acid was found to delay wound healing by prolonging fibroblast proliferation.

The result of fifth group (positive control) showed no sign of wound contraction, closure and re-epithelization these may resulting from the persistent wound inflammation due to multiplication and colonization of the bacteria that completely inhibited the mechanism of healing and wound contraction, these may agreed with (25) they believed that aerobic or facultative pathogens such as *Staphylococcus aureus* is primarily responsible for delayed healing and infection in all types of wounds.

In conclusion, the using of the mixture of honey and cod liver oil accelerate the wound cleaning and contraction

then hasten wound healing and re-epithelization.

### References

1. Waldron, D.R. and Zimmerman-Pope, N. (2003). Superficial skin wounds. In: Slatter D, ed. Textbook of Small Animal Surgery. 3<sup>rd</sup> ed. Philadelphia: WB Saunders, pp:259–273.
2. Cucarella, C.; Tormo, M.; Ubeda, C.; Trotonda, M.; Monzon, M; Peris, C.; Amorena, B.; Lasa, I. and Penades, J. (2004). Role of biofilm associated protein bap in the pathogenesis of bovine *Staphylococcus aureus*. Infect. Immun., 72, 2177-2185.
3. Gao, J. and Stewart, G. (2004). Regulatory elements of the *Staphylococcus aureus* protein A (Spa) promoter. J. Bacteriol., 186, 3738-3748.
4. Mork, T.; Tollersrud, T.; Kvitle, B.; Jorgensen, H. and Waage, S. (2005). Genetic diversity of *Staphylococcus aureus* isolated from ovine intramammary infections in Norway. Vet. Microbiol., 106, 265-273.
5. Segura, P.; Martinez, J.; Peris, B.; Selva, L.; Viana, D.; Penades, J. and Corpa, J. (2007). Staphylococcal infections in rabbit does on two industrial farms. Vet. Rec., 160, 869-872.
6. Mainous, A.; Hueston, W.; Everett, C. and Diaz, V. (2006). Nasal carriage of *Staphylococcus aureus* and methicillin-resistant *S. aureus* in the United States. Ann. Fam. Med., 4, 132-137.
7. Archer, H.; Barnett, S.; Irving, S.; Middleton, K. and Seal, D. (1990). A controlled model of moist wound healing: comparison between semipermeable film, antiseptics and sugar paste. J Exp Pathol, 71:155-70.
8. Knutson, R., Merbitz, L.; Creekmore, M. and Snipes, H. (1981). Use of sugar and povidone-iodine to enhance wound healing: five year's

- experience. South Med J, 74:1329-1335.
9. Cooper, R. and Molan, P. (1999). The use of honey as an antiseptic in managing *Pseudomonas* infection. J Wound Care, 8:161-4.
  10. Karayil, S.; Deshpande, S. and Koppikar, G. (1999). Effect of honey on multidrug resistant organisms and its synergistic action with three common antibiotics. J Postgrad Med, 44:93-6.
  11. Cooper, R. and Molan, P. (1999). Antibacterial activity of honey against strains of *Staphylococcus aureus* from infected wounds. J Roy Soc Med, 92:283-5.
  12. Subrahmanyam, M. (1998). A prospective randomized clinical and histological study of superficial burn wound healing with honey and silver sulfadiazine. Burns; 24(2):157-61.
  13. Ali, M. and Radad, K. (2011). Cod liver oil/honey mixture: An effective treatment of equine complicated lower leg wounds. Veterinary World, Vol.4(7): 304-310.
  14. Wills, F.; Kerrigan, C.; Soothill, S. (2005). Experimental bacteriophage protection against *Staphylococcus aureus* abscesses in a rabbit model. Antimicrob. Agents Chemother., 49, 1220-1221.
  15. Luna, L.G. (1968). Manual of histological staining of force institute of pathology. 3rd Ed., McGraw hill book, New York. 258:134-135.
  16. Gurung, S. and Skalko-Basnet, N. (2009). Wound healing properties of *Carica papaya* latex: in vivo evaluation in mice burn model. J Ethnopharmacol; 121:338-341.
  17. Alizadeh, A.M.; Ahmadi, A.; Mohammadzadeh, M.; Paknejad, M. and Mohagheghi, M.A. (2009). The effect of HESA-A, an herbal-marine compound, on wound healing process: an experimental study. Res J Biol Sci; 4:298-302.
  18. Staunton, C. J.; Halliday, L. C. and Garcia, K. D. (2005). The use of honey as a topical dressing to treat a large, devitalized wound in a stump tail macaque (*Macaca arctoides*). Contemp. Top. Lab. Anim. Sci., 44(4):43-5.
  19. Hashemipour, M.; Ghasemi, A.; Dogaheh, M. and Torabi, M. (2012). Effects of locally and systemically applied n-3 fatty acid on oral ulcer recovery process in rats. WOUNDS; 24(9):258-266.
  20. Majtán, J. (2009). Apitherapy, the role of honey in the chronic wound healing process. Epidemiologie Mikrobiologie Imunologie 58: 137-140.
  21. Terkelsen, L.H., Eskild-Jensen, A., Kjeldsen, H., Barker, J.H. and Hjortdal, V.E. (2000). Topical application of cod liver oil ointment accelerates wound healing: an experimental study in wounds in the ears of hairless mice. Scandinavian Journal of Plastic and Reconstructive Surgery and Hand Surgurg 34: 15-20.
  22. Ramesh, K.V., Mahindrakar, M.B. and Bhat, E.P. (1993). A new role for vitamin D: cholecalciferol promotes dermal wound strength and re-epithelization. Indian Journal of Experimental Biology 31: 778-779.
  23. Iftikhar, F., Arshad, M., Rasheed, F., Amraiz, D., Anwar, P. and Gulfraz, M. (2010). Effects of acacia honey on wound healing in various rat models. Phytotherapy Research 24: 583-586.
  24. Gurel, M.S.; Naycı, S.; Turgut, A.V. and Bozkurt, E.R. (2015). Comparison of the effects of topical fusidic acid and rifamycin on wound healing in rats. Int Wound J. 12(1):106-10.
  25. Bowler, P.G.; Duerden, B.I.; Armstrong, D.G. (2001). Wound microbiology and associated approaches to wound management. Clin Microbiol Rev. 14: 244-269.