

Topical Treatment of Melasma with Lactic Acid Cream: a Comparative Study with Glycolic Acid Cream

Ali F.Al-Saadi* ,Khalifa E. Sharquie**, Sabeeh A. Al-Mashhadani **

ABSTRACT:

BACKGROUND:

Melasma is a major cosmetic problem affecting young people mainly females. There are many modalities of topical therapy but usually end with relapse.

OBJECTIVE:

To evaluate the efficacy and safety of 6% lactic acid cream in comparison with glycolic acid cream 6% and 12% in the treatment of melasma.

PATIENTS & METHODS:

This is a COHORT comparative therapeutic trial conducted in the Department of Dermatology-Baghdad Teaching Hospital.

Sixty patients with melasma were included in this study. They were divided into three groups; each one consisted of twenty patients. Group one treated with 6% lactic acid cream, group two with 6% glycolic acid cream, group three with 12% glycolic acid cream. Patients were evaluated clinically using wood's light & melasma area severity index score before and after therapy. Follow up was done regularly every two weeks for two months to assess the improvement and side effects. Also patients were seen monthly for 3 months after the end of treatment to see any relapse. All patients were instructed to apply the cream once at night for two months with broad spectrum sun block SPF > 30 before sun exposure.

RESULTS:

In group one of the study using lactic acid cream 6%, 14 patients completed the study; their ages ranged from 26-42 years, with a mean $31.9 \pm SD 4.1$ years, twelve patients (86%) were females and 2 (14%) males. The result showed that the average score before treatment was 11.45 ± 2.9 while after treatment score changed to 5.31 ± 2.71 ; so the improvement was 6.14, this represented a (54%) decrease and was statistically significant (p value < 0.0005). No important side effects were recorded during the treatment or follow up. In group two of the study using 6% glycolic acid cream, 13 patients completed the treatment; their ages ranged from 17- 40 years with a mean $27.5 \pm SD 6.8$ years, all patients (100%) were females. The result revealed the mean of score before treatment was 10.56 ± 2.77 while after treatment score became 8.36 ± 2.85 . So the average decrease was 2.2 which represented (21%) decrease and it was statistically significant (p value < 0.0005). No important side effects were recorded during the treatment or follow up. While In group 3 of the study using 12% glycolic acid cream, 15 patients completed the study; their ages 22 to 40 years with a mean of $31.8 \pm SD 5.3$ years. Thirteen (87%) patients were females and 2 (13%) males. The result showed that the mean before treatment was $12.54 \pm 3, 4$ while after treatment score changed to 6.06 ± 2.38 . So the average decrease was 6.48; this represented 52% decrease and was statistically significant (p value < 0.0005). No important side effects were recorded during the treatment or follow up. The three agents were statistically significant for the treatment of melasma and there were no significant difference between 6% lactic acid cream and 12% glycolic acid cream (p value = 0.654). But there were significant difference between 6% glycolic acid cream and the others.

CONCLUSION:

Lactic acid cream 6% is a new, non costly, alternative effective, safe agent and as effective as 12% glycolic acid cream for the treatment of melasma.

*Department, Baghdad Teaching Hospital, Iraq.

**Department of Dermatology & Venereology,
College of Medicine, University of Baghdad.

INTRODUCTION:

Melasma is a major cosmetic problem especially among dark skin women⁽¹⁾, affecting almost 30% of Iraqi females in their reproductive age⁽²⁾. There

are many modalities of treatment especially bleaching agents like hydroquinone but unfortunately the relapse rate is usually high after therapy. This may be attributed to continuous exposure to triggering agents like sun light and contraceptive pills which are the main exacerbating factors⁽¹⁾.

Alpha hydroxy acids(AHAs) are non-toxic acids formed naturally in foods, such as sugar cane(glycolic acid),fermented apples (pyruvic acid)⁽³⁾. The benefit of AHAs have long been recognized .Cleopatra, e.g. applied sore milk (lactic acid) to her face; Arabian women also used yogurt as source of lactic acid. English, Spanish and Arabian women used lemon juice (citric acid).Polynesian women found similar benefit from sugar cane juice (glycolic acid)⁽⁴⁾. AHAs decrease corneocyte cohesion by promoting exfoliation of the outer layers of the stratum corneum. In high concentrations, they cause epidermolysis. Other properties of AHAs include decreased fragmentation of elastic fibers, increase number and quantity of elastic fibers, increase volume of epidermis, and tightening superficial skin layers⁽⁵⁾.

Lactic acid is a member of AHAs consists of a mixture of a lactic acid and its condensation products, such as lactoyl lactic acid, which slowly reverts to lactic acid on dilution with water. Lactic acid is miscible with water, alcohol, and ether, immiscible with benzene, carbon disulphide, chloroform, and light petroleum. Lactic acid contains the equivalent of not less than 88% W/W and not more than 92% W/W of Lactic acid (C₃H₆O₃) . Lactic acid is used in dermatology for treatments of warts, xerosis of the skin⁽⁶⁾, also it is used for chemical peeling⁽⁴⁾, treatment of vitiligo as antioxidant action⁽⁷⁾. Topically applied lactic acid increases spontaneous secretion of vascular endothelial growth factor by human reconstructed epidermis⁽⁸⁾. Also lactic acid used in 5% and 12% in order to improve skin smoothness and in the appearance of lines and wrinkles, with 12% lactic acid show more dermal changes⁽⁹⁾. Lactic acid as a member of AHAs also used to reduce the thickness of stratum corneum by reducing corneocyte cohesion; this may be used to control dry skin, ichthyosis, follicular hyperkeratosis, seborhic keratosis, actinic keratosis and verrucae vulgaris⁽¹⁰⁾. Alpha – hydroxy acids have been used as effective peeling agents in a variety of conditions including melasma⁽⁴⁾,but the clinical experience is limited to glycolic acid as peeling agent and as cream only which is expensive and may not be available in

every center. Lactic acid is also an α -hydroxy acid that has similar activities to glycolic acid but it was not used as therapeutic agent until recently used as peeling agent and approved its effectiveness, and the improvement was 56% in the treatment of melasma⁽¹¹⁾.

To evaluate the efficacy and safety of 6% lactic acid cream in comparison with glycolic acid cream 6% and 12% in the treatment of melasma.

PATIENTS AND METHODS:

This study was conducted at the out-patients department of dermatology - Baghdad teaching hospital.

The study consists of three Groups:

Group one: treatment with 6 % lactic Acid cream.

Group two: treatment with 6% glycolic Acid cream

Group three: treatment with 12% glycolic acid cream

Sixty patients with melasma were included in the study, twenty patients for each group. Consent was obtained from all participants in the study

All patients had melasma for more than two months; they have not received treatment for at least two months before the study.

Pregnant and lactating women and those females on contraceptive pills were excluded from the study. The diagnosis was made on clinical bases. A detailed history was taken from each patient stressing on the age, sex, duration of melasma, time of onset, marital states, sun exposure duration and drug history. For female's patients, history of menstrual cycle, premenstrual flare up, history of pregnancy, contraceptive pills intake, use of cosmetics, dye and their effect on melasma and any associated diseases and aggravating factors was optioned.

A careful examination of melasma was done including the following:-

Site of melasma (cheeks, nose, upper lip, forehead and chin). Distribution of melasma: butterfly, mask shape, horse shoe and others. The presence or absence of associated other diseases, (acne, hirsutism, hair fall).

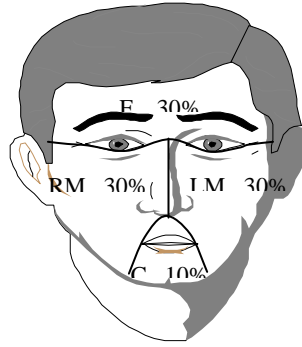
Wood's light examination was done for all patients to assess the depth of pigmentation and the response of therapy.

Evaluation:

A- Clinical assessment:

Melasma severity was scored with melasma area and severity index (MASI)⁽¹²⁾. In this system the face is divided into four areas:

for head, right malar, left malar and chin that correspond respectively to 30%, 30%, 30%, 10%, of total facial area .



The melasma in each of these areas was graded on three variables:

1- Percentage of total area involved on a scale: this was measured by using transparent square paper. By this method the melasma and the total face surface areas were measured accurately by square centimeters, then the percentage of the total melasma area relative to the total area of the face was measured and scoring done as follows:

Scale 0: no involvement

Scale 1: < 10 %

Scale 2: 10 - 29 %

Scale 3: 30 - 49 %

Scale 4: 50 - 69 %

Scale 5: 70 - 89 %

Scale 6: 90 - 100 % involvement

2- Darkness scoring from (0-4) was recorded according to the previously designed color chart⁽¹¹⁾. The scale of each patient was graded according to the comparison between darkness of melasma and the score of the chart as follows:

Scale 0 : no melasma

Scale 1 : light brown

Scale 2 : brown

Scale 3 : dark brown

Scale 4 : black

3- Homogeneity on scale of 0 (minimal) to 4 (maximal)

The MASI was then calculated by the following equation:

$$\text{MASI} = 0.3 (\text{DF} + \text{HF}) \text{AF} + 0.3 (\text{DMR} + \text{HMR}) \text{AMR} + 0.3 (\text{DML} + \text{HML}) \text{MAL} + 0.1 (\text{DC} + \text{HC}) \text{AC}$$

Where D is darkness , H is Homogeneity , A is area , F is forehead , MR is right malar, ML is left malar, C is chin , and the values 0.3,0.3,0.3, & 0.1 stands respective percentage of total facial area⁽¹²⁾.

MASI was measured before treatment as base line and after treatment regularly each two weeks till the end of two months.

B. subjective method:-

Depending on recording improvement in patients satisfaction measures during the time course of intervention and graded as follows:

Grade 0= not satisfied, Grade1= moderately or partially satisfied, Grade2= greatly but not fully satisfied, Grade3= fully or completely satisfied.

Statistical Analyses

Statistical analyses were used in all parameters. Paired t-test was used to compare the mean of MASI change resulting from treatment.

P-value of less than 0.05 was considered significant⁽¹³⁾.

ANOVA test was used to compare the mean of MASI after treatment among the three groups

Treatment

Concentration of lactic acid solution was 90.08, PH= 1.8 made in England by May & Baker LTD Dagenham, and the desired concentration result from the following equation:

$$C_1 V_1 = C_2 V_2$$

$$90 \times 10 = 6 \times 150$$

C: concentration V: volume

To obtain 6 % lactic acid cream PH=3.2 take (10 ml) of 90% lactic acid solution mixed gently with 140 gm. Aqua Rosa.

Six percent lactic acid cream was given to all patients in group I, in group II the concentration of glycolic acid cream is 6 %, PH= 4.5 made in India by micro LABS Limited available in the market and in group III the concentration of glycolic acid cream is 12 %, PH= 3.5 made in India by micro LABS Limited available in the market. We instructed all patients to use the creams initially on alternate day over the melasma area for one week to prevent irritation then daily use at night for two months. The patient instructed to avoid sun exposure as much as possible during and after treatment, and encourage to use sun screen (SPF>30).

Follow up

The patients were seen regularly every two weeks for two months to assess the response for treatment, recording the side effects and calculate MASI for each patient and after the end of the course of treatment all patients were then seen monthly for three months as follow up for any signs of relapse.

RESULTS:

Group one: Treatment With 6% Lactic Acid Cream. Twenty patients with melasma were included in this study. Six patients defaulted from the study because of hard situation of our country, 14 patients completed the study, their ages ranged from 26 to 42 years with a mean of $31.92 \pm SD$ of 4.1 years. Twelve patients (85.7%) were females and 2 males (14.2 %). Eight females (57.1) were married and 4 (28.5 %) were unmarried. Five patients (35.7%) had history of previous pregnancies, family history of melasma was positive in 6 patients. The duration of melasma ranged from 1 to 8 years with a mean $\pm SD$ of 3.1 ± 1.9 years. According to Fitzpatrick classification, 10 patients were skin type III and 4 patients skin type IV⁽³⁾. Wood's light examination showed increased contrast in 8 patients (epidermal type) & partial contrast in 6 patients (mixed type). Morphological forms of melasma were as follows: butter fly like in 8 patients (57.14 %), mask like in 4 patients (28.5 %), horse shoe like 1 patient (7.1 %) and localized 1 patient (7.1%).

Group two: Treatment With 6% glycolic Acid Cream. Twenty patients with melasma were included in this study. Seven patients defaulted from the study for unknown reasons. Thirteen patients completed the study, their ages ranged from 17 to 40 years with a mean of $27.5 \pm SD$ 6.8 years. Thirteen patients (100 %) were females, seven females (53.8) were married and 6 (46.1 %) were unmarried, five patients (38.4%) had history of previous pregnancies, family history of melasma was positive in 7 patients. The duration of melasma ranged from 3 months to 15 years with a mean $\pm SD$ of 3.9 ± 4.2 Years. According to Fitzpatrick classification, 8 patients were skin type III and 5 patients were skin type IV, wood's light examination showed increased contrast in 8 patients (epidermal type) & partial contrast in 5 patients (mixed type). Morphological forms of melasma were as follows:

Butter fly like in 6 patients (46.1 %), Mask like in 4 patients(30.7%),localized 2 patients (15.3%) & horse shoe like 1 Patient(7.69 %).

Group Three: Treatment With 12% glycolic Acid Cream. Twenty patients with melasma were included in this study. Five patients defaulted

from the study, 15 patients completed the study, their ages ranged from 22 to 40 years with a mean of $31.8 \pm SD$ of 5.3 years. 13(87 %) were females and 2 male (13%). Nine females (69.2%) were married and 4 (30.8%) were unmarried. Six patients (40%) had history of previous pregnancies, family history of melasma was positive in 9 of patients. The duration of melasma ranged from 3 months to 15 years with a mean $\pm SD$ of 3.3 ± 4.1 Years. According to Fitzpatrick classification, 11 patients were skin type III and 4 patients were skin type IV. Wood's light examination showed increased contrast in 10 patients (epidermal type) & partial contrast in 5 patients (mixed type). Morphological forms of melasma were as follows: Butter fly like in 7 patients (47 %), mask like in 6 patients (40%) and localized like 2 Patients (13.3 %).

Clinical results

In group I the average MASI score before treatment was 11.45 ± 2.9 While after treatment MASI score changed into 5.31 ± 2.71 , so the average decrease in MASI was 6.41. This represents a (54%) decrease and was statistically significant (P value < 0.0005). In group II the average MASI score before treatment was 10.56 ± 2.77 While after treatment MASI score changed into 8.36 ± 2.85 so the average decrease in MASI was 2.2. This represent a (21 %) decrease and was statistically significant (P value <0.0005). While In group III the average MASI score before treatment was 12.54 ± 3.4 while after treatment MASI score changed into 6.06 ± 2.38 so the average decrease in MASI was 6.48. This represent a (52%) decrease and was statistically significant (P value <0.0005).

Follow up

Group I: showed that only 3 patients had relapse since they failed to follow the instructions regarding broad spectrum sun block. Patients self-assessment: 13 patients were Grade2 (greatly but not fully satisfied), and one patient was Grade3.

Group II: showed that only 4 patients had relapse since they failed to follow the instructions regarding broad spectrum sun block. Patient's self-assessment: two patients were Grade 0, 8 patients were Grade1 and 3 patients were Grade 2.

Group III: showed that only 5 patients had relapse since they failed to follow the instructions regarding broad spectrum sun block.

Patient's self-assessment: two patients were Grade1, 12 patients were Grade2 and one patient was Grade2.

Side effect

Group I: no side effects were recorded a part from transient erythema which occurred in a minority

TOPICAL TREATMENT OF MELASMA WITH LACTIC ACID CREAM

of patients and did not necessitate stopping treatment.

Group II: no side effects were recorded.

Group III: no side effects were recorded a part from transient erythema which occurred in five of patients and did not necessitate stopping treatment.

Table 1: Multiple Comparisons among three groups and previous Iraqi study (using full strength lactic acid peel) by ANOVA Test.

Group	MASI before therapy			MASI after therapy			% of improvement Mean±SD	t-test & P value
	Range	Mean	SD	Range	Mean	SD		
I	11	11.45	2.9	9	5.3	2.7	54.6 ± 16.8	12.34 < 0.05
II	10.5	10.5	2.7	10	8.3	2.8	21.1 ± 12.8	5.41 < 0.05
III	11	12.5	3.4	9.4	6.06	2.3	52.1 ± 14.6	11.53 < 0.05
Lactic acid peel	15.6	14.05	5.7	9	6.08	2.6	56.7 ± 18.9	13.02 < 0.05
ANOVA test= 417.684 p value =0.027								

MASI = melasma area severity index

p < 0.05; statistically significant

Table 2: Showing the comparisons among different groups of treatment.

Groups			Significance
6% lactic acid cream	I	II	.004
	I	III	.442
	I	Lactic acid peel	.458
6% glycolic acid cream	II	I	.004
	II	III	.026
	II	Lactic acid peel	.036
12% glycolic acid cream	III	I	.442
	III	II	.026
	III	Lactic acid peel	.987
Lactic acid peel Full strength	I		.458
	II		.036
	III		.987

DISCUSSION:

Melasma is a major cosmetic problem especially among dark skin women⁽¹⁾, affecting almost 30% of Iraqi females in their reproductive age⁽²⁾. There are many modalities of treatment especially bleaching agents like hydroquinone but unfortunately the relapse rate is usually high after therapy. The present work showed that (6%) lactic acid cream is an effective agent and the improvement was 54% in treatment of patients with melasma assessed by objective methods of clinical evaluation using MASI scoring. More over glycolic acid has not been used as pure agent but it has been combined with hydroquinone to enhance its effectiveness in treatment of melasma

⁽¹⁴⁾, but the present work showed that 6% glycolic acid cream has mild effect and the improvement was only 21%, although using 12% glycolic acid cream had been shown to be effective agent in treatment of melasma and the improvement was 52%. So the present work demonstrated that 6% lactic acid cream was as effective as 12% glycolic acid cream and also as effective as full concentration lactic acid peel that seen in pervious Iraqi study⁽¹¹⁾Table (1),(2). so both lactic acid and glycolic acid are effective agents in treatment of melasma with almost similar side effect mainly irritation. The mechanism of lactic acid might be similar to glycolic acid by epidermal remodeling

and accelerated desquamation which would result in quick pigment dispersion. Recent invitro study in Japan showed direct inhibitory effect of lactic acid and glycolic acid on tyrosinase enzyme activity this will inhibit melanin formation in melanocytes. ⁽¹⁵⁾. To over come the irritancy of 12% glycolic acid and 6% lactic acid creams we advised all recruited patients to use the cream on alternate day to overcome this side effect then used once daily at night for two months with SPF =30 before sun exposure and continue till the end of follow up. In conclusion, Lactic acid cream 6% is a new, non costly, alternative effective, safe agent and as effective as 12% glycolic acid cream.

REFERENCES:

1. Bleehen SS, Ebling FJG, Champion RH. Disorders of skin colour. In: Champion RH, Burton JL, Ebling FJG (eds). Textbook of Dermatology, 8th ed. Black Well Scientific Publications, Oxford, 2010;58:34.
2. Sharquie KE and Dhahir SA. Melasma in Iraqi women; A Clinical and Histopathological and Histochemical study. J Pan- Arab League Dermatologists 2000; 3: 111-17.
3. Jaishree Sharad. glycolic acid peel therapy-current review. Clinical, cosmetic, and investigational dermatologic.2013;6:281-88.
4. Slavin JW.Consideration in α hydroxyl acid peels.Clinics in Plastic Surgery 1998;25:45-52.
5. Van-Scott E and Yu R. Hyperkeratinization, corneocyte cohesion and alpha-hydroxy acid. J Am Acad Dermatol 1984; 5: 867-79.
6. Wehr R, Krochmal L, Bagatelle F and Ragsdale W.A controlled two-center study of lactate 12% lotion and a petrolatum-based cream in patients with xerosis . *Cutis* 1986; 37:205-7.
7. Sharquie KE & Abdulah MS. Treatment of vitiligo with topical 15% lactic acid solution in combination with ultraviolet-A. Saudi Med J. 2005; 26:1013-14.
8. Rendle M, Myer C, Weninger W and Tschachler E. Topically applied lactic acid increases spontaneous secretion of vascular endothelial growth factor by human reconstructed epidermis. Br J Dermatol 2001; 145:3-9.
9. Smith WP. Epidermal and dermal effects of topical lactic acid. *J Am Acad Dermatol* 1996;35: 388-91.
10. Van-Scott E and Yu R. Alpha-hydroxy acids: Procedures for use in clinical practice. *Cutis* 1989;43: 222-28.
11. Sharquie KE, AL-Tikreety MM and AL-Mashhaddani SA. Lactic acid as a new therapeutic peeling agent in melasma. *Dermatol surg* 2005; 31:1- 6.
12. Kimbrough-Green Ck, Griffiths CEM and Finkel LJ. Topical retinoic acid (tretinoin) for melasma in black patients. *Arch Dermatol* 1994; 130: 727-33.
13. Nie NH, Hadin Hull C and Jenkins JG. SPSS "Statistical package for social sciences" New York, Mc Grow Hill. 2013:41-42.
14. WK Chowdhury, MA Wahab, L Khondker, MSI Khan, IK Shirajul.efficacy and safety of hydroquinone,Kojic acid and glycolic acid combination in the treatment of melasma.Bangladesh journal of medical science.2012;11:3.
15. E.B.Handog and Ma.J.E.Macarayo. Color Atlas of Chemical Peels.2nd ed .springer-Herlag, Head of Dermatology & Venereology Berlin, Heidelberg, 2012; 15:130.

