

Use of Fine Needle Aspiration Biopsy in Diagnosis Oral and Maxillo-Facial Tumors

Emad H. Abdulla BDS, MSc.⁽¹⁾

Khalid Y. Igzeer BDS, MSc.FD.D.R.C.S.I⁽²⁾

Key words

fine needle aspiration, oral tumors, maxillo-facial tumors.

Abstract

The Technique of fine needle aspiration biopsy (F.N.A.B.) was evaluated in the field of maxillofacial surgery. For this purpose comparison of cytological results with the conventional histopathological results were taken place. Seventy-two specimens were obtained by F.N.A.B. from 60 patients with age range from 3-84 years of both sexes, 11.7% of the patients had previous history of diagnosed malignant tumors. Cytological results show 40 cases (55.5%) were benign tumor, 27 cases (37.5 %) were malignant, 3 cases (4.2 %) unsatisfactory for diagnosis and 2 cases (2.8 %) were suspicious to be malignant. The statistical analysis showed that F.N.A.B. had sensitivity (92.6%), specificity (100%), positive predictive value (92.3%), and accuracy rate (96%).

Introduction

Fine needle aspiration biopsy is a method by which cells or tissues are obtained for microscopically study using small gauge needle⁽¹⁾. It is a technique-gained popularity and wide acceptance in many medical fields and surgical specialties⁽²⁾. F.N.A.B. has demonstrated to be reliable for the diagnosis of tumors in the head and neck^(3,4,5,6,7,8). However the accuracy of F.N.A.B. in the oral and maxillofacial region has not specifically addressed⁽⁷⁾. In 1930 Martin, Ellis and Stewart introduced in oral and maxillo-facial region this technique for the first time⁽⁹⁾. The aim of the study to clarify the role of F.N.A.B. in the field of oral and maxillo-facial surgery and assess its accuracy and role in planning therapy in oral and maxillofacial surgery.

Materials and Methods

The study sample includes (60) patients with clinically significant oral and maxillo-facial masses. All the patients were examined using the F.N.A.B. between May 1995 till the end of February 1996. The F.N.A.B. were performed at the department of oral and maxillo-facial surgery college of dentistry, university of Baghdad, and in the consultation clinic of oral and maxillo-facial surgery of Baghdad medical city hospital. The patients ranging in age from 3-84 years old. Two separate F.N.A.B. were obtained from only 12 patients, from the 60 patients 17 people (28.3%) were below the age of 18 years this group contains 13 boys and 4 girls. Only seven patients (11.7%) from total sample have previous history of malignancies. The sex incidence in this study consisted of 34 males (56.7%) and 26 females (43.3%). The sample included patients presented with an abnormal mass, palpable or visible, suspicious to be malignant in the oral cavity and maxillofacial region (including the salivary glands and excluding thyroid

(1) Lecturer, Department of Oral Surgery, College of Dentistry, University of Tikrit.

(2) Ass. Prof, Department of Oral Surgery, College of Dentistry, University of Baghdad..

gland) Table (1), patients with previous treatment from malignant growths who return with a new masses during follow up examination and patients with masses of long duration with no response to dental and medical treatment. The procedure performed in an outpatient clinic, local or topical anesthesia were not administrated, disinfected solutions were used for extra oral masses but not applied for intra oral masses, F.N.A.B. were taken with a standard disposable needle of (21-23) gauge attached to 10 ml disposable plastic syringe. The needle attached to the syringe, and air aspirated to the mark of 2ml, the lesion grasped firmly with left hand or pinned in position between the thumb and the index finger and held in position. The needle inserted directly with a single quick motion and advanced into the mass once the needle was in the mass negative pressures created in the syringe by retraction of its plunger. While constantly maintaining the negative pressure in the syringe barrel, and with the needle was still within the mass, several sharp quick strokes indifferent directions were done to mass in different areas, prior to removal of syringe suction on the plunger was released .After the drawl of the needle from the skin or the mass slight pressure was applied to the puncture site to stop pinpoint bleeding and prevent hematoma Formation. To prepare smears, the specimen were expressed onto glass slide by using the volume of (2..c.c) of air left in the syringe, a second slide was dipped, in fixer solution (95 % ethanol solution) and this wetted glass was used to spread the aspiration in the same manner used in preparation of blood smears, the slides immediately immersed in the fixer solution present in the container. The slides put in 95% ethanol solution for 30 minutes and stained by or according to modified papanicolaou staining method. Measuring of the needle depth in the mass done by using sterilize rubber piece inserted by the needle and the distance between the tip of the needle and the rubber stopper measured as needle depth. The histopathological diagnosis done for the specimens removed by surgical biopsy and prepared in the usual manner. The four fold contingency tables and pooled

student t test were used to evaluate the results. An ultra sound, seamen's, soulin SLI machine used to guide F.N.A.B. for one mass in the study. (Fig 3).

Results

A diagnosis was made by cytological examination of the aspirated material taken by F.N.A.B. from various lesions in the oral cavity and maxillofacial region. Seventy-two F.N.A.B. were performed from 60 patients. Table (1) shown the anatomical distribution of tumor lesions according to site and location which subjected to F.N.A.B. From the total sample, 55 F.N.A.B. (76.39%) were possible to compare their cytological results by means of a histological diagnosis, the remaining 17 F.N.A.B.(23.7%) had no histological examination from those 17,11aspiration (15.2%) had clinical follow-up examination, and for other6 F.N.A.B. (98.33%) the patients had not returned back for further investigations Table (4).

A-Forty cases (55.5%) from the total sample were reported as benign and inflammatory conditions, as shown in table (4). From these surgical biopsy was available for only 26 cases (65, %), the remaining was (14) cases (35%).Nine cases (25.5%) be under medication and follow-up examination while other 5 cases (12.5%) the patients were not seen again for another investigation. The cases associated with surgical biopsy the histopathological examination revealed that (24) cases (88.9 %) were Benign and the other two cases (7.1%) were malignant.

B-The other twenty seven cases (37.5 %) diagnosed cytological as malignant lesions, surgical biopsy were available for only 25 cases the histopathological diagnosis was agreed with the cytological results ,table (2).The others two cases the lesions were advanced that the cytological and other clinical

investigations were dependent as a final diagnosis.

C-The three unsatisfactory cases for diagnosis (4.25%) have inadequate aspirated material for examination, surgical biopsy was available for two cases, which proved to be benign tumor by histopathological diagnosis, and the other condition was lost to follow-up.

D-Two cases (2.8%) were diagnosed cytologically as suspicious to be malignant and one mass was malignant and the other one was benign tumor proved by histopathological and cytological examination. In addition to the main group of tumor, the results of F.N.A.B. were analyzed and recorded in four subgroups in addition to the main group of tumor according to site location Table (1), include group of patients below the age of 18 years, table (5&6), group of malignancy history and results in tumors of lymph nodes, and salivary gland masses, fig(1).

The results of needle depth measurements in relation to type of cytological diagnosis were assessed in forty cases no relation significantly was noticed between needle depths and study result. In one case the F.N.A.B. examination was done guided by ultrasonography. Analysis of clinical data in this study, sensitivity of the F.N.A.B. test ((percentage of person with the disease who are positive to the test)) was (92.6%) the specificity ((percentage of persons with none diseased persons who are negative to the test)) was (100%) and the accuracy rate to be (96%) predictive value of a positive test =percentage of persons with a positive test who have the disease. (100%) predictive value of a negative= percentage of persons with a negative test who do not have the disease (92.3%), (fig2).

Discussion

Although the diagnosis of many lesions could be made clinically by experienced surgeons, such diagnosis is considered provisional one unless confirmed by biopsy examination. The various

investigations used for diagnosis of malignant, benign and inflammatory lesions are expensive, time consuming and it may require hospitalization and surgical interference, this is especially important in suggested malignant lesions where any delay in their diagnosis and treatment will greatly affect the prognosis of condition. Many researchers have found complete predictive value of F.N.A.B. results in diagnosis of oral cavity, oropharynx and nasopharynx masses, many authorities were found that this method very helpful to the clinician to overcome many problems in clinical management of their patients^(3,6,9). Especially those complaining of limitation in mouth opening caused by oral masses. The results of this study was similar to the other studies in the field of oral and maxilla-facial region^(10,11,12,13,14). In addition this method also permits the surgeon to examine more than one mass in the same time especially lymph node and intra-osseous masses with decreasing the risk of multiple surgeries⁽¹⁵⁾.

Conclusions

1-F.N.A.B. is simple, safe, rapid and cost-effective procedure and it was a helpful major procedure for diagnosis of masses.

2-It could differentiate between malignant, benign and inflammatory masses of oral and maxillo-facial regions.

3-F.N.A.B. is safe and practical procedure in management of children, young adults and gives a great aid in management of patients with recurrent malignancy or secondary metastases tumors and F.N.A.B. is useful in diagnosis of intra-osseous, salivary gland, and lump node tumors.

4-There is a need for an oral cytologist who has interest and experience in examination and diagnosis of F.N.A.B.s.

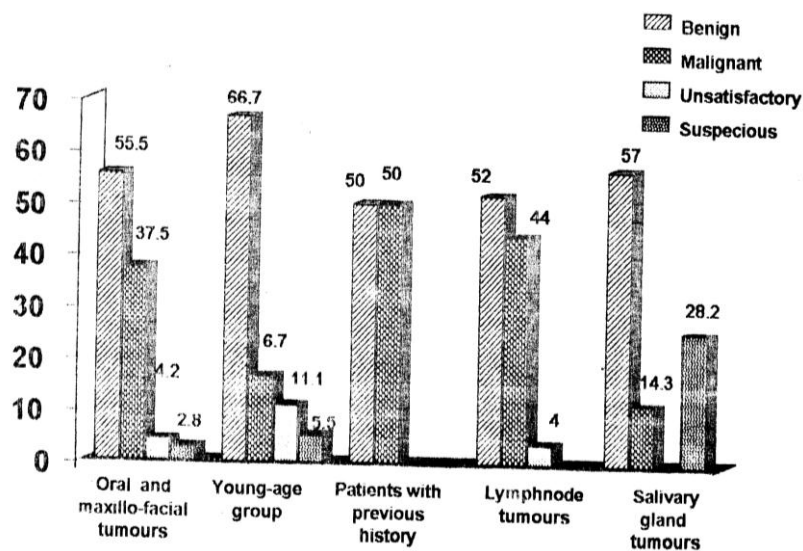


Fig.(1):- Histogram showing the fine needle aspiration biopsy cytological results.

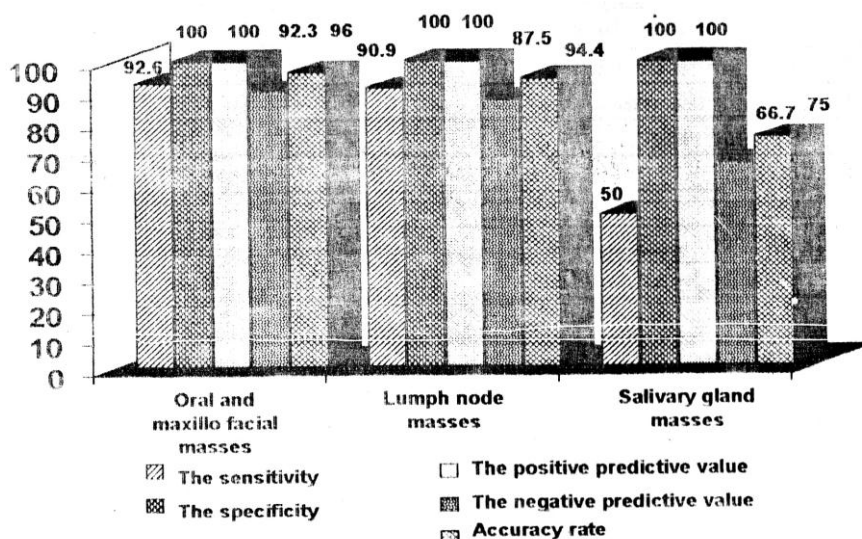


Fig.(2):- Histogram showing the statistical analysis of fine needle aspiration biopsy results compared with histopathological results.

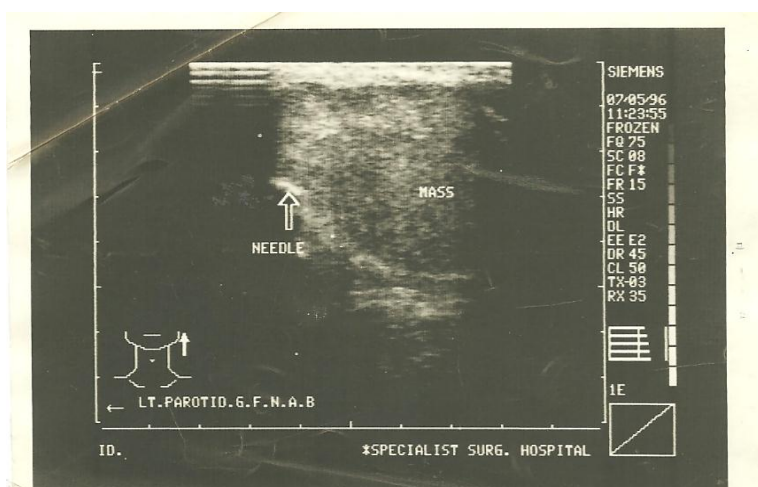


Fig. (3):- Photo from ultras sound system showing needle penetrated parotid mass guided by the ultra sound examiner to make F.N.A.B in the study.

Table (1):-The anatomical distribution of F.N.A.Bs.

Location of Mass	No. of Cases	Percentages (%)
Submandibular area	21	29.2 %
Submental area	8	11.1 %
Alveolar ridge	8	11.1 %
Check	7	9.7 %
Maxilla	7	9.7 %
Mandible	6	8.3 %
Parotid gland	6	8.3 %
Tongue	5	6.9 %
Palate	2	2.8 %
Submandibular salivary gland	1	1.4 %
Lip	1	1.4 %
Total	72	100 %

Table (2):-The distribution of histopathological diagnosis of malignant tumours examined by F.N.A.Bs.

Diagnosis	No.	Percentages (%)
Squamous cell carcinoma	18	64.3 %
Mucoepidermoid carcinoma	4	14.3 %
Lymphoma	3	10.7 %
Malignant melanoma	2	7.1 %
Adenocystic carcinoma	1	3.6 %
Total	28	100 %

Table (3):-The findings of histopathological diagnosis of benign tumors examined by F.N.A.Bs.

Diagnosis	No.	Percentages (%)
Reactive lymph node	7	25.9 %
Cyst	5	18.5 %
Pyogenic granuloma	4	14.8 %
Ameloblastoma	3	11.11 %
Haemangioma	2	7.4 %
Benign salivary gland	2	7.4 %
Neurofibroma	1	3.7 %
Sebaceous cyst	1	3.7 %
Eosinophilic granuloma	1	3.7 %
Xeroderma pigmentosa	1	3.7 %
Total	27	100 %

Table (4):-The cytological diagnosis of (72) F.N.A.Bs. of oral and maxilla facial tumors.

F.N.A.B results	No.	No. with surgical biopsy	No. with follow up	No. of cases lost to be followed
Benign and inflammatory	40(55.5 %)	26	9	5
Malignant	27(37.5 %)	25	2	-----
Unsatisfactory for diagnosis	3(4.2 %)	2	-----	1
Suspicious to be malignant	2(2.8 %)	2	-----	-----
Total	72	55(76.3 %)	11(15.3 %)	6(8.3 %)

Table (5):-The results of F.N.A.Bs in patients below 18 years of age.

F.N.A.B results	No. %	No. of cases with surgical biopsy	No. of cases with follow up	No. of cases lost to be followed
Benign and inflammatory	12(66.7 %)	7	4	1
Malignant	3(16.7 %)	1	2	-----
Unsatisfactory for diagnosis	2(11.1 %)	1	1	1
Suspicious for malignancy	1(5.5 %)	1	-----	-----
Total	18	10	7	2

Table (6):-The histopathological results of patients below 18 years of age.

F.N.A.B results	No. of cases with surgical biopsy	Benign histopathological diagnosis	Malignant histopathological diagnosis
Benign and inflammatory	7	7	-----
Malignant	1	-----	1
Unsatisfactory for diagnosis	1	1	-----
Suspicious to be malignancy	1	1	-----
Total	10	9	1

References

- 1-Schultenover,S.J.,Ramzy,I., Page, C.P., Leferbre, S.M., and Cruz,A.B..Needle aspiration;role and limitations in surgical decision making. Am. J.clin. pathol; 1984;82;405-410.
- 2-Shah, J.P., colour atlas of operative techniques in head and neck surgery, face,skull and neck-Wolfe Medical publications LTD. Ipswich, England 1987.
- 3-BarnardN.A.,PatersonA.W.,Irvine G.H.,Mackenzie E.D., aspiration cytology in maxilla-facial surgery experience in adistrict general hospital: Br.J. White H. Fine-needle oral and maxilla-facial surgery1993; 31(40):223-6 (Abst.cited by medline).
- 4-Cannon-C.R Fine aspiration (F.N.A.) of parotid masses , J.miss-state.med.Assoc.Jul. 1994;35;7; 191-5,(Abst.cited by medline).
- 5-Comeche-C.,Barona.,Navarro.T., Armengot.m., Basterra J Verifiable diagnosis of the puncture of the fine needl easpiration,.In the head and neck neoplasms;Acta-Oto- rrinolarigol.-Esp1993;44(5) 381-4 (Abst-cited by medline).
- 6-DAas.DK,Gulati A,Bhatt N.C., Mandol A.K.,Khan V.A., Bhambhani S Fine needle aspiration cytology of oral and pharyngeal lesions; A study of 45 cases ;Acta cytol 1993;37,(30) 333-42.(Abst.cited by medline
- 7-kaur A .,Chew C.T.,lim-Tan-SK, Fine needle aspiration of the 123 heaed and neck masses an intial experience.Ann -Actad -Med.singapore 1993; 22,(3);303-306 ((Abst cited by med Line)).
- 8-Young J.E.H.,Archibald, S.D.,Dand Schier, K.J Needle aspiration cytological biopsy in head and neck masses. AM.J.Surg 1981; 142; 484-489.
- 9- Martin H.E.,, and Ellis E.G biopsy by needle puncture and aspiration; Annals of surgery 1930;92 ;169-181.
- 10-Mehrotra R, Gupta A, Singh M and Ibrahim R Application of cytology and molecular biology in diagnosing premalignant or malignant oral lesions. Molecular Cancer 2006; 5:11
- 11-Platt,J.C.,Rogers,S.F.,,Davidson,D.,and Nelson .,C.L Fine needle aspiration biopsy in oral and maxillofacial surgery; Oral surg.Oral med.Oral pathol 1993;75(2)152-155.
- 12-Platt.,j.c.,Davidson.,D.,,Nelson.,C.L.,andWeisberger,E fine needle aspiration biopsy: An analysis of 89 head and neck cases.J.Oral maxillo-facial surge 1990;84(7);702-706
- 13-Roland,N.J.,Caslin,A.W.,Smith,P.A.,Turnbull,L. S.,Panarese,A.,Jones,A.S Fine needle aspiration cytology of the salivary gland lesions reported immediately in a head and neck clinic.J. Laryngol.otol1993;107(11);1025-8 (Abstract cited by medline).
- 14-Sunita Singh,Natasha Garg, Sumiti Gupta, Nish Marwah, Rajneesh Kalara ,Virender Singh ,Rajee Vsense Fine needle Aspiration cytology in lesions of oral and maxillofacial region ;Diagnostic pitfalls 2011.
- 15-Zurrida,S.,Alasio,L.,Tradati,N.,Bartoli,C.,Chiesa, F.,and Pillotis,S Fine needle aspiration of parotid masses.Cancer 1993;72 :2306-2311.