

Uterine Arterial Embolization for Treatment of Uterine Leiomyoma: Initial Experience with 1-Year Follow-up

Dear Editor,

Arterial embolization has been used during the last three decades as a method of treating gynecological hemorrhage in a variety of clinical situations; the procedure is now widely accepted option for the treatment of symptomatic fibroids and has been recognized as such by the National Institute for Health and Care Excellence in its guidelines for heavy menstrual bleeding.^[1]

Uterine fibroids are the most common benign pelvic tumor in female, occurring in up to 50% of women in some ethnic groups (the incidence is greatest among women of African descent), but most remain asymptomatic.

Uterine fibroids are supplied by uterine arteries. Origin of uterine arteries is variable,^[2] classified into Type I 45% (the uterine artery as first branch of the inferior gluteal artery), Type II 6% (the uterine artery as second or third branch of the inferior gluteal artery), Type III 43% (the uterine, the inferior gluteal, and the superior gluteal arteries arising as a trifurcation), and Type IV 6% (the uterine artery as first branch of the hypogastric artery). In <1%, the uterine artery may arise from the ovarian artery.

The many advantages of uterine arterial embolization (UAE) are significant symptom improvement, uterus preserving procedure, rapid postprocedure recovery, and lower cost giving high overall patient satisfaction rate. Many indications and contraindications should be evaluated.^[3]

To the best of my knowledge, this is the first cross-sectional study in Iraq which deals with the effect of UAE as a treatment of uterine fibroids and it is our first experience of UAE and the first reported patient series in Iraq.

From April 2016 to April 2017, 91 women (37.06 ± 5.51 , range 25–48 years) with symptomatic fibroids were included in the study; informed consent was taken from each patient, with approval from the institutional committee. Contact with referring gynecologist was done for most of the patients. Patients with fibroid and any contraindications were excluded from the procedure. Magnetic resonance imaging (MRI, 1.5 Tesla, Achieva Philips Medical) and ultrasonography (IU22/PHILIPS medical systems) studies were done for each patient before the procedure for size (volume), position, and number of uterine fibroids with enhancement patterns and associated uterine conditions.

Dominant fibroid volume (mean, range) and symptoms were evaluated, including menstrual abnormality (menorrhagia, dysmenorrhea) and pressure symptoms (heaviness sensation, urinary frequency, uterine prolapse, and hydronephroses).

The study was performed on angiographic system (PHILIPS ALLURA bi-plain medical systems). Catheterization was done in all 91 (100%) patients from the right (Rt.) common femoral artery. This technique was reported by Pelage *et al.*^[4] Cobra shape 5F angiographic catheter was used in all cases (Cordis Medical), with microcatheter used in only two patients. Catheterization of both Rt. and Lt. uterine arteries was done from Rt.-sided approach with catheterization of Rt. uterine artery done by Waltman loop formation. Vasospasm was seen in Rt. uterine artery in two patients (3.3%) and in Lt. uterine artery in four patients (4.4%), necessitating the use of vasodilator with or without microcatheter. The tip of Cobra catheter was at the distal part of transverse segment of uterine artery. Polyvinyl alcohol particles (355 μ m–500 μ m) were used in all patients (Bearing nsPVA, MERIT MEDICAL), and then gel foam sponge was slowly injected under fluoroscopic control. Degree of optimum embolization is when reflux of embolization materials or disappearance of distal branches. Procedures were done under conscious sedation, and tramadol 50 mg intramuscular with 50 mg intravenous infusion was used. Intravenous infusion of single dose of metronidazole 500 mg, with intravenous infusion 1 g ceftriaxone, was given. About six hours post procedure stay in hospital, all patients discharged in the same day. Patients continue on oral metronidazole and ciprofloxacin for 7–10 days with analgesia as required.

Ultrasound (US) follow-up at 1, 3, 6, 9, and 12 months was performed in all patients, with MRI done at 12 months for final evaluation. Symptomatic evaluation for improvement or resolution of symptoms was also done at 1, 3, 6, and 12 months.

Bilateral UAE was done for all 91 women, with access from Rt. CFA, with only two patients (2.2%) requiring bilateral CFA access. No intraoperative complications were seen (extravasation, dissection, pseudoaneurysm formation, and nontarget embolization). No major complications were seen at 1 year. Postoperative pain seen in 41 patients (42.9%) which was mild pelvic pain improved gradually during few days with mild analgesics. Postoperative fever seen in 19 patient (20.9%) which is low grade lasted for <3 days.

Fibroid volume evaluation was performed by US ($L \times W \times H/0.5$), with same time symptom evaluation. Sixty patients (65.9%) present with pressure effect, 66 patients (72.5%) present with menstrual abnormality only, and 35 patients (38.5%) present with both bleeding and pressure symptoms.

At 1 month, symptom improvement was seen in 17 (18.7%) patients.

At 3 months, symptom improvement was seen in 53 (58.2%) patients, with average size reduction evaluated by US being 19.5%. At 6 months, symptom improvement was seen in 65 (71.4%) patients, with average size reduction by 48.9%. At 9 months, volume reduction was about by 58.9%.

At 1 year, symptom improvement was seen in 74 (81.3%) patients, with average size reduction by 76.5%, with significant *P* value. Table 1 shows distribution patients with uterine fibroid according to clinical manifestation including bleeding, pressure effect, fever, and discharge [Figure 1].

Table 1: Distribution of patients with uterine fibroid according to clinical manifestation

Clinical manifestation	n (%)
Pressure effect	
Present	60 (65.9)
Absent	31 (34.1)
Total	91 (100.0)
Bleeding	
Present	66 (72.5)
Absent	25 (27.5)
Total	91 (100.0)
Fever	
Present	19 (20.9)
Absent	72 (79.1)
Total	91 (100.0)

Table 2: Mean differences of uterine fibroid size during 12 months of follow-up

Study variable	Study group	n	Mean±SD	Paired t-test	P
Size (cm ³)	Preoperative	91	294.73±167.56	14.169	<0.001*
	3 months postoperative	91	237.52±140.58		
	Preoperative	91	294.73±167.56	14.644	<0.001*
	6 months postoperative	91	150.5±92.24		
	Preoperative	91	294.73±167.56	14.806	<0.001*
	9 months postoperative	91	121.12±76.81		
	Preoperative	91	294.73±167.56	15.823	<0.001*
	12 months postoperative	91	69.16±43.05		

**P*≤0.05 was significant. SD: Standard deviation

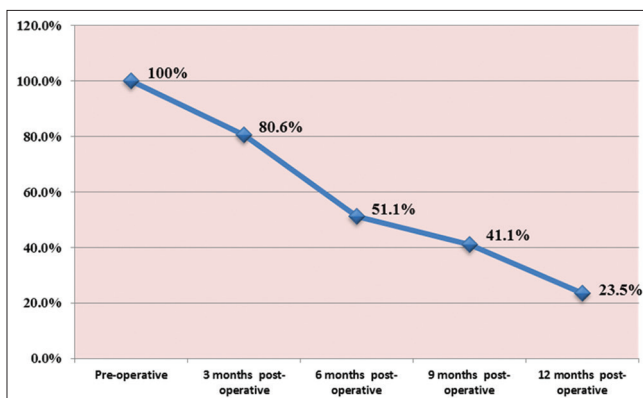


Figure 1: Uterine size reduction during 12 months of follow-up

In this study, 91 women had undergone UAE; almost all have significant improvement in their symptoms related to fibroid with high satisfaction and low complication rates.

Menstrual bleeding abnormality and pressure symptoms with tendency to preserve the uterus were the major indications in those women; significant gradual improvement in these symptoms was noted at 1, 3, 6, and 12 months with 81.3% becoming symptom-free at the end of 1 year, whereas the others showed significant improvement [Table 2]. This result was compatible with the results by other trials by Spies *et al.*^[5]

Subjective improvement was seen in most women 83% with recommendation to other women being very great which is similar to many trials.^[6] Size reduction of uterine fibroids were gradual and progressive, Mean size reduction was 19.5% at the end of 3 months after UFE which is compatible to a study by Brunereau *et al.*^[7] but less than that reported by other studies like Worthington-Kirsch *et al.*^[8] Possibly it is related to degree of initial embolization since in this study the ischemia is gradual & progressive rather than sudden (mostly related to particle size used in embolization).

Mean size reduction at 6, 9, and 12 months was 48.9%, 58.9%, and 76.5% respectively, which is compatible with a study by Laios *et al.*^[9] Single catheter and single femoral puncture were used in all patients making the procedure low cost. Local anesthesia and conscious sedation were used in all patients.

The procedure of UAE is proved to be effective, safe, low cost with very low adverse effects of complications and high success rate when done by an experienced interventional radiologist, with >85% of treated women being recommended the procedure to a friend or family member. The study recommends a longer follow-up to the patients to know the long-term outcome.

Financial support and sponsorship

Nil.

Conflicts of interest

There are no conflicts of interest.

Zaid Hadi Hammoodi

Shaheed Al-Mihrab Center of Cardiac Surgery and Catheterization, Babil Health Directorate, Al Hilla, Iraq

Address for correspondence: Dr. Zaid Hadi Hammoodi, Shaheed Al-Mihrab Center of Cardiac Surgery and Catheterization, Babil Health Directorate, Al Hilla, Iraq. E-mail: zaid_hadi06@yahoo.com

REFERENCES

1. National Institute for Health and Care Excellence (NICE). Clinical Recommendations on use of Uterine Artery Embolization in the Management of Fibroids, 3rd edition, National Institute for Health and Clinical Excellence. Heavy Menstrual Bleeding. NICE Clinical Guideline (CG44) London. NICE.2007. Available from: <http://www.guidancencice.org.uk/G44/guidance/pdf/>. [Last accessed on 2013 Oct 25].
2. Gomez-Jorge J, Keyoung A, Levy EB, Spies JB. Uterine artery anatomy relevant to uterine leiomyomata embolization. Cardiovasc Intervent Radiol 2003;26:522-7.

Letter to Editor

3. Jefferies A, Akande V. Modern management of fibroids. *Obstet Gynecol Reprod Med* 2016; 26:127-32.
4. Pelage JP, Soyer P, Le Dref O, Dahan H, Coumbaras J, Kardache M, *et al.* Uterine arteries: Bilateral catheterization with a single femoral approach and a single 5-F catheter – Technical note. *Radiology* 1999;210:573-5.
5. Spies JB, Cooper JM, Worthington-Kirsch R, Lipman JC, Mills BB, Benenati JF, *et al.* Outcome of uterine embolization and hysterectomy for leiomyomas: Results of a multicenter study. *Am J Obstet Gynecol* 2004;191:22-31.
6. Pron G, Bennett J, Common A, Wall J, Asch M, Sniderman K, *et al.* The Ontario uterine fibroid embolization trial. Part 2. Uterine fibroid reduction and symptom relief after uterine artery embolization for fibroids. *Fertil Steril* 2003;79:120-7.
7. Brunereau L, Herbreteau D, Gallas S, Cottier JP, Lebrun JL, Tranquart F, *et al.* Uterine artery embolization in the primary treatment of uterine leiomyomas: Technical features and prospective follow-up with clinical and sonographic examinations in 58 patients. *AJR Am J Roentgenol* 2000;175:1267-72.
8. Worthington-Kirsch RL, Popky GL, Hutchins FL Jr. Uterine arterial embolization for the management of leiomyomas: Quality-of-life assessment and clinical response. *Radiology* 1998;208:625-9.
9. Laios A, Baharuddin N, Iliou K, Gubara E, O'Sullivan G. Uterine artery

embolization for treatment of symptomatic fibroids; A single institution experience. *Hippokratia* 2014;18:258-61.

This is an open access journal, and articles are distributed under the terms of the Creative Commons Attribution-NonCommercial-ShareAlike 4.0 License, which allows others to remix, tweak, and build upon the work non-commercially, as long as appropriate credit is given and the new creations are licensed under the identical terms.

Access this article online	
Quick Response Code: 	Website: www.medjbabylon.org
	DOI: 10.4103/MJBL.MJBL_19_18

How to cite this article: Hammoodi ZH. Uterine arterial embolization for treatment of uterine leiomyoma: Initial experience with 1-Year Follow-up. *Med J Babylon* 2018;15:104-6.

© 2018 Medical Journal of Babylon | Published by Wolters Kluwer - Medknow

