



ISSN: 0067-2904

Sperms Abnormalities and Testicular Damage Induced by cyclosporine A Drug and the Protective Effect of Garlic in Male Albino Rats

Shaimaa Mohammed Ali Jasim*¹, Zaid Makki Mohammed², Alaa Shakir AL-Nahi¹

¹Department of Biology, Faculty of science, University of Kufa, Kufa Iraq

²Department of Ecology Faculty of science, University of Kufa, Kufa Iraq

Received: 4/6/2022

Accepted: 28/10/2022

Published: 30/9/2023

Abstract:

The objective of present study is to identify the adverse effects of cyclosporine A drug and the protective role of garlic in cytotoxicity test, including sperms deformation and histological changes in testes tissues of male albino rats. The study recorded significant increase $p \geq 0.05$ in sperms head and tail deformation rates in groups that were administrated cyclosporine and cyclosporine + garlic for two weeks compared with control groups which were administrated olive oil and garlic. The study reported significant decrease $p \geq 0.05$ in sperms head and tail deformation rates in the group that was administrated cyclosporine + garlic compared with group that was administrated cyclosporine only. In addition, the study also indicated histological changes in testes tissues including degenerative changes represented by depletion of the spermatogonial cells (some seminiferous tubules appeared with one or two layers of spermatogonia) in the group that was administrated cyclosporine compared with the control group which was administrated olive oil. The study reported slight histological changes in testes tissues from normal testes architecture, somniferous tubules with maturation of spermatogony and sperms inside the lumen in group that was administrated cyclosporine + garlic for two weeks compared with the control group which was administrated olive oil and garlic. Finally, the findings showed reduction in histological changes of testes tissues in group which was administrated cyclosporine + garlic for two weeks compared with group which was administrated cyclosporine only.

Keywords: Cyclosporine A; Garlic; Testicular damage; Sperm abnormalities

تشوهات الحيوانات المنوية وتلف الخصى الناجم عن عقار السيكلوسبورين أ والتأثير الوقائي للثوم في ذكور الجرذان البيض

شيماء محمد علي جاسم¹ *، زيد مكي محمد² *، إلاء شاكِر الناهي¹

¹قسم علوم الحياة، كلية العلوم، جامعة الكوفة، النجف، العراق

²قسم البيئة والتلوث، كلية العلوم، جامعة الكوفة، النجف، العراق

الخلاصة:

الهدف من الدراسة الحالية هو التعرف على التأثير الضار لعقار السيكلوسبورين والدور الوقائي للثوم في اختبار السمية الخلوية الذي تضمن تشوه الحيوانات المنوية والتغيرات النسيجية في أنسجة الخصى لدى ذكور الجرذان البيض. سجلت الدراسة زيادة معنوية $p \leq 0.05$ في معدل تشوه الرأس والذيل في المجموعات التي

*Email: shimaam.jasim@uokufa.edu.iq

تناولت السيكلوسبورين والسيكلوسبورين والثوم لمدة أسبوعين مقارنة بمجاميع السيطرة التي تناولت زيت الزيتون والثوم. فضلا عن ذلك ، أشارت الدراسة إلى انخفاض معنوي $p \leq 0.05$ في معدل تشوه الرأس والذيل في المجموعة التي تناولت السيكلوسبورين والثوم مقارنة مع المجموعة التي تناولت السيكلوسبورين فقط. فضلا عن ذلك ، أشارت الدراسة إلى تغيرات نسيجية في أنسجة الخصى تضمنت تغيرات تنكسية تتمثل في نضوب خلايا الحيوانات المنوية (ظهرت بعض الأنابيب المنوية مع طبقة أو طبقتين من الحيوانات المنوية) في المجموعة التي تناولت السيكلوسبورين مقارنة بمجموعة السيطرة التي تم إعطاؤها زيت الزيتون. أشارت الدراسة إلى حدوث تغيرات طفيفة في أنسجة الخصص بنية الخصى الطبيعية ، الأنابيب المنوية مع نضوج الحيوانات المنوية داخل التجويف في المجموعة التي تم اعطاؤها السيكلوسبورين و الثوم لمدة أسبوعين مقارنة بمجاميع السيطرة التي تم إعطاؤها زيت الزيتون والثوم. أظهرت النتائج انخفاضًا في التغيرات النسيجية لنسيج الخصى في المجموعة التي تناولت السيكلوسبورين و الثوم لمدة أسبوعين مقارنة بمجموعة التي تم اعطاؤها السيكلوسبورين فقط.

Introduction:

Cyclosporine A is a cyclic polypeptide drug with strong immunosuppressive potency [1]. Cyclosporine has been widely used in transplantation and preventing organ rejection, as well as in treating autoimmune diseases [1-2].

Cyclosporine is an immunosuppressant drug that is cyclic non-polar oligopeptide composed of 11 amino acid residues which are isolated from the insect-pathogenic fungus *Tolypocladium inflatum* [3].

Due to its high toxicity, Cyclosporine A administration can be accompanied by many adverse side effects such as the nephrotoxic, hepatotoxic, neurotoxic and testicular toxicity [1-4]. cyclosporine toxicity on fertility and other side effects limit its clinical use [1-5].

Garlic (*Allium sativum L.*) is a medicinal plant that has also been used for human healthcare and as spices, and plays an important role in improving the immune system against diseases in humans [6]. Garlic contains diverse bioactive compounds, such as allicin, alliin, diallyl sulfide, diallyl disulfide, diallyl trisulfide, ajoene and S-allyl-cysteine [7].

The active constituents of garlic have biological functions as antioxidant, anti-inflammatory, immuno-modulatory, anticancer, hepatoprotective, digestive system protective, anti-diabetic, anti-obesity, neuroprotective, renal protective and have wound healing properties [6-8].

Spermatogenesis is a complex process of germ cell proliferation and differentiation. Large number of factors affect the process of spermatogenesis, including pathological changes of the seminiferous epithelium, aberrant gene expression and environmental factors. Pathological changes of the seminiferous epithelium may cause the disruption of sertoli and germ cells which result in impaired spermatogenesis and may also lead to germ cell loss [9].

The aim of this study was to investigate the possible protective effects of garlic in improving cytotoxicity in sperm cells and preventing testicular injury caused by administration of cyclosporine drug through the sperm deformation and histological study of changes in the testes of male albino rats.

Materials and Methods

The study was conducted for the period from October to January 2021. All animal experiments had been approved by the Central Committee for Bioethics, University of Kufa and were performed according to its guidelines.

Fourteen mature male rats (*Rattus norvegicus*) were used in present study with age ranging between 2.5 – 3 months, and weighing 148 to 280 gm. They were kept in the animal house under the normal light dark rhythm where they were given food and water supplements for at least two weeks before commencing the experiment.

The animal groups were administrated orally for two weeks and divided into four groups. Group one animals (Negative control) were kept without medication and composed of three rats and were administrated with olive oil because cyclosporine drug was oily and would get dissolved in olive oil. The second group composed of three rats and received powdered garlic 480 mg/kg body weight. The third group composed of four rats and received cyclosporine about 50 mg /kg body weight. The fourth group composed of four rats and received cyclosporine + garlic.

Drugs:

1- Cyclosporine solution was prepared by dissolving oily drug material of cyclosporine capsules in a dose equivalent to 50 mg/kg body weight in 4 ml olive oil and was administrated for two weeks by oral route [10].

2- Garlic solution was prepared by powdered garlic dissolving 480 mg/kg body weight in 13 ml of distilled water and was administrated for two weeks by oral route [10].

Sperm Preparation:

Sperm cells were prepared according to [11]

Histological Study:

Tissue specimens were prepared to study histological changes in testis tissues of experimental animals that were dehydrated in 70% ethanol, embedded in paraffin and cut into 6 mm-thick sections using a rotary microtome according to [12].

The tissue sections were stained with hematoxylin and eosin dyes and were visualized under light microscope to observe histological changes in the testis.

Statistical Analysis:

The data was presented as means \pm S. D and statistically analyzed by using one way ANOVA test at ($P \leq 0.05$) probability of level. t- test was used to compare two independent groups [13].

Results:

The findings of the present research recorded significant $P \leq 0.05$ increment in sperms head and tail deformation rate per 100 cells in groups which were administrated cyclosporine, cyclosporine + garlic for two weeks in comparison with the control group which as administered olive oil and garlic as shown in Tables 1 and 2.

While the study revealed significant $P \leq 0.05$ decrement in sperms head and tail deformation rate per 100 cells in groups which were administrated cyclosporine + garlic for two weeks compared with group which was administrated cyclosporine only as shown in Tables 1 and 2.

Table 1: Effects of cyclosporine and garlic administration for two weeks on the sperms head deformation rate in male albino rats.

Groups	Olive Oil	Garlic	Cyclosporine	Cyclosporine + Garlic
Type of Deformation				
Amorphous shape	0.00±0.00	0.00±0.00	13.1±3.00 a	11.2±1.1 ab
Banana shape	2.6±0.52	0.00±0.00	16.6±0.00 ac	13.6±2.8 abc
Hummer shape	0.00±0.00	0.00±0.00	12.5±0.00 ac	0.00±0.00 c
Head less	2.35±0.16	0.00±0.00	9.5±0.35 ac	7.6±0.00 abc
Striate shape	0.00±0.00	0.00±0.00	14.1±1.6 bc	10.8±0.9 abc
Swollen head	0.00±0.00	0.00±0.00	0.00±0.00	0.00±0.00
Blunt hook	2.75±0.58	2.35±0.16	18.3±1.8 ac	11.9±1.7 abc
Total	7.7±1.26	2.35±0.16	84.1±6.75	55.1±6.5

The mean values for the mean ± the standard deviation (Mean ± S.D) a: significant P≤0.05 difference between treatment and control treated with olive oil, b: significant P≤0.05 difference between treatment and garlic, c: significant P≤0.05 difference between Cyclosporine A+ garlic & cyclosporine A group.

Table 2: Effects of cyclosporine and garlic administration for two weeks on the sperms tail deformation rate in male albino rats.

Groups	Olive Oil	Garlic	Cyclosporine	Cyclosporine + Garlic
Type of Deformation				
Tail less	0.00±0.00	2.27±0.1	17.5±2.00 a	15.9±1.5 ab
Double tail	0.00±0.00	0.00±0.00	7.6±0.00	0.00±0.00
Bent tail	0.00±0.00	0.00±0.00	10.00±0.00 ac	0.00±0.00 c
Curved tail	2.35±0.16	2.35±0.16	14.1±1.60 ac	8.9±1.00 abc
Coiled tail	2.6±0.52	0.00±0.00	18.00±1.40 ac	12.9±0.70 c
Short tail	0.00±0.00	0.00±0.00	10.00±0.00 ac	5.8±0.00 c
Total	4.95±0.68	4.62±0.26	77.2±5.00	43.5±3.2

The mean values for the mean \pm the standard deviation (Mean \pm S.D) a: significant $P \leq 0.05$ difference between treatment and control treated with olive oil, b: significant $P \leq 0.05$ difference between treatment and garlic, c: significant $P \leq 0.05$ difference between cyclosporine A+ garlic & cyclosporine A group

The current research indicated several types of sperm head abnormalities in groups that were administrated cyclosporine drug and cyclosporine + garlic included amorphous shape, banana shape, hummer shape, head less, striate shape, and blunt hook head as shown in Figure 1.

Figure 1: Head Sperm abnormalities in male albino rats A: normal head sperm from control group treated olive oil. B: banana shape head. C: hummer shape head D: amorphous head E: the pointed heads show striate, missed and detached head F: striate head G: Blunted hook from group treated by cyclosporine H-I amorphous head from group treated by cyclosporine + garlic (40x).

Moreover, the present research indicated several types of sperm tail abnormalities in groups which were administrated cyclosporine drug and cyclosporine + garlic included tail-less sperms, double tail, bent tail, curved, coiled and short tail as shown in Figure 2.

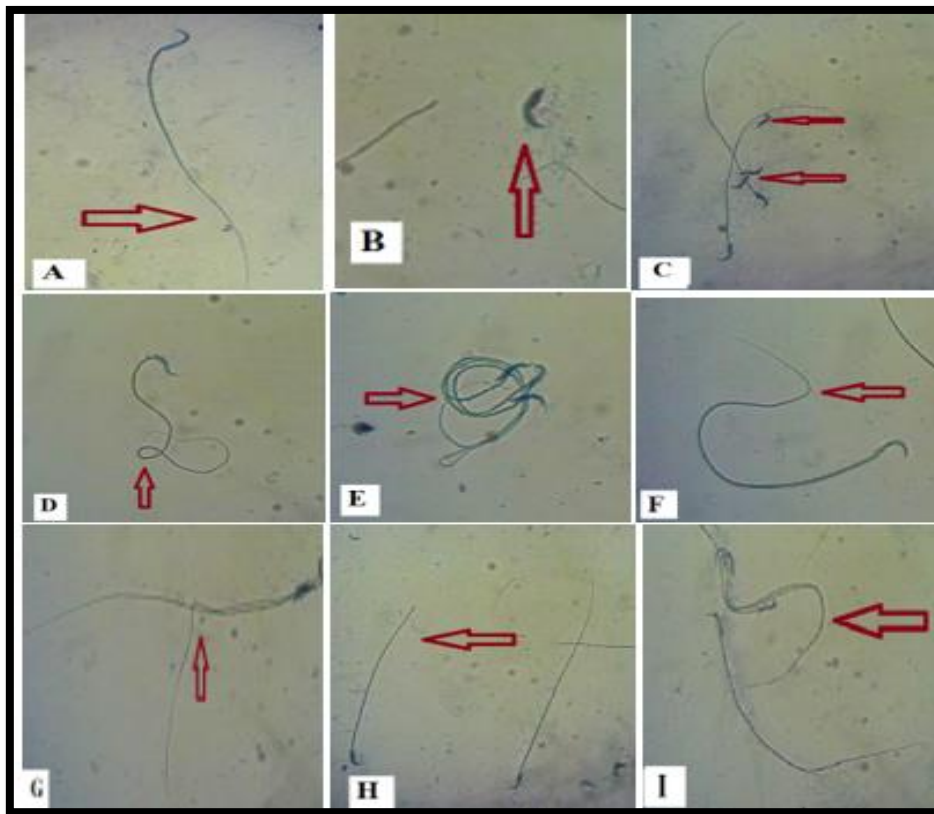


Figure 2: Tail Sperm abnormalities in male albino rats A: normal tail sperm from control group treated olive oil. B-C: tail less sperm. D: coiled tail E: coiled tail F: bent tail G: double tail from group treated Cyclosporine H: short tail from group treated cyclosporine+ garlic I: curved tail from group treated cyclosporine+ garlic(40x).

1- Histological Study - Testes Tissue:

The current research indicated presence of histological changes induced by Cyclosporine drug administration on testes through a study of testes tissues in male albino rats when they were administrated cyclosporine at dose of 50 mg/kg body weight for two weeks. The results also indicated that the protective role of garlic and its ability to reduce the histological changes in the testes tissues as shown in Figures 3 and 4.

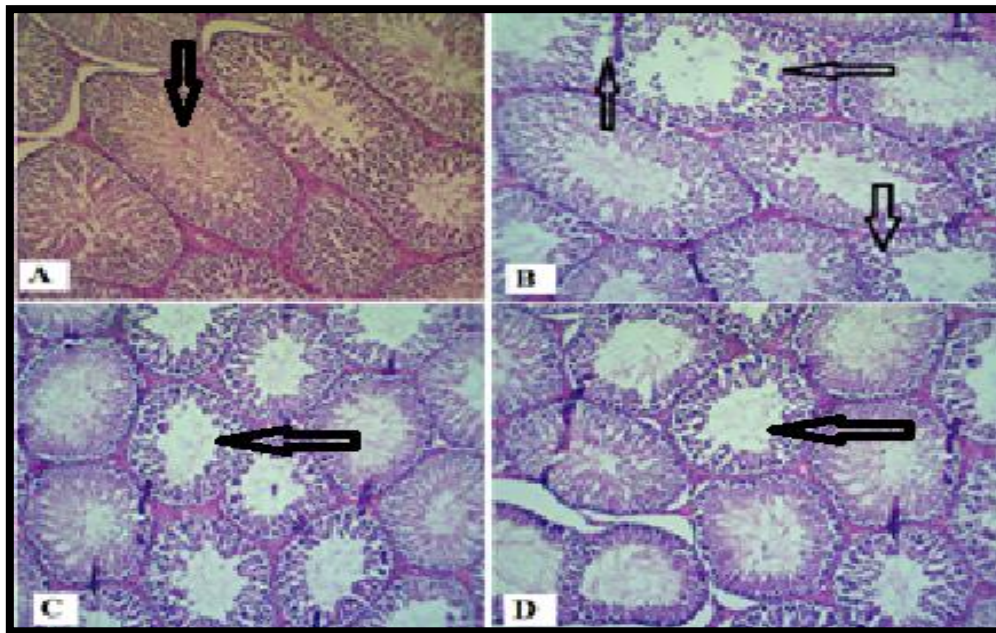


Figure 3: Cross-section of testes in male albino rats A: control group treated olive oil showing no change in testes architecture. B: from group treated cyclosporine showing depletion of the spermatogonial cells (some seminiferous tubules appeared with one or two layers of spermatogonia). C-D: from group treated Cyclosporine+ garlic showing slight change from normal testes architecture, seminiferous tubules with maturation of spermatogony and sperms inside the lumen (H&E X100).

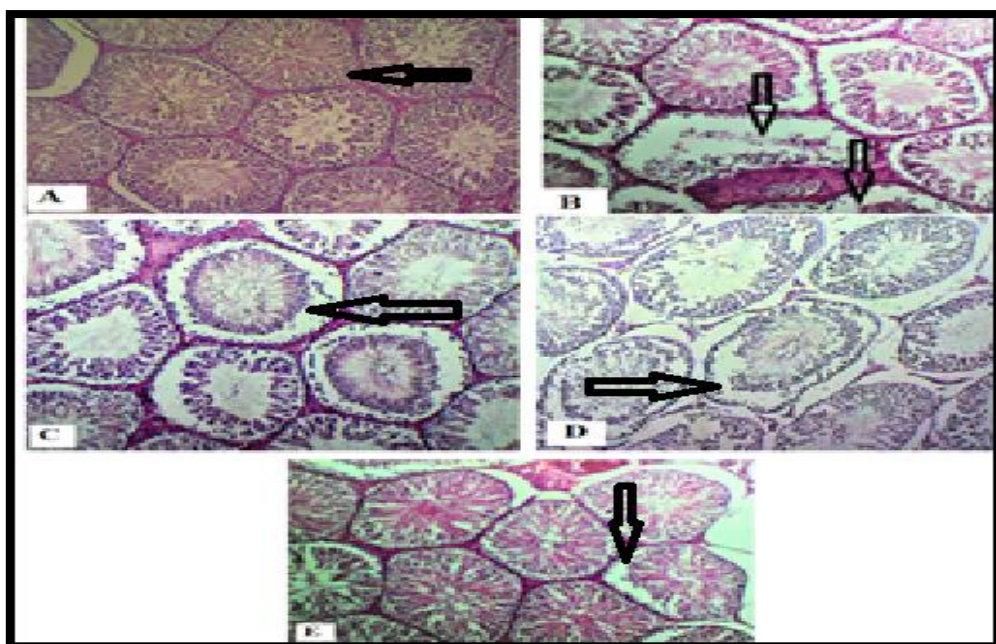


Figure 4: Cross-section of testes in male albino rats A: control group treated garlic showing no change in testes architecture. B-D from group treated cyclosporine showing degenerative changes represented great depletion of the spermatogonial cells (most seminiferous tubules appeared with one or two layers of spermatogonia and in picture d: absence of Leydig cells. E: from group treated cyclosporine + garlic showing slight change from normal testes architecture, somniferous tubules with maturation of spermatogony and sperms inside the lumen (H&E X 100).

In addition, the results in Figure 3 and 4 indicated depletion of the spermatogonial cells (some seminiferous tubules appeared with one or two layers of spermatogonia) and disruption or absence of leydig cells in group treated cyclosporine for two weeks. While the findings showed slight changes in normal testes architecture, seminiferous tubules with maturation of spermatogonia and sperms inside the lumen in the group that was administrated cyclosporine + garlic for two weeks.

Discussion:

1- Sperms Head and Tail Deformation

The findings in Tables 1 and 2 agree with Baykalir *et al* [14] concerning that cyclosporine drug significantly increases total abnormal sperm rates while decreasing the concentration and motility of sperms in rats compared with the control group.

In addition, the results agree with Khattab and Mansoury [15] who found that cyclosporine A causes reactive oxygen species production and induces testicular toxicity and sperm abnormalities. Likewise, these findings agree with Ghazipour *et al.* [16] regarding that cyclosporine participated in elevating oxidative stress damage markers and apoptotic cells in testis of Wistar male rats. This result also agrees with Jennings *et al.* [17] who mentioned cyclosporine increases hydrogen peroxide production which causes cytotoxicity.

The results in Table 1 are supported by Kaneko *et al.*[18] who found that garlic components and derivatives participate in DNA repair mechanisms and then boost the cell division, induction apoptosis. In the same way, this finding agrees with Kaneko *et al.* [19] who found that the components of garlic can bind to most of the growth factor receptors and control DNA damage.

The findings agree with Morales-Gonzalez *et al.* [20] as well who revealed the greatest anti-mutagenic role of garlic and its geno-protective effects which associated their antioxidant properties, reducing oxidative stress and repairing DNA damage. In addition, the results are in agreement with Shukry *et al.* [21] regarding that garlic extract has an ability to maintain health by improving and has protective effects against toxicity induced by carcinogens and chemicals and drugs such as cyclosporine. Our result are consistent with a study of Abdalla and Gad [22] which found that grounded and fresh garlic can be used as inhibitor of cells cancer, and it also reduces abnormalities of chromosomes by diallyl disulfide. These compounds have anti-mutagenic effects and are capable of inhibiting both cytogenetic and cytotoxic damage induced by inorganic materials.

2 - Histological Study - Testes Tissue:

The results of the study are shown in Figures 3 and 4 and are supported by Hardinger *et al.*[23] concerning that cyclosporine is a very large lipophilic cyclic peptide, characterized by binding with high affinity to cyclophilins (a family of cytoplasmic proteins present in most cells of the body). In addition, these results agree with Ghazipour *et al.* [16] who reported that cyclosporine induces testicular damage which is evidenced by increasing oxidative stress damage markers and apoptotic cells.

Furthermore, these findings are in agreement with Yoshinag *et al.* [24] who reported that cyclosporine induces oxidative injuries and other harmful effects of testes tissue are represented by damaged seminiferous tubules, stoppage of the maturation of spermatogonia and the presence of cells with irregular dense nuclei in the lumina of some tubules.

Moving further, the results also indicated protective role of garlic and its ability to reduce the histological changes in the testes as shown in Figures 3 and 4. This is supported by Kaneko *et al.* [19] who reported that garlic components are capable of improving different agent toxicities in body organs, cyto-protective activities represented by antioxidant effect, radical scavenging, reducing lipid peroxidation, anti-inflammatory, increase in protein synthesis in the damaged tissues and apoptosis suppression.

The results of this current study also agree with other recent studies regarding that garlic and its oil supplementation has a positive impact on cyclosporine A-induced hepatic and sperm toxicity, this could occur by improving and increasing antioxidants gene expression activities such as superoxide dismutase, catalase, glutathione S-transferase and glutathione which causes a reduction in lipid peroxidation and prevents tissue damages[24, 25] .

Conclusion: Cyclosporine drug administration at a dose of 50 mg/kg body weight for two weeks had significant increment in the sperm head and tail deformation rate per 100 cells in albino rat males compared with control, the garlic reduced the istopathological changes in rat testes and showed protective and improving role against cyclosporine cytotoxicity and testicular damage, this positive effect of garlic was achieved during administration for two weeks at a dose of 480 mg/kg body weight.

References:

- [1] J. Patocka, E. Nepovimova, K. Kuca, and W. Wu, "Cyclosporine A: chemistry and toxicity—a review" ,*Current medicinal chemistry*, vol. 28, no. 20, pp. 3925-3934, 2021.
- [2] M. Abdelkader, M. Hilal, A. R. Torky., H. Elsayed, and W. Allam, "The ameliorative effect of N-acetylcysteine on cyclosporine induced testicular toxicity in male albino rats" ,*Ain Shams Journal of Forensic Medicine and Clinical Toxicology*, vol. 36, no. 1, pp. 123-129, 2021.
- [3] X. Yang , P. Feng, Y. Yin, K . Bushley, J. W. Spatafora and C. Wang, "Cyclosporine biosynthesis in *Tolypocladium inflatum* benefits fungal adaptation to the environment" ,*MBio*, vol. 9, no. 5, e01211-18, 2018.
- [4] A. M. Kabel, S. A. Salama, A. A. Alghorabi, and R. S Estfanous, "Amelioration of cyclosporine-induced testicular toxicity by carvedilol and/or alpha-lipoic acid: Role of TGF-β1, the proinflammatory cytokines, Nrf2/HO-1 pathway and apoptosis" ,*Clinical and Experimental Pharmacology and Physiology*, vol. 47, no. 7, pp. 1169-1181, 2020.
- [5] Q. Wu, X. Wang , E. Nepovimova , Y. Wang., H. Yang., and K. Kuca, "Mechanism of cyclosporine A nephrotoxicity: oxidative stress, autophagy, and signaling" , *Food and Chemical Toxicology*, vol. 118, pp. 889-907, 2018.
- [6] V. P. Londhe., A. T. Gavasane., S. S. Nipate., D. D., Bandawane and P. D. Chaudhari, "Role of garlic (*Allium sativum*) in various diseases: An overview" ,*angiogenesis*, vol.12, no. 13, 2011.
- [7] A. Shang., S. Y. Cao., X. Y. Xu., R. Y. Gan., G. Y Tang., H. Corke and H. B. Li, "Bioactive compounds and biological functions of garlic (*Allium sativum L.*)" , *Foods*, vol. 8, no. 7, p. 246, 2019.
- [8] G. El-Saber Batiha., A. G. Magdy Beshbishy, L. Wasef., Y. H. Elewa., A. A Al-Sagan., A. El-Hack and H. Prasad Devkota, "Chemical constituents and pharmacological activities of garlic (*Allium sativum L.*): A review" , *Nutrients*, vol. 12, no. 3, pp. 872, 2020.
- [9] J. S. Moffit., BH. Bryant, SJ. Hall, K. Boekelheide, "Dose-dependent effects of sertoli cell toxicants 2,5-hexanedione, carbendazim, and mono-(2-ethylhexyl) phthalate in adult rat testis " , *Toxicol Pathol.*; vol. 35, pp.719–727, 2007. [PubMed] [Google Scholar].
- [10] A. A. E. M. Tohamy, "Genotoxic and molecular studies on cyclosporine A-azithromycin interaction and the protective effect of garlic during administration,"*The Egyptian Society of Experimental Biology*, vol. 1, pp. 141 – 150, 2013.
- [11] J. Seed., RE. Chapi, ED. Clegg., LA. Dostal., RE. Foote., ME. Hurtt., GR. Klinefelter., SL. Makris., SD. Perreault., S Schrader, D. Seyler., R. Sprando., KA. Treinen., DN. Rao Veeramachaneni., LD.Wis,"Methods for assessing sperm motility, morphology, and counts in the

- rat, rabbit, and dog: a consensus report" ,*Reprod Toxicol.*, vol.10, no. 3, pp. 237-244.10.1016/0890-6238(96)00028-7 ,1996.
- [12] J. Bancroft and Stevens, "A Theory and practice f Histological Technique 4th"*New York: Churchill Liingstone*, pp.113-118 , 1999.
- [13] H. J. Motulsky., GraphPad Prism Version 4.0" .Statistics Guide-Statistical analyses for laboratory and clinical researcher," *GraphPad Software Inc., San Diego CA* ,2003.
- [14] B. G. Baykalir., P. T. Seven., S. Gur., and I. Seven, "The effects of propolis on sperm quality, reproductive organs and testicular antioxidant status of male rats treated with cyclosporine-A , " *Animal Reproduction (AR)*, vol. 13, no. 2, pp. 105-111, 2018.
- [15] H. H. Khattab and M. M. Mansoury, "Costus afer leaf extract protects against testicle damage caused by cyclosporine A in adult male Wistar rats through an antioxidant mechanism" ,*Andrologia*, vol. 52, no. 5, pp. e13561, 2020.
- [16] A. M. Ghazipour., A. Shirpoor, R. Ghiasi., B. Pourheydar., N. Khalaji., and R.Naderi, "Cyclosporine A induces testicular injury via mitochondrial apoptotic pathway by regulation of mir-34a and sirt-1 in male rats: The rescue effect of curcumin" ,*Chemico-Biological Interactions*, vol. 327, pp. 109180, 2020.
- [17] P. Jennings., C. Koppelstaetter., S. Aydin., T. Abberger., A. M.Wolf., G.Mayer and W.Pfaller., "Cyclosporine A induces senescence in renal tubular epithelial cells",*American Journal of Physiology-Renal Physiology*, vol. 293, no. 3, pp. F831-F838, 2007.
- [18] R. K. Upadhyay, "Garlic induced apoptosis, cell cycle check points and inhibition of cancer cell proliferation" ,*Journal of Cancer Research*, vol. 5, no. 2, pp. 35-54, 2017.
- [19] T. Kaneko., K. Shimpo., T. Chihara., H. Beppu., A. Tomatsu., M. Shinzato and T. Higashiguchi, "Inhibition of ENNG-induced pyloric stomach and small intestinal carcinogenesis in mice by high temperature-and pressure-treated garlic" ,*Asian Pacific Journal of Cancer Prevention*, vol. 13, no. 5, pp. 1983-1988, 2012.
- [20] J. A. Morales-Gonzalez., E. Madrigal-Bujaidar., M. Sanchez-Gutierrez., J. A. Izquierdo-Vega., M. D. C. Valadez-Vega., I. Alvarez-Gonzalez, and E. Madrigal-Santillan, "Garlic (Allium sativum L.): A brief review of its antigenotoxic effects" ,*Foods*, vol. 8, no. 8, pp. 343 ,2019.
- [21] M. Shukry., S. S. Alotaibi., S. M. Albogami., N. Fathallah., F. Farrag., M. A. Dawood., and M. S. Gewaily, "Garlic Alleviates the Injurious Impact of Cyclosporine-A in Male Rats through Modulation of Fibrogenic and Steroidogenic Genes" ,*Animals*, vol. 11, no. 1, pp. 64, 2021.
- [22] E. Abdalla., and M. Gad, "Protective role of diallyl disulphide compound (from garlic extract) against mercuric chloride–induced genotoxicity and cytotoxicity in albino rats ,"2008.
- [23] K. Hardinger., C. C. Magee., and D. C. Brennan, "Pharmacology of cyclosporine and tacrolimus" ,*Waltham: Up To Date* 2019.
- [24] T. T. Yoshinag., J. R. K. Júnior., A. J.Butzge., R. L.Olio., F. J. Hernandez-Blazquez., A. C. O. Carreira.,... and R. S.Hattori, "Testicular subcutaneous allografting followed by immunosuppressive treatment promotes maintenance of spermatogonial cells in rainbow trout (Oncorhynchus mykiss)" ,*Fish & Shellfish Immunology*, vol. 112, pp. 108-115 ,2021.
- [25] M. S. Khan., N. A. Qureshi., F. Jabeen., M. Wajid., S. Sabri., and M. Shakir, "The role of garlic oil in the amelioration of oxidative stress and tissue damage in rohu Labeo rohita treated with silver nanoparticles" ,*Fisheries Science*, vol. 86, no. 2, pp. 255-269, 2020.