

Radiological Evaluation of the Anatomic Characteristic of Lingual Foramina and Their Vascular Canals in the Anterior Region of the Mandible Using Cone Beam Computed Tomography

Fatima M. Abd Al-khuthar, B.D.S.⁽¹⁾

Ahlam A. Fatah, B.D.S., M.Sc.⁽²⁾

ABSTRACT

Background: presence of lingual vascular foramina and canals in the interforaminal region may increase the risk of surgical complications during implant placement or any surgical procedure in this area. Aim of this study is the radiological evaluation of the anatomic characteristic of the lingual foramina and their vascular canals in the anterior of the mandible using cone beam computed tomography.

Materials and Methods: Prospective study including 72 Iraqi subjects (31 male and 41 female) ranging from 20 to 59 years, all subjects attended Al-Sharaa dental clinic in AL-Najaf AL-Ashraf city, scanned with CBCT from September 2016 to February 2017. Using 3dimensional and sagittal cross section to detect lingual foramina and their vascular canals. Their presence, number, diameter, position, and orientation were established.

Results: Lingual foramina in the anterior mandible were viewed in whole sample. Number of lingual canals varied from (1-5), the average diameter of the canals was 0.81 mm. The average distance from the foramina to the base of the mandible and to the alveolar crest was 13.78 mm and 16.05mm respectively. There was no significant correlation found between age and gender on all selected measurements. There was significant association of diameter of lingual foramen with the count, situation, extent and direction of lingual canal through the mandible width.

Conclusion: Cone beam computed tomography is an invaluable system in diagnosis and treatment planning of surgical procedures. It help in detection of various anatomic features of mandible like presence of lingual foramen and canals in the anterior mandible.

Keywords: Lingual foramina and their vascular canals, Anterior of the mandible, CBCT. (*J Bagh Coll Dentistry 2018; 30(1): 23-27*)

INTRODUCTION

The interforaminal region of the mandible (area constricted between the two mental foramina) is deemed as safe region that because anatomical features like submandibular fossa and the inferior alveolar canal are positioned posterior to it⁽¹⁾. In fact there are some serious anatomical features even in this region including lingual foramina (LF) and canals (LC), incisive canal and the lingual shell concavity⁽²⁾.

The lingual foramen is a small opening situated on the lingual side surface of the anterior mandible through which small blood vessels pass. The lingual foramina is usually situated in the midline of the internal surface of the mandible at the level of or superior to the mental spines⁽³⁾. The contents of LC have not been clarified and are still debated⁽⁴⁾. Many studies submit that a neurovascular bundle pass into the LF^(5,6). However, others declared that the LC includes just artery^(4,7).

The anterior of mandible (AOM) is supplied by three arteries: sublingual artery, submental artery, chin artery⁽⁸⁾.

During surgical operation of dental implant, orthognathic surgery and osteodistraction in AOM, there is a possibility to damage the vital structure in this area resulting in severe bleeding⁽¹⁾. This hemorrhage may not be noticed instantly within the operation results in big hematoma in the floor of the mouth leading to airway obstruction⁽⁹⁾. To avoid this complication, the surgeon should have good knowledge about the anatomical structures in AOM and be carefully prepared for the operation by utilizing the valuable 3 dimensional radiography (3-D) and regulating software present in cone-beam computed tomography (CBCT), the more recent scanning contrivance^(8,10), that give image with great resolution, comparatively low irradiation dosage and actual size of substantial bony structures of the AOM on various planes of view^(11,12).

In this study, the LF and their bony canals at AOM were assessed by utilizing CBCT images of Iraqi adult patients to provide useful preoperative evaluation.

MATERIALS AND METHOD

In this cross-sectional study included 72 Iraqi adult subjects (male and female) ranging from 20 to 59 years, attend Al-Sharaa dental clinic in Al-Najaf Al-Ashraf City, scanned with CBCT image for

(1) MSc. Student, Department of Oral and Maxillofacial, Radiology, Collage of Dentistry, University of Baghdad

(2) Assist. Professor, Department of Oral and Maxillofacial, Radiology, Collage of Dentistry, University of Baghdad

different surgical interventions from September 2016 to February 2017.

Images were acquired using GenDex Finland CBCT unit and exposure factors were set ranging from 6.3-8.0 mA and 90 Kv. The acquired images were processed with Anatomage Invivo 5.4 3D imaging dental software and slice thickness 0.1mm.

AOM carefully inspected on the midline and around the midline for checking the present of LF and their bony canals. The number of LF as shown in figure 1, diameter (categorized the foramen diameters as <1 and ≥ 1 mm) and the orientation of LC (descending trajectory, ascending trajectory or horizontal)⁽²⁾ were analyzed on the 3D and sagittal view, the position of LF was described in relation to genial tubercle (above, below)⁽⁴⁾, the distance from the lower cortex border of the foramina to the inferior border of the mandible (main foramina) upper one as shown in figure 2 and the distance from the upper cortex border of the foramina to the alveolar crest as shown in figure 3. The extent of penetration of LC through the width of mandible (lingual, middle, buccal third), as shown in figure 4.

Statistical analyses were done using IBM SPSS version 21 computer software. Compliance of a continuous quantitative random variables with Gaussian curve (normal distribution) was analyzed using the Kolmogorov-Smirnov test. The statistical significance of difference in mean between two groups was assessed using the independent samples t-test, while between more than two groups ANOVA model was used. ANOVA trend was used when the independent (grouping variable) was an ordinal level variable.

The accuracy and reproducibility of examiner readings was determined by means of inter-examiner calibration to compare the readings of examiner (10 randomly selected readings) with those performed by professional senior, the comparison appeared no significant difference between the first and second examiners readings when paired t-test was applied. Also all the measurement repeated by the same examiner after 2 weeks from the first reading (intra-examiner calibration) on randomly selected 10 subjects, comparison of two reading showed non-significant difference when paired t-test was applied.

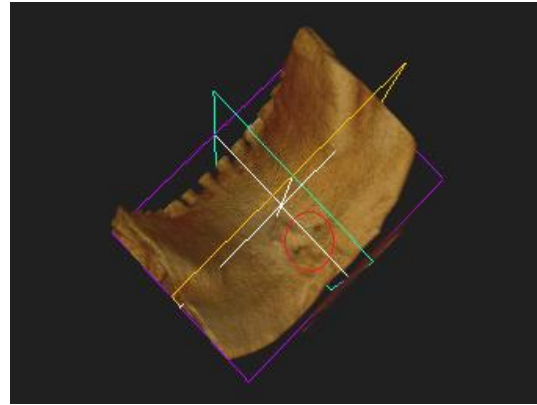


Figure 1: 3D image showing the present of more than one lingual canal in the lingual median region of the mandible (2 canals)

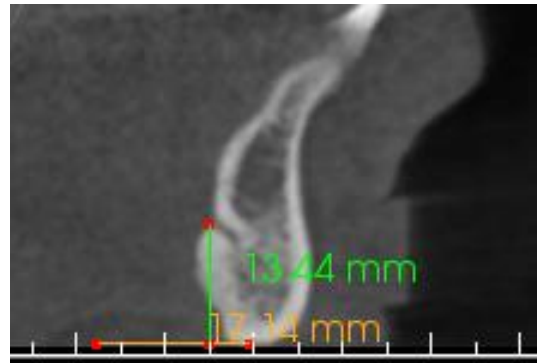


Figure 2: Distance from the lower cortex border of the lingual foramen to the base of the mandible (13.44mm)

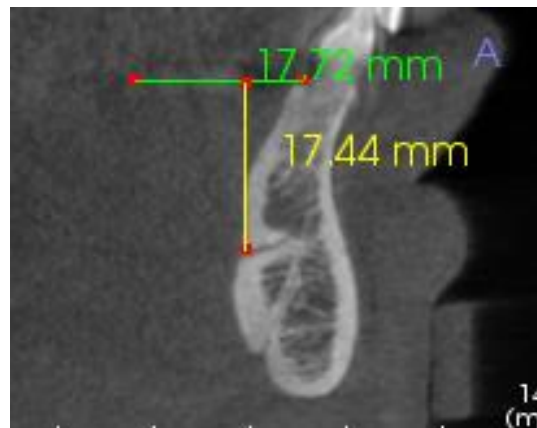


Figure 3: Distance from the upper cortex border of the lingual foramen to the crest of alveolar bone (17.44mm)

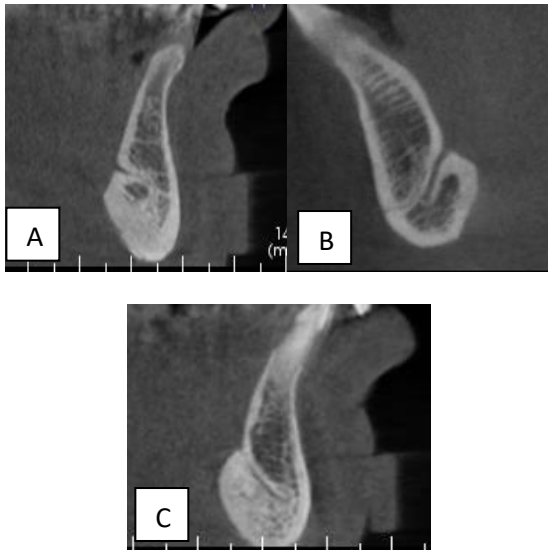

Figure 4: Lingual vascular canal penetrated only the lingual third of the width of mandible in (A), lingual canal reached middle third in (B) and in (C) the lingual canal extends to the buccal third.

RESULTS:

The data were analyzed, 160 LC from 72 subjects, LF is observed in 72 (100%) of study sample, and 55 (76.4%) had multiple LC (two canals 38.9%, three canals 31.9%, four canals 2.8%, and five canals 2.8%).

LC traverse the mandibular bone to a variable extent, 40 of total 160 canals extended through only the lingual third of the mandible width, the majority (55.6%) extended to the middle third and only 19.4% reached to the buccal third, there was a moderately strong positive (direct) linear correlation between canal diameter of LF and depth of penetration inside the mandible $r=0.432$, $P<0.001$ as shown in figure 5.

The orientation of LC was detected in the sagittal plane, 83 of total 160 canals had descending trajectory, 35% of the canals had ascending trajectory and 13% were solely anterior.

In relation to genial tubercle (GT), 87 (54.4%) of total 160 canals were above GT and 45.6% were found below GT, there was statistically significant linear correlation between the diameter of LF and the count of LC per subject with the position of LF in relation to GT as shown in table 1.

The mean distance from LF to the base and alveolar crest of the mandible was 13.78mm and 16.05mm respectively. The correlation between age or gender with the measurement of the distance from LF to the base and alveolar crest of the mandible showed statistical not significant difference as shown in table 2 and 3.

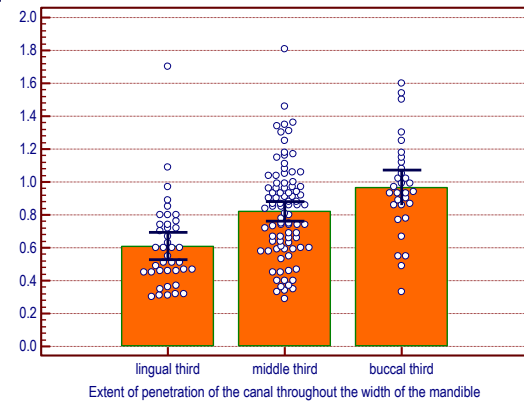


Figure 5: Association of the extent of penetration of the LC through the width of the mandible with the diameter of the canal

Table 1: Association of the position of lingual canal opening in relation to genial tubercle with the diameter of the canal

Diameter of canal (mm)	Position of LC opening - genial tubercle		P
	Below	Above	
Range	0.31 to 1.81	0.29 to 1.7	<0.001
Mean	0.69	0.89	
SD	0.27	0.31	
SE	0.03	0.03	
N	73	87	

Table 2: Distance from the lingual foramen to the base of the mandible

Accurate measurements	
Range	4.18 to 18.72
Mean	13.78
SD	2.94
SE	0.35
Number of subjects	72
Range of normal values (5 th to 95 th centile)	7.64 to 18.08

Table 3: The distance from the lingual foramen to the alveolar crest

Accurate measurements	
Range	4.18 to 18.72
Mean	13.78
SD	2.94
SE	0.35
Number of subjects	72
Range of normal values (5 th to 95 th centile)	7.64 to 18.08

The range of the diameter of the LC was 0.3mm-1.8mm with mean 0.81mm, about 28.1% of all the subjects had LF with diameter ≥ 1 mm. We categorized the foramen diameters as <1 and ≥ 1 mm to give an idea about the hazard of haemorrhage severity. There was statistically significant indirect linear correlation between the diameter and count of LC per subject as shown in figure 6.

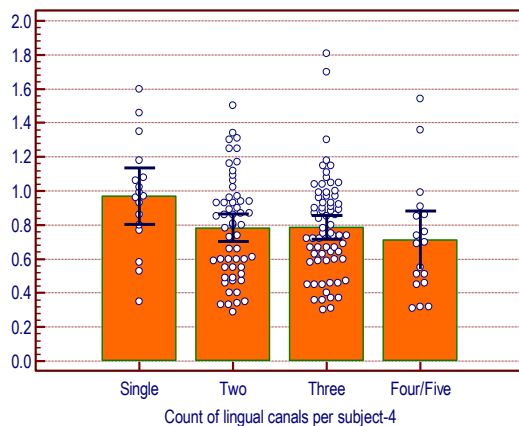


Figure 6: Association of the count of lingual canal per subject with the diameter of the canal

DISCUSSION

In the AOM there are many anatomical landmarks, such as foramina and vascular canals. Due to neurovascular content of LC, any trauma to this canal may cause haemorrhage or neurosensory complications. Consequently, that very important to do well planning preoperatively by radiological investigation to avoid any neurovascular disturbances. Imaging by CBCT provides perfect visualization of foramina and canals, because there is no superimposition of the anatomical structures (especially in the AOM)⁽¹³⁾.

In the present study all the CBCT images taken showed the present of LF, and the number of canals ranged from 1 to 5 per patient. These finding come in agreement with Tepper *et al.*⁽¹⁴⁾ Gahleitner *et al.*⁽⁹⁾ Park *et al.*⁽¹⁶⁾. The majority of LC extend to the middle third of the mandible width, and these findings agreed with Abesi *et al.*⁽¹⁵⁾ Babiuc *et al.*⁽²⁾. Most LC had descending direction, the trajectory of the LC described in this study is similar to that described by Babiuc *et al.*⁽²⁾ Liang *et al.*⁽⁵⁾ Tepper *et al.*⁽¹⁴⁾ McDonnell *et al.*⁽¹⁷⁾. The LF were above the GT more than that present below it, that come in accordance with Babiuc *et al.*⁽²⁾ Bernardi *et al.*⁽¹⁸⁾ and Denny *et al.*⁽¹⁹⁾. The average distance from the LF to the alveolar crest was of 16.05mm, with a minimum of 8.67mm and

a maximum of 27.71mm. Previous studies^(2,19,20) agreed with the results of the present study and the difference in mean distance value is probably due to anatomical variation and different ethnicity.

The relative frequency of subjects with canal diameter ≥ 1 mm is (28.1%) that was agreed with the study made by Babiuc *et al.*⁽²⁾ Yildirim *et al.*⁽²¹⁾. The results of the present study in table 1 showed highly significant correlation between diameter of LF and the position of it ($P < 0.001$). Our results come in agreement with Sheikhet *et al.*⁽²⁰⁾ Liang *et al.*⁽⁵⁾ and Bernardi *et al.*⁽¹⁸⁾ who analyzed the morphology of LF and found that it had mainly an oval shape, the main axis of the superior LF located vertically, while the main axis of the inferior LF located horizontally. These findings can express the exceeding of the superior LF in diameter than the inferior one.

Figure 5 showed that the penetration of the LC through the width of the mandible had direct linear correlation with the diameter of LF. No previous study, however, had described this association as seen in this study.

There is an important relationship between the diameter of LF opening and the size of blood vessels that go through them, and the vessels with a diameter less than 1mm are a potential hemorrhagic index risk^(2,18).

Figure 6 showed significant association of the count of LC per subject with the diameter of the canal. No previous reports had described this association. However, Liang *et al.*⁽⁵⁾ who reported that the majority of lower jaw having two LF, the larger one with greater dimensions (longer canal and larger diameter) was similar to single canals. In conclusion, CBCT imaging provides perfect visualization of lingual foramen. There was statistically significant linear correlation between the position, extent, count of LF and its diameter. There was statistically significant linear correlation between the count and the extent of LC per subject with the position of LF in relation to genial tubercle. The correlation between age or gender with the measurement of the distance from the lingual foramen to the base and alveolar crest of the mandible showed no statistically significant difference.

REFERENCES

1. Liang H, Frederiksen NL, Benson BW. Lingual vascular canals of the interforaminal region of the mandible: evaluation with conventional tomography. *Dentomaxillofac Radiol* 2004; 33(5):340-1.
2. Babiuc I, Tărlungeanu I, Păuna M. Cone beam computed tomography observations of the lingual foramina and their bony canals in the median region of the mandible. *Rom J Morphol Embryol* 2011; 52(3):827-9.

3. Mraiwa N, Jacobs R, Moerman P, Lambrichts I, van Steenberghe D, Quirynen M. Presence and course of the incisive canal in the human mandibular interforaminal region: two-dimensional imaging versus anatomical observations. *Surg Radiol Anat* 2003; 25(5-6):416-23.
4. Rosano G, Taschieri S, Gaudy JF, Testori T, Del Fabbro M. Anatomic assessment of the anterior mandible and relative hemorrhage risk in implant dentistry: A cadaveric study. *Clin Oral Implants Res* 2009; 20(8):791-5.
5. Liang X, Jacobs R, Lambrichts I, Vandewalle G. Lingual foramina on the mandibular midline revisited: a macroanatomical study. *Clin Anat* 2007; 20(3):246-51.
6. Natekar PE, De Souza FM, Natekar P. Variations in position of lingual foramen of the mandible in reconstructive surgery. *Indian J Otol* 2011; 17(1):12-3.
7. Lustig JP, London D, Dor BL, Yanko R. Ultrasound identification and quantitative measurement of blood supply to the anterior part of the mandible. *Oral Surg Oral Med Oral Pathol Oral Radiol Endod* 2003; 96: 625-9.
8. Balaguer Marti JC, Guarinos J, Serrano Sánchez P, Ruiz Torner A, Peñarrocha Oltra D, Peñarrocha Diago M. Review of the arterial vascular anatomy for implant placement in the anterior mandible. *J Oral Sci Rehabil* 2016; 2(1):32-9.
9. Gahleitner A, Hofschneider U, Tepper G, Pretterklieber M, Schick S, Zauza K, Watzek G. Lingual Vascular Canals of the Mandible: Evaluation with Dental CT. *Radiology* 2001; 220(1):186-9.
10. Neves FS, Vasconcelos TV, Oenning AC, de-AzevedoVaz SL, Almeida SM, Freitas DQ. Oblique or orthoradial CBCT slices for preoperative implant planning: which one is more accurate?. *Braz J Oral Sci* 2014; 13(2): 104-8
11. Liang X, Jacobs R, Hassan B, Li L, Pauwels R, Corpas L, et al. A comparative evaluation of cone beam computed tomography (CBCT) and multi-slice CT (MSCT) Part I. On subjective image quality. *Eur J Radiol* 2010; 75: 265-9.
12. De Oliveira-Santos C, Souza PH, de Azambuja Berti-Couto S, Stinkens L, Moyaert K, Rubira-Bullen IR, et al. Assessment of variations of the mandibular canal through cone beam computed tomography. *Clin Oral Investig* 2012; 16: 387-93.
13. Dreiseidler T, Mischkowski RA, Neugebauer J, Ritter L, Zöllner JE. Comparison of cone-beam imaging with orthopantomography and computerized tomography for assessment in presurgical implant dentistry. *Int J Oral Maxillofac Implants* 2009; 24(2):216-25.
14. Tepper G, Hofschneider UB, Gahleitner A. Computed Tomographic Diagnosis and Localization of Bone Canals in the Mandibular Interforaminal Region for Prevention of Bleeding Complications During Implant Surgery. *Int J maxillofac implants* 2001; 16(1):68-72.
15. Abesi F, Ehsani M, Haghani S, Sohanian S. Assessing the Anatomical Variations of Lingual Foramen and its Bony Canals with CBCT. *Int J Sci* 2015; 20(1): 220-7.
16. Park TJ, Lee SH, Lee KS. A method for mandibular dental arch superimposition using 3D cone beam CT and orthodontic 3D digital model. *Korean J Orthod* 2012; 42(4):169-181.
17. McDonnell D, Nouri MR, Todd ME. The mandibular lingual foramen: A consistent arterial foramen in the middle of the mandible. *J Anat* 1994; 184(2):363-9.
18. Bernardi S, Rastelli C, Leuter C, Gatto R, Continenza MA. Anterior Mandibular Lingual Foramina: An In Vivo Investigation. *Anat Rese Internat* 2014:1-6
19. Denny CE, Natarajan S, Ahmed J, Binnal A, Jindal R. Anatomic variation in lingual foramen: a cone beam computed tomography study. *World J Dent* 2016; 7(4): 179-81.
20. Sheikhi M, Mosavat F, Ahmadi A. Assessing the anatomical variations of lingual foramen and its bony canals with CBCT taken from 102 patients in Isfahan. *Dent Res J* 2012; 9 (7): 45-51.
21. Yildirim YD, Galindo-Moreno P, Velasco-Torres M, Juodzbals G, Kubilius M, Gervickas A, Al-Hezaimi K, Al-Sadhan R, Yilmaz HG, Asar NV, Karabulut E, Wang HL, Tözüm TF. Evaluation of mandibular lingual foramina related to dental implant treatment with computerized tomography: a multicenter clinical study. *Implant Dent* 2014; 23(1):57-63.

الخلاصة

الخلفية: وجود الثقبة اللغوية وقنوات الأوعية الدموية في المنطقة المحصورة بين الثقبتين الذقنية قد يزيد من خطر المضاعفات الجراحية أثناء وضع الغرسة أو أي إجراء جراحي في هذه المنطقة.

الهدف من هذه الدراسة: التقييم الإشعاعي للخصائص التشريحية للثقبة اللغوية وقنوات الأوعية الدموية في مقدمة الفك السفلي باستخدام التصوير المقطعي ذو الشعاع المخروطي.

المواد والطرق: دراسة استطلاعية شملت 72 مواطنا عراقيا (31 من الذكور و 41 من الإناث) تتراوح أعمارهم بين 20 و 59 عاماً، وحضر جميع المشاركين عيادة الشرع لطب الأسنان في مدينة النجف الأشرف، وتم تصويرهم بواسطة جهاز التصوير المقطعي ذو الشعاع المخروطي من سبتمبر 2016 إلى فبراير 2017 واستخدام المقطع العرضي والصور ثلاثية الأبعاد للكشف عن وجود الثقبة اللغوية وقنواتها، قطرها، موقعها، وتوجهها.

النتائج: تم اكتشاف الثقوب اللغوية في مقدمة الفك السفلي في العينة كاملة. وتراوح عدد القنوات اللغوية من (5-1)، وبلغ متوسط قطر القنوات (0.81 مم). كان متوسط المسافة من الثقبة إلى قاعدة الفك السفلي والعروة السنخية (13.78 مم) و (16.05 mm) على التوالي. وظهرت النتائج أنه لم يكن هناك أي تأثير للعمر ونوع الجنس على جميع القياسات المختارة. كان هناك ارتباط كبير بين قطر الثقبة اللغوية مع العدد والموقع والتغلغل والاتجاه للقناة اللغوية من خلال عرض الفك السفلي.

الاستنتاج: التصوير المقطعي ذو الشعاع المخروط هو نظام لا يقدر بثمن في التشخيص وخطة العلاج للعمليات الجراحية. أنها تساعد في الكشف عن الملامح التشريحية المختلفة مثل وجود الثقبة اللغوية والقنوات في مقدمة الفك السفلي.