

## Treatment Of Verruca Vulgaris with Long Pulsed Nd:YAG Laser 1064 nm In Iraqi Patients

علاج داء الثآليل الشائع بليزر النادميوم / النابض الطويل ذو الطول الموجي ١٠٦٤ نانومتر عند المرضى العراقيين

Haider Al-Sabak\*

Muhsin A.Al-Dhalimi\*\*

Wid Abbas Ali\*\*\*

### الخلاصة:

**خلفية البحث:** داء الثآليل الشائع هو من مشاكل الأمراض الجلدية الشائعة. عادةً ما تكون العلاجات التقليدية لداء الثآليل غزويه وذات فعالية منخفضة وتحتاج إلى فترة نقاهة طويلة.

**الهدف:** تقييم فعالية وسلامة ليزر النادميوم / النابض الطويل ذو الطول الموجي ١٠٦٤ نانومتر في علاج داء الثآليل الشائع.  
**المنهجية:** في هذه التجربة السريرية العلاجية ، تم تسجيل خمسة وثلاثين مريضاً مع ما مجموعه ١٠٥ آفات. كان كل مريض مؤهلاً لمدة تصل إلى ثلاث جلسات علاج في فاصل ٢ أسابيع مع ليزر نادميوم / نابض طويل. تم تقييم جميع الثآليل قبل كل جلسة وثلاثة أشهر بعد جلسة العلاج الأخيرة. تصنف الاستجابة على أنها كاملة (عندما يكون هناك اختفاء تام للآفات) ، لا استجابة عندما لا يكون هناك تغيير ، وجزئي (عندما يكون الانخفاض في حجم الثآليل 50٪ أو أكبر).

**النتائج:** شوهد استجابة كاملة في ٩٦ (٩١.٤٣٪) ، استجابة جزئية في ٤ (٣.٨١٪) ، وعدم استجابة في ٥ (٤.٧٦٪) من الثآليل. وكان معدل التخلص التراكمي بعد جلسات العلاج الأولى والثانية والثالثة ٦٠٪ ، ٨٠٪ ، و ٩١.٤٣٪ على التوالي، في نهاية المتابعة، كان معدل الانتكاس ٢.٠٨٪. كانت الآثار الجانبية خفيفة بشكل عام ولم تمنع النشاط الطبيعي.

**الاستنتاج:** يبدو أن ليزر النادميوم / النابض الطويل ذو الطول الموجي ١٠٦٤ نانومتر فعال وآمن لعلاج داء الثآليل الشائع.

**التوصيات:** توصي الدراسة بما يلي:

١. ادخال عدد اكبر من المرضى .
٢. عمل دراسة مقارنة بين هذا النوع من الليزر واستعمال علاج تقليدي لداء الثآليل.

### ABSTRACT:

**Background:** Verruca vulgaris is a common dermatological problem. The conventional treatments for verruca vulgaris are usually invasive, low efficacy, and need a long recovery period.

**Aims of study:** evaluate the effectiveness and the safety of long pulsed Nd:YAG laser in the treatment of verruca vulgaris.

**Methodology:** In this therapeutic clinical trial, thirty five patients with a total of 105 lesions were enrolled. Each patient was eligible for up to three treatment sessions at 2 weeks interval with long pulsed Nd:YAG laser. All verrucae were evaluated before every session and three months after the last treatment session. The response classifies as complete (when there is complete disappearance of lesions), no response when there was no change, and partial (when the reduction in verruca size 50% or greater).

**Results:** complete response was seen in 96 (91.43%), partial response in 4 (3.81%), and no response in 5 (4.76%) verruca. The cumulative clearance rate after first, second, third treatment sessions was 60%, 80%, and 91.43 % respectively. At end of follow up, relapse rate was 2.08%. Side effects were generally mild and did not prevent normal activity.

**Conclusion:** long pulsed Nd:YAG laser (1064nm) appears to be effective and safe for treatment of verruca vulgaris.

### Recommendations:

1. Increase the sample size.
2. Make comparative study with other traditional treatment modality for verruca vulgaris.

**Keywords:** wart, Nd:YAG, laser, Verruca, 1064 nm.

\* MD. Iraq, Najaf, Department of Dermatology, Faculty of Medicine, University of Kufa,

Email: [haidera.alsabak@uokufa.edu.iq](mailto:haidera.alsabak@uokufa.edu.iq)

\*\* MD. Iraq, Najaf, Department of Dermatology, Faculty of Medicine, University of Kufa,

Email: [muhsin.aldhalimi@uokufa.edu.iq](mailto:muhsin.aldhalimi@uokufa.edu.iq)

\*\*\* F.I.C.M.S. Iraq, Babylon, Department of Dermatology, Faculty of Medicine, university of Babylon,

Email: [widabas2015@gmail.com](mailto:widabas2015@gmail.com)

### INTRODUCTION:

Warts are a benign proliferation of skin and mucosa that result from infection with human papillomavirus (HPVs). These viruses do not produce acute signs or symptoms but induce slow growing lesion that can remain subclinical for a long time, a subset of HPVs has been associated with the development of epithelial malignancy<sup>(1)</sup>.

Warts occur at any age but unusual in infancy and early childhood. The incidence increases in the school years to reach a peak between the age of 12 and 16 years then declines sharply to the age of 20 and more gradually thereafter <sup>(2,3)</sup>. HPV members of genus family papovaviruses, which are double stranded DNA viruses replicate inside the nucleus. Because they contain no envelope, they are resistant to drying, freezing, and solvents <sup>(4)</sup>.

Transmission of warts occurs from direct person-to-person contact or indirectly by fomites <sup>(5)</sup>. Cell mediated immunity appears to be the principle mechanism for the rejection of warts <sup>(6)</sup>. Common warts occur largely between the age of 5 and 20 years and only 15% occur after the age of 35 <sup>(7)</sup>. They usually occur on the hands but are also often on the face and genitalia, or in other sites prone to trauma such as the knees or elbows, but they may occur anywhere on the skin surface, on the hands they favor the fingers and palm, periungual warts are common on nail biter <sup>(8)</sup>.

Lesions range in size from pinpoint to more than 1 cm, most averaging about 5 mm. They grow in size for weeks to months and usually present as elevated, rounded papules with a rough, grayish surface, which is so characteristic that it has given us the word “verrucous,” used to describe lesions with similar surface character (e.g., seborrheic keratosis) <sup>(1)</sup>. Modalities of treatment of common warts include topical, intralesional, systemic and surgical treatment <sup>(9, 10)</sup>. No treatment modality is uniformly effective for all cases of viral warts or directly antiviral <sup>(7)</sup>.

Lasers can be an effective treatment option for both simple and recalcitrant warts <sup>(11)</sup>. The most commonly used laser modalities for removal of wart consist of invasive lasers such as carbon dioxide and Er:YAG lasers, which ablate the warts layer by layer from the epidermis and the noninvasive lasers such as PDL and Nd:YAG lasers <sup>(1,12)</sup>.

Verruca vulgaris is caused by the human papillomavirus, which induces epidermal hyperplasia and neovascularization in affected skin. The use of non-ablative lasers is said to be based on the principle of targeting their vascular component which is evident histologically as dilated blood vessels in the dermal papillae <sup>(8, 13)</sup>.

The studies showed that CO<sub>2</sub>, PDL, Er:YAG and Nd:YAG are the most commonly studied laser modalities for wart treatment <sup>(14, 15)</sup>.

The Nd:YAG laser’s principal emission wavelength is at 1064 nm, still in the infrared range. The proposed mechanism of action for Nd:YAG laser has been coagulation and destruction of blood vessels in the papillary dermis of warts, so the target chromophore is hemoglobin <sup>(11)</sup>. Also, hyperthermic treatment with this laser has been reported to cause remission with no recurrence in several case reports and case series <sup>(8, 11)</sup>.

## **AIMS OF STUDY**

Evaluate the effectiveness and the safety of long pulsed Nd:YAG laser in the treatment of verruca vulgaris.

## **METHODOLOGY**

This study was carried out in the Laser Research Unit, College of Medicine / university of Kufa during the period from October 2016 to October 2017. The ethical approval was obtained from the Scientific Council of Dermatology and Venereology- Iraqi Board for Medical Specializations.

This is a therapeutic clinical trial study for the evaluation of effectiveness and safety of long pulsed Nd:YAG laser in treatment of verruca vulgaris in Iraqi patients.

Forty two patients (21 males and 21 females) with single or multiple verrucae were included in this study; Thirty five patients (17 males and 18 females) with a total of 105 verruca vulgaris lesions have completed the treatment. The age of the enrolled patients ranged between 4-45 years.

**Exclusion criteria were:**

1. Pregnant women.
2. Active infections and chronic or uncontrolled systemic disease (diabetes, heart/kidney/liver disease).
3. Children below 3 years.
4. Wart with secondary bacterial infection.
5. Immunocompromised patients (related to cancer, chemotherapy, systemic corticosteroid, transplant patients, etc.).
6. Patient with seizure disorders.
7. Patient who used other modalities of treatment in the last 1 month prior to the study.

At the initial visits, all patients and the parents of pediatric patients were interviewed and a full history was taken regarding the: name, age, sex, occupation, marital status, duration of disease, site of the lesion, number of the lesions; single versus multiple; whether the laser treatment is the first time treatment of the lesion or second type of treatment, response of the lesions to previous treatment. Family history of warts, past medical history (states of immune suppression, organ transplantation or any chronic diseases), drugs history especially for corticosteroids and other immune suppressants or any previous treatment modality received for their warts.

The careful physical examination was carried out to identify the site, size, and numbers of lesions. Color photographs for each patient were performed at the baseline before each treatment session and 3 months after the last session; photographs were taken using Sony-digital, high sensitivity, 9 megapixels, DSCHX1 full HD 1080 camera in the same place with fixed illumination and distance.

The procedure was fully described to the patients and the need for pre and post treatment photographs was explained to them. All patients signed a written informed consent about the nature of laser treatment, safety measures, possible side effects, and complications.

The areas of involved tissues were cleaned with povidone iodine solution 10% and topical anesthesia was offered as an option and was infiltrated locally with 2% xylocaine hydrochloride without adrenaline with the patient recumbent. However, it is not required by most subjects.

Subjects and clinicians wore protective goggles and masks during the treatments, and a smoke evacuator was used to remove any airborne viral particles. The study employed 1064-nm long-pulsed Nd:YAG laser (Quanta system - DNA laser technology – ULTRALIGHT, Milan, Italy). The following parameters were used: spot size, 5 mm; pulse duration, 20 msec; and fluence, 200 J/cm<sup>2</sup>. Each patient was eligible for up to three treatments session administrated at two week intervals. In each session, the affected area was treated by the laser for a minimum of three passes depending on the thickness of lesion with a 1-mm margin on the surrounding skin. The endpoint looked for was just mild visible erythema of the treated area. After treatment, povidone iodine was dapped over the verruca and finally, a dressing was applied. Patients were told to keep the dressing for 1 day only and then leave the treated area opened. Post-treatment care also includes a local antibiotic in the form of fusidic acid (2 % cream), twice daily. Analgesic in the form of paracetamol was prescribed if needed.

They were warned that it might be tender and might turn to black. At the next session, if there still verruca present, the area will prepared as before and further laser treatment was performed exactly as above. However, if there was no obvious verruca present and normal skin striations continued across the area previously occupied by the verruca, then the verruca was deemed gone. During the treatment period, examination of the lesions was carried out to monitor the size of treated lesions and to report the degree of resolution.

All verrucae were measured before each treatment session and at three months after the final treatment session to assess the response to treatment; the response was considered as:

- 1- Complete response when there is complete disappearance of the lesion
- 2- Partial response which was defined as equal or > 50% of verruca size.
- 3- Poor response when the there is less than 50% of verruca size.
- 4- No response when there was any change in verruca size.

At the end of follow up period, patients were asked about the degree of pain and relapse of any treated lesion. Any complications or side effects of laser treatment were recorded.

Statistical analysis was done by using SPSS(statistical package for social sciences) version 20 In which we use mean with standard deviation and number with percentage as descriptive statistics. For analysis, we used chi square test for categorical data. P value  $\leq 0.05$  regarded significant.

## RESULTS:

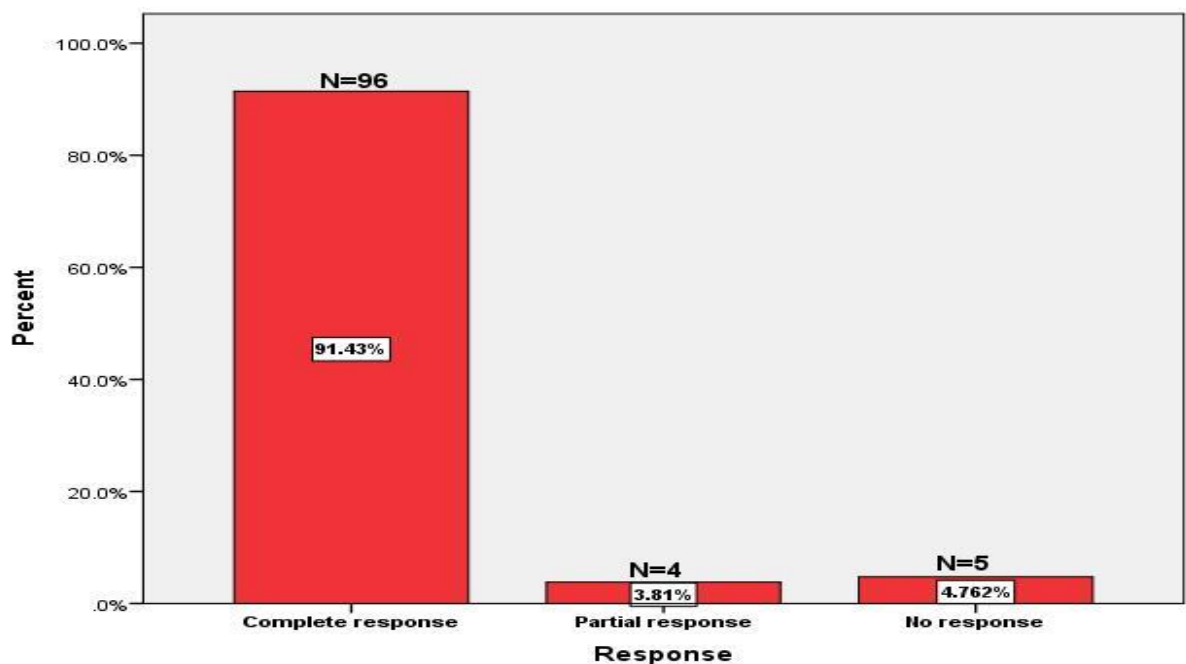
A total of 35 patients with common wart had been completed the study. Seven patients defaulted; because the treatment interfered with their work.

(Table 1): Basic characteristics of subjects included in the study (n=35).

|               | Mean±SD     | Range |
|---------------|-------------|-------|
| Age/years     | 22.85±12.76 | 4-45  |
| Duration/mont | 8.40±5.12   | 2-24  |

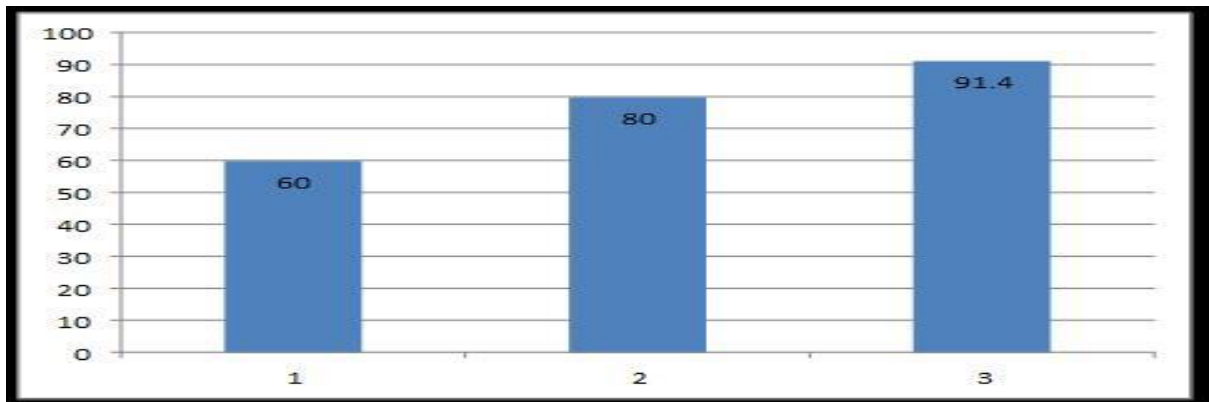
There were 17 male (48.58%) and 18 female (51.43%). Their ages ranged from 5-45 year with a mean  $\pm$  SD of 22.85±12.76. The mean duration of the lesions was 8.40±5.12 months. The number of the lesions treated was 105 wart lesions. The lesions were distributed mainly on the upper and lower extremities. The average number of treatment sessions required for clearance was varied from 1-3 sessions.

**Figure (1):** the response rate of verrucous vulgaris after treatment with long pulse Nd:YAG laser 1064 nm.



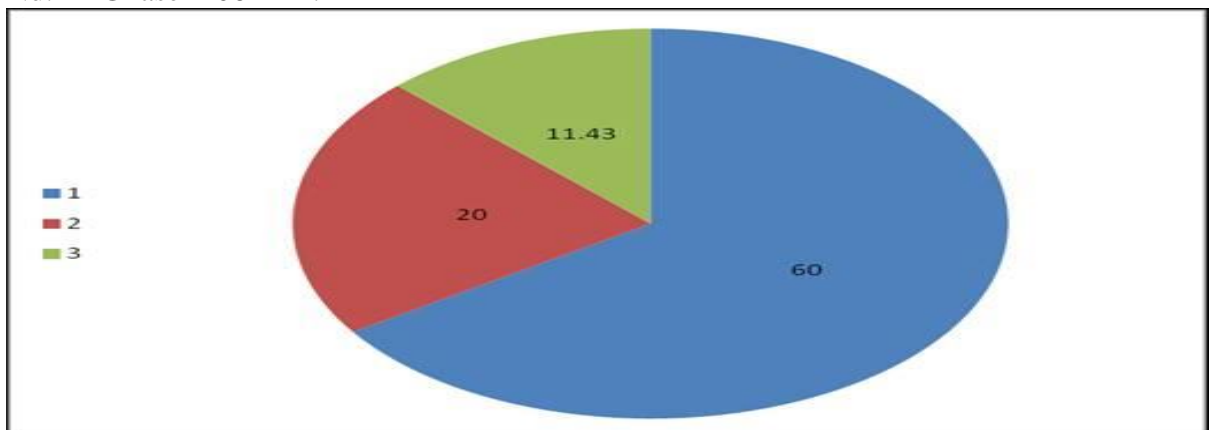
A complete response was seen in 96 (91.43%) verrucae. A partial response was seen in 4 (3.81%) verrucae. Poor response was zero. No response was seen in 5 (4.76%) verruca

**Figure (2):** cumulative clearance rate at 1st, 2nd, and 3rd session following the treatment with long pulse Nd:YAG laser 1064 nm.



The cumulative clearance rate after first, second and third treatment session was 60 %, 80%, and 91.43 % respectively

**Figure (3):** Clearance rates in the 1st, 2nd, and 3rd treatment session with long pulse Nd:YAG laser 1064 nm.



The clearance rate after the first treatment session was seen in 63 (60%) lesions, and after the second session was seen in 21(20%) lesions, and after the third treatment session was seen in 12 (11.43%) lesions.

**Table (2):** Association between the responses of verrucous vulgaris to long pulse Nd:YAG laser 1064 nm and previous history of other treatment options.

|          |                        | Treatment before |             | Total         | P value |
|----------|------------------------|------------------|-------------|---------------|---------|
|          |                        | No               | Yes         |               |         |
| Response | Complete response      | 35<br>87.5%      | 61<br>93.8% | 96<br>91.4%   | 0.259   |
|          | Partial or no response | 5<br>12.5%       | 4<br>6.2%   | 9<br>8.6%     |         |
| Total    |                        | 40<br>100%       | 65<br>61.9% | 105<br>100.0% |         |

In regarding of the association between the responses of verrucous vulgaris to long pulse Nd:YAG laser 1064 nm and previous history of other treatment options (local acid application and electrocautery), the differences appear to be not statistically significant (p value=0.259)

**Table (3):** comparison in duration of lesions between responded & not responded lesion

| Duration/ month | Complete response no. (96) |      | No or partial (9) response |      | P value |
|-----------------|----------------------------|------|----------------------------|------|---------|
|                 | Mean                       | SD   | Mean                       | SD   |         |
|                 | 8.36                       | 5.39 | 8.60                       | 3.57 |         |

Regarding the duration of disease, the mean of duration  $\pm$ SD of the lesions with full response (8.36 months $\pm$  5.39) and the mean of duration  $\pm$ SD of the lesions with no response (8.60months  $\pm$  3.57), the P-value was 0.927 which is statistically insignificant. This implies that the duration of the disease has no role on the response of the lesions to treatment with long pulsed ND: YAG laser.

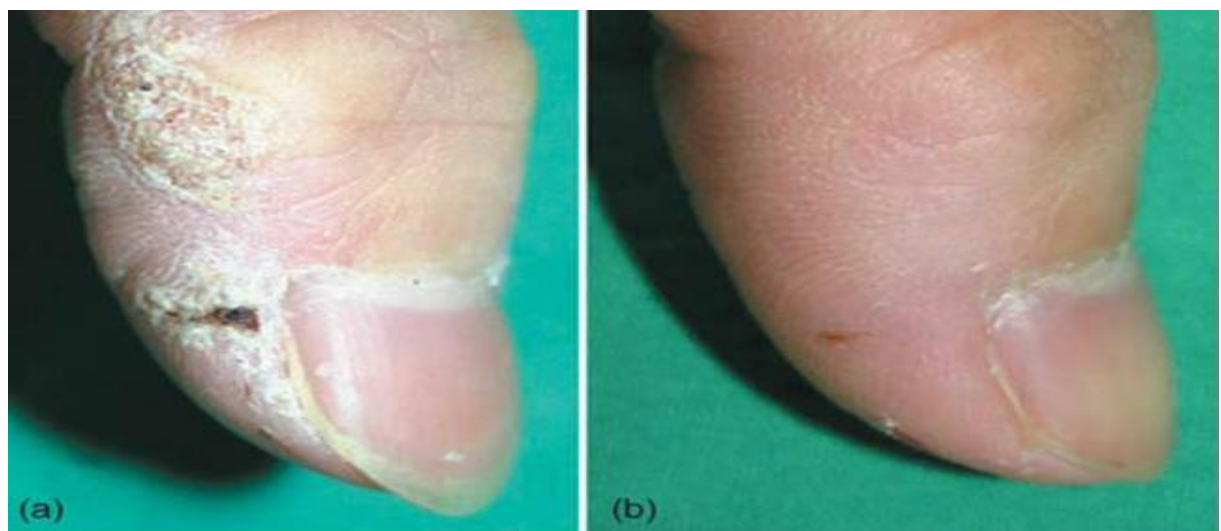
**Table (4):** Associations between size of lesion and response to long pulse Nd:YAG

| Response          | Size of lesion mm |              | Total         | P value |
|-------------------|-------------------|--------------|---------------|---------|
|                   | $\leq 5$ mm       | $> 5$ mm     |               |         |
| Complete Response | 48                | 48           | <b>96</b>     | 0.909   |
|                   | 50.0%             | 50.0%        | <b>100.0%</b> |         |
| Partial response  | 2                 | 2            | <b>4</b>      |         |
|                   | 50.0%             | 50.0%        | <b>100.0%</b> |         |
| No response       | 2                 | 3            | <b>5</b>      |         |
|                   | 40.0%             | 60.0%        | <b>100.0%</b> |         |
| Total             | <b>52</b>         | <b>53</b>    | <b>105</b>    |         |
|                   | <b>49.5%</b>      | <b>50.5%</b> | <b>100.0%</b> |         |

laser 1064 nm.

The associations between the size of the wart and the response to long pulse Nd:YAG laser 1064 nm, whether complete or partial or no response, was statistically non-significant (P-value0.909)

**Figure (4):** Twenty five years old female with warts on the thumb (A) before treatment and (B) 3 months following treatment with long pulse Nd:YAG laser.





The associations between the size of the wart and the response to long pulse Nd:YAG laser 1064 nm, whether complete or partial or no response, was statistically non-significant (P-value0.909)

**Table (5):** Association between site of lesions and response rate to long pulse Nd:YAG laser 1064 nm.

| Site                                       | Complete response | Partial response | No response |
|--|-------------------|------------------|-------------|
| <b>Fingers &amp; hand</b>                  | 38 (95%)          | 1 (2.5%)         | 1 (2.5%)    |
| <b>Palm</b>                                | 20 (90%)          | 0                | 2 (10%)     |
| <b>Periungual</b>                          | 16 (80%)          | 2 (10%)          | 2 (10%)     |
| <b>Dorsal surface of feet</b>              | 13 (92%)          | 1 (7.14)         | 0           |
| <b>Other site: forearm, arm thigh, leg</b> | 10 (100%)         | 0                | 0           |

Regarding the site of lesions, periungual warts showing the lowest cure rate of 80 %. While those on arm; forearm; leg; thighs showing the best cure rate of 100 %. The cure rate on the hand and dorsal surface of the foot were comparable.

At the end of the 3 months of follow up, only 2 (2.08%) lesions which were completely cleared lesions showed recurrence.

The side effects were generally mild and did not prevent normal activity, which include transient pain during treatment was experienced in 10 (28.6%) patients; numbness post treatment was experienced in 3 (8.6%) patients; hemorrhagic bulla in the treated areas was apparent in 21(20%) lesions; hyperpigmentation was noted in 9 (8.6%) lesions which was transient and disappears at the end of follow up; hypopigmentation in 6 (5.7%) lesions, no scar and no nail dystrophy.

## DISCUSSION:

Viral warts are a common dermatological disease. They are lesions of the skin and mucosa caused by HPV, can appear anywhere on the body with a usual incubation period of 1–6 months <sup>(1)</sup>.

In this present study, 35 Iraqi patients (17males and18 females) with a total of 105 verrucae vulgaris were treated with long pulsed Nd:YAG laser (1064nm, 5mm spot size, 200J/ cm<sup>2</sup> fluence, and 20ms pulsed duration) for their common wart to evaluate its effectiveness and safety.

The result from this study shows that long pulsed Nd:YAG laser lead to a complete response in 96 verruca (91.4%).

The largest series of warts treated with Nd:YAG laser was reported by Han et al <sup>(16)</sup>. The following parameters were used: spot size, 5mm; pulsed duration, 20msec; and fluence, 200J/cm<sup>2</sup> . Their overall success rate in 369 patients was 96%. They also reported that after the first, second, third, and fourth treatment sessions the clearance rate was 65%, 83%, 92%, and 96%, respectively. The clearance rate after the first treatment was also higher in the verruca vulgaris group (72.6%) than 64.7% in the periungual warts group and 44.1% in the deep palmoplantar warts group.

In periungual and deep palmoplantar warts, the reported success rate was lower than that for other body areas. They also reported that after the first, second, third, and fourth treatment sessions the clearance rate for verruca vulgaris was72.6 %, 90%, 96.6%, and 99.6%, respectively. Side effect included transient numbness (15%), hemorrhagic bulla (7%), hyperpigmentation (5%), and hypopigmentation (4%), 2% of patients with periungual warts experienced nail dystrophy.

The present study is in accordance with Han et al study, the present study shows that overall response rate was 91.4 %, and also show that after the first, second and third treatment

sessions the clearance rate was 60%,80%,and91.4%, respectively. Side effect included transient numbness (8.6%), hemorrhagic bullae (21%), hyperpigmentation (8.6%), and hypopigmentation (5.7%), no nail dystrophy, so in this present study, these results show less percentage of clearance rate and different side effect this may be due to small sample size, fewer sessions.

Kimura et al.<sup>(17)</sup> recently reported a series of 20 patients with a total of 34 lesions. All the subjects suffered from refractory hand and foot warts despite conventional treatments for more than 6 months. The patients were administrated up to six sessions of treatment, at intervals of 4 weeks between sessions, with long pulsed Nd:YAG at a spot size of 5 mm, pulse duration of 15msec and fluence of 150–185 J/cm<sup>2</sup>.

Evaluation of the treatment results at 24 weeks after the initial treatment showed complete clearance was observed for 56% (19/34) of the lesions, with 80% (27/34) of the lesions showing at least moderate improvement ( $\geq 51\%$  improvement). During the study, no scarring, no pigmentary changes or serious adverse events were reported.

The present study showed higher complete clearance rate of 91.43 % ( 96/105) of the lesions and slightly more adverse effect. This may be attributed to the difference in parameters used, as Kimura at al used shorter pulse duration and lower fluence, and because the enrolled lesions only old and refractory that had failed to respond to conventional treatments while in the present study used lesions without previous treatment therapy and also lesions in which other modalities of treatment was used before.

David Goldberg et al<sup>(18)</sup>, 25 adult subjects with a total of 63 hand verrucae in a clinical trial were treated with a low energy (200mjoule) 1064nm Nd:YAG laser. Each subject was eligible for 3 treatments administered at monthly intervals. All verrucae were measured at 6 months after the final treatment. Results showed complete response was seen in 19 (76%) patients and in 41 (65%) verrucae and showed no complication.

Ugur Anil Bingol et al.<sup>(19)</sup> study included 51 patients who were treated for 146 recalcitrant hand warts using 1064 nm long-pulsed Nd:YAG laser as follows: spot size, 3 mm; pulse duration, 23 ms; fluence, 180–200 J/cm<sup>2</sup>, the laser treatment method is novel because each treated wart was aligned at the intersection point of the circles of 3 laser pulses per session. Results of this study, 88.35% were successfully treated with one session and 100% of those that required a second treatment session were treated successfully, based on the 12 month follow-up examination. Complications of this study were thin scars which observed in(11.64%), Hyperpigmentation was observed in (5.48%), hypopigmentation did not occur in any of the patients, and none of the patients had a recurrence at the 12-month post-treatment follow-up.in this present study, the present study achieved slightly less complete rate (91.4%)but in the present study showed no scar in any patient, this may be due to different parameter used ,also because overlapped triple circle pulse technique employed might have positively affected the success rate, the technique described here is facilitated delivery of maximum therapeutic laser energy to the core of the warts while delivering less, but sufficient energy to the periphery of the warts.

Other modalities of treatments other than laser had been used for treatment of wart in Iraqi patients with variable success rate, oral zinc sulphate(89%) cure rate<sup>(20)</sup>, BCG vaccine showed (39.7%)cure rate<sup>(21)</sup>, intralesional zinc sulphate showed high cure rate(98%) two weeks after the third injection<sup>(22)</sup>, but it is difficult to compare the efficacy of these studies from this present study as these studies differ in duration of treatment, number of sessions, parameters of patients and type of warts.

So this present study demonstrated that long pulsed ND:YAG laser (1064nm) is an effective and safe method to treat verruca vulgaris in Iraqi patients, as this is the first study done in Iraq using this type of laser in treatment of common warts, it is much easier than the daily application of keratolytic ,or caustic material with less side effect than like CO2 laser, cryotherapy or electrocautery with higher success rate.



## **CONCLUSION**

Long pulsed Nd:YAG laser (1064nm) appears to be effective and safe for treatment of verruca vulgaris.

## **RECOMMENDATIONS:**

1. Increase the sample size.
2. Make comparative study with other traditional treatment modality for verruca vulgaris.

## **REFERENCES:**

1. Robert Chalmers Jonathan Barker, Christopher Griffiths, Tanya Bleiker, Daniel Creamer: Rooks Textbook of Dermatology, John Wiley, 2016: 9th edition: 25.43-63.
2. Van Haalen FM, Bruggink SC, Gussekloo J, Assendelft WJ, Eekhof JA. Warts in primary schoolchildren: prevalence and relation with environmental factors. *Br J of Dermatology*. 2009 1; 161(1):148-52.
3. Bruggink SC, Eekhof JA, Egberts PF, van Blijswijk SC, Assendelft WJ, Gussekloo J. Natural course of cutaneous warts among primary school children: a prospective cohort study. *The Ann of Family Medicine*. 2013 Sep 1; 11(5):437-41.
4. Richard C, Reichman. Human Papilloma Virus Infections. In, Braunwald E, Isselbacher KJ, Petersdorf RG, Wilson JD. *Harrison's Principle of Medicine*.16th ed, Mc Graw-Hill Company, 2005: 169: 1056-8.
5. Stulberg DL, Hutchinson AG. Molluscum contagiosum and warts. *American family physician*. 2003; 67(6):1233-40.
6. Ladoyanni E, North J, Tan CY. Idiopathic CD4+ T-cell lymphocytopaenia associated with recalcitrant viral warts and squamous malignancy. *Acta Derm-Venereol*. 2007; 87(1):76-7.
7. James WD, Berger TG, Elison DM. Viral Diseases. In: *Andrew's Diseases of the skin, Clinical Dermatology*, 12th edition, Canada, WB Saunders Company: 2016: 19: 399-410.
8. Reinhard Kirnbauer and Petra Lenz. Human Papillomaviruses. In: Bolognia JL, Jorizzo JL, Julie V Schaffer (eds.). *Dermatology*, 3rd edition. Mosby Elsevier, 2012; 2, 79:1303-18.
9. Gibbs S, Harvey I, Sterling JC, Stark R. Local treatments for cutaneous warts. *Cochrane Database Syst Rev*. 2003; 3:CD001781.
10. Leman JA, Benton EC. Verrucas. Guidelines for management. *Am J Clin Dermatol* 2000; 1:143 -149
11. Nguyen J, Korta DZ, Chapman LW, Kelly KM. Laser treatment of nongenital verrucae: a systematic review. *JAMA dermatology*. 2016; 152(9):1025-34.
12. Wolff K, Goldsmith L, Katz S, Gilchrest B, Paller AS, Leffell D, Paller A. *Fitzpatrick's dermatology in general medicine* 8th edition, New York, McGraw-Hill Book Company: 2012; 196: 2421-2433.
13. Wu C, Langan S, Kilmurray M, Lawlor D, Watson R. Efficacy of pulsed-dye laser for viral warts--an internal audit. *Iri Med Journal*. 2003; 96(3):80-2.

- 14.** Aldhalimi MA. Carbon dioxide laser treatment of viral warts, a new approach: P02. 73. J Euro Acad Dermatol & Venereol. 2004; 18:237.
- 15.** Wollina U, Konrad H, Karamfilov T. Treatment of common warts and actinic keratoses by Er: YAG laser. J Cutan las therapy. 2001; 3(2):63-6.
- 16.** Han TY, Lee JH, Lee CK, Ahn JY, Seo SJ, and Hong CK. Long-pulsed Nd: YAG laser treatment of warts: report on a series of 369 cases. J Kor Med science. 2009; 24(5):889-93.
- 17.** Kimura U, Takeuchi K, Kinoshita A, Takamori K, Suga Y. Long-pulsed 1064nm neodymium: yttrium–aluminum–garnet laser treatment for refractory warts on hands and feet. The J Dermatol. 2014; 41(3):252-7.
- 18.** Goldberg DJ, Beckford AN, Mourin A. Verruca vulgaris: novel treatment with a 1064 nm Nd: YAG laser. J Cosmet Las Therapy. 2015; 17(2):116-9.
- 19.** Bingol UA, Cömert A, Cinar C. The overlapped triple circle pulse technique with Nd: YAG laser for refractory hand warts. Photomed and las surg. 2015; 33(6):338-42.
- 20.** Al-Gurairi FT, Al-Waiz MM, Sharquie KE. Oral zinc sulphate in the treatment of recalcitrant viral warts. Randomized placebo-controlled clinical trial. Br J Dermatol 2002; 146(3): 423-31.
- 21.** Sharquie KE, Al-Rawi JR, Al-Nuaimy AA, Radhy SH. Bacille Calmette-Guerin immunotherapy of viral warts. Saudi Med J. 2008; 29(4):589.
- 22.** Sharquie KE, AL-Nuaimy AA. Treatment of viral warts by intralesional injection of zinc sulphate. Ann of Saudi med 2002; 22: 26-8.