

# The relation of maxillary root apices and the maxillary sinus floor among patients with different skeletal patterns in Iraqi samples

Karrar Hameed Al-sultany, B. D. S<sup>(1)</sup>

Iman I. Al\_sheakli, B. D. S., M. SC.<sup>(2)</sup>

## ABSTRACT

**Background:** Understanding the morphological characteristics between the floor of the maxillary sinus and the tips of the maxillary posterior roots is crucial in orthodontics involving diagnosis and treatment planning. The aim of this study was to evaluate the distances from the maxillary posterior root apices to the inferior wall of the maxillary sinus, thickness and density of maxillary sinus floor using cone-beam computed tomography images and the relationships between roots and maxillary sinus according to gonial angle and skeletal pattern.

**Materials and methods:** Three-dimensional images of each root were checked, and the distances were measured along the true vertical axis from the apex of the root to the sinus floor, and the thickness and density of maxillary sinus floor in 60 patients (30 males, 30 female) aged 18 to 25 years. Evaluation of the differences between groups which classified to gonial angle and skeletal pattern which were done according to the comparison between the mean statistic tests.

**Results:** results showed that the density of floor of maxillary sinus at the first molar roots region in class III were significantly lower than class I and II, also the distance between the floor of maxillary sinus and both distobuccal and palatal roots of first molar were significantly lower in class I than other classes, while the thickness of maxillary sinus floor at the distobuccal root of first molar were significantly higher in class III than other classes. In gonial angle difference, the maxillary sinus floor density and distance to the maxillary posterior roots had no significant difference in all groups, while the thickness of maxillary sinus floor at distobuccal and palatal of second molar roots region were significantly higher in large gonial angle than small and normal angles.

**Conclusion:** subjects with class I skeletal pattern have small distance between the maxillary sinus floor and the maxillary posterior roots due to the pneumatization of maxillary sinus causing more difficult and time consuming orthodontic treatment.

**Keywords:** distance, thickness, and density of maxillary sinus floor, cone beam computed tomography. (Received: 12/9/2018; Accepted: 12/11/2018)

## INTRODUCTION

In adults, the maxillary sinus differs in its projection due to the presence of 'Hillocks' which are elevations in the surface of sinus floor that occur in 50 % of population when the floor projects among adjacent teeth or roots<sup>(1)</sup>. In these cases, the sinus floor thickness is clearly diminished. When the roots project into the sinus floor many complications occur involving oroantral fistulae or displacement of root into the sinus or cavity that usually happen after extractions of maxillary molars<sup>(2)</sup>.

The sinus floor is made by the alveolar process of maxilla and locate about 12.5 mm beneath the floor of the nasal cavity. Casually a delicate layer of mucous lining is the only detachment of the roots of teeth from the maxillary sinus<sup>(3)</sup>.

The occlusion is influenced by vertical relationship of the upper and lower jaws. The effect is more obvious at the gonial angle when

there is difference in the shape of the lower jaw. Whenever the gonial angle is high, the mandible prone to increase vertical dimension of the face, and in severe cases causes an anterior open bite. In contrast, the mandible with a low gonial angle prone to decrease vertical dimension of the face.

During movement of tooth in orthodontic field and placement of implant, some problems may occur caused by maxillary sinus. Intrusion of maxillary posterior teeth into the maxillary sinus may cause tipping and periapical root resorption histologically and even radiographically<sup>(4,5)</sup>. furthermore, the angled placement of microimplants has high risk of destroying the maxillary sinus<sup>(6)</sup>. Therefore, problems like sinus perforation, and the resorption of root during the intrusion of molar can be stopped by the recognition about the distance between the roots of maxillary posterior teeth to the floor of maxillary sinus.

The thickness of the bone layer of the sinus floor is reduced significantly due to the presence of the

(1) Master student

(2) Professor, Department of Orthodontics, College of Dentistry, University of Baghdad.

roots of the posterior maxillary teeth within the maxillary sinus floor (MSF). However, most roots that project into the sinus are normally covered by a delicate cortical layer on histologic sections, and the rates of real perforation are not more than 14% to 28%<sup>(7)</sup>.

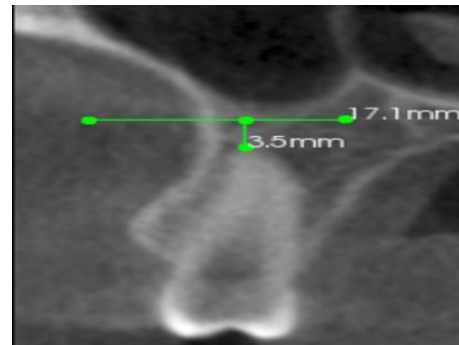
Bone density is defined as the amount of bone tissue in a specific volume of bone<sup>(8)</sup>. Many studies illustrate the importance of cone beam computerized tomography CBCT scans in the recognition of the topography of the maxillary sinus and its correlation with the tips of the maxillary posterior roots<sup>(9-11)</sup>. The advantages of CBCT are low radiation dose and easier technology than the other technologies<sup>(12)</sup>.

The aim of this study was to assess the relationships between maxillary posterior roots and maxillary sinus floor according to skeletal pattern, and gonial angle by using cone beam computed tomography images which include measuring the distances between maxillary posterior root apices and inferior wall of maxillary sinus, the cortical bone thickness and density of maxillary sinus floor in the region closest to the root apices and in the furcation areas.

## MATERIALS AND METHODS

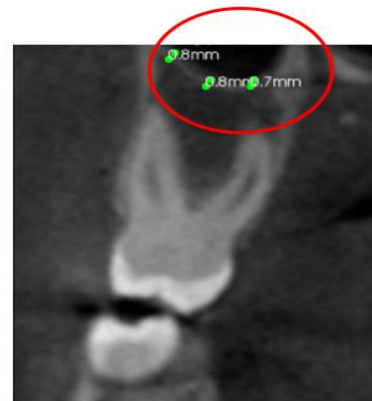This study composed of CBCT images has been taken in the Specialized Health Centre in Al-Sadr city / 3D radiographic department using Kodak 9500 Cone Beam 3D system machine that made in France (serial number: 420354AFXL057) with Carestream (CS) 3D Imaging software for patients who were attending from December 2017 till May 2018. From the 671 patients that included 436 females and 235 male aged from 15 years to 28 years that was sent for CBCT for the diagnosis of impacted third molars, impacted canine, and for orthodontic purposes, 60 Iraqi samples (30 males: 10 class I, 10 class II, 10 class III; and 30 females: 10 class I, 10 class II, 10 class III) ranged between 18-25 years chosen according to the stratified random sampling probability. An informed consent must be made for the subject to be part of the study of different skeletal pattern (class I, class II, and class III) that have been determined clinically by palpation with two-fingers method<sup>(13)</sup>. All patients were included except with these exclusion criteria which include: history of previous orthodontic treatment, missing posterior teeth (excluding the third molars), pathologic lesions or abnormalities of the maxillary sinus, radiographic signs of periapical disease, medical history. According to Foster<sup>(13)</sup> extra-orally, the assessment of the skeletal pattern clinically. On the CBCT images, the distances from the upper

posterior teeth root tips to the inferior wall of the floor of maxillary sinus were measured. The 3-dimensional (3D) measurements were done with Carestream (CS) 3D Imaging system software (KODAK dental imaging 9500 3D, France). Positive values were given to the distances that measured when there was no contact between the root and floor of the sinus (Figure 1), while negative values were given to the distances measured when the side of the root had contact with the sinus floor or the root penetrated into the maxillary sinus<sup>(14,15)</sup>.



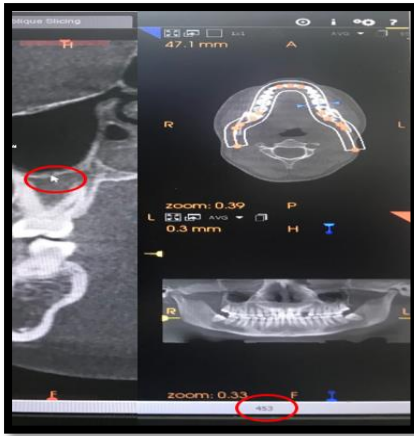**Figure 1: When the root had no contact with sinus floor, the distance was recorded as a positive value**

If the root apex is in contact or penetrate the maxillary sinus, the thickness is given value of 0.00 mm<sup>(14)</sup>. Measuring MSF cortical bone thickness in the region closest to the upper posterior root apices and in the furcation areas (Figure 2).



**Figure 2: The cortical thickness of the inferior wall of the maxillary sinus**

The density of the inferior wall of MSF was measured above the maxillary posterior root apices in both sides Above the root tip of second premolar, and above the furcation area for both first and second molars, the density of inferior wall of the sinus was measured by placing the mouse on three locations in MSF, and obtaining the mean of three readings that had been appeared on the lower right corner of screen (Figure 3).

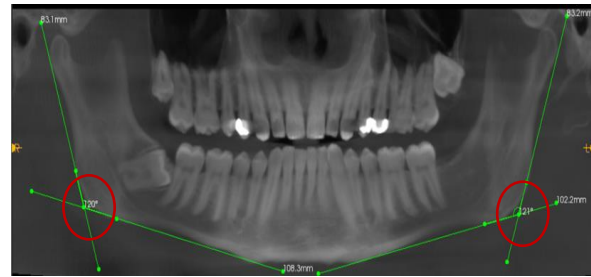


**Figure 3: Measurement of density**

The gonial angle can be measured from panoramic view and the location was determined from drawing two lines, a perpendicular line that touches the posterior border of ramus, and a horizontal line touches the mandibular inferior border. In order to impede rotation of the line, two points were determined contact each line. The angle was achieved from the meeting of the horizontal and vertical lines <sup>(16,17)</sup> (Figure 4). Okşayan et al. <sup>(17)</sup> confirmed that the values of gonial angle obtained from lateral cephalometry and orthopantomogram had no significant differences between Class I, II, and III malocclusion group. After measurements were done 3 groups obtained: large ( $\geq 132$ ), normal (119-131), and small ( $\leq 118$ ) gonial angle groups.

#### **Descriptive statistics and Class difference of the cortical bone thickness:**

The mean thickness of the sinus floor above root apices according to classes. The greatest thickness of inferior wall seen in class III above the



**Figure 4: Measurement of gonial angle on left and right side**

#### **RESULTS**

The sample include 60 subjects (30 males, and 30 females) was divided into 3 groups according to gonial angle: 14 samples with large ( $\geq 132$ ), 33 samples with normal (119-131), and 13 samples with small ( $\leq 118$ ) gonial angle groups. Also the sample divided according to skeletal pattern into 20 samples with Class I, 20 samples with Class II and 20 samples with Class III groups.

**Descriptive statistics and Class difference of the distance between floor of maxillary sinus and root apex of maxillary posterior teeth:** The longest distance between the sinus floor and root apices seen in class I with no protrusion at the second premolars (mean value, 0.580), and the more protruded roots into the sinus were the palatal roots of the first molars that found in class I (mean value, -4.075). Regarding the sagittal jaw relationship, the study showed a statistical significance at the distobuccal, and palatal roots of the first molars by using ANOVA test, then the difference in distances between class I and III in both roots found by using Tukey's test (Table 1)

furcation area of the first molar roots (mean value, 1.058), while the lowest thickness found in class I at the mesiobuccal root of the second molar teeth (mean value, 0). The Kruskal Wallis H Test showed statistical significance found at the distobuccal root of the first molar, and by using Mann Whitney test, the difference in thickness found between class I and III as in (Table 2).

**Table 1: Distances between the sinus floor and root tips on CBCT according to classes**

Roots	Classes	Descriptive Statistics		Classes difference			
		Mean	S.D.	F-test	p-value	ANOVA	
5	I	0.533	4.300	0.437	0.647		
	II	0.580	4.295				
	III	1.305	3.809				
6MB	I	-2.605	2.535	1.307	0.275	Tukey's HSD	
	II	-2.520	2.739			Classes	p-value
	III	-1.648	3.443				
6DB	I	-3.678	2.843	4.503	0.013*	I-II	0.233
	II	-2.558	2.683			I-III	0.009**
	III	-1.633	3.558			II-III	0.368
6P	I	-4.075	2.645	5.301	0.006**	I-II	0.083
	II	-2.575	3.232			I-III	0.005**
	III	-1.858	3.398			II-III	0.558
7MB	I	-3.623	2.361	2.843	0.062		
	II	-2.598	2.828				
	III	-2.308	2.564				
7DB	I	-2.625	2.516	2.543	0.083		
	II	-1.785	2.638				
	III	-1.393	2.328				
7P	I	-1.780	2.006	1.302	0.276		
	II	-1.210	3.004				
	III	-0.885	2.423				

Note: \* significant, \*\* highly significant; 5, Second premolar; 6, first molar; 7, second molar; DB, distobuccal; MB, mesiobuccal; P, palatal; d.f: 59.

**Table 2: Thickness (mm) of the sinus floor above root apices on CBCT according to classes**

Roots	Classes	Descriptive Statistics			Class difference				
		Median	Mean	S.D.	Kruskal Wallis H Test	p-value	classes	Mann-Whitney U test	P-value
5	I	0.55	0.660	0.716	0.625	0.731			
	II	0.55	0.598	0.601					
	III	0.9	0.723	0.643					
6MB	I	0	0.200	0.450	0.893	0.640			
	II	0	0.148	0.382					
	III	0	0.255	0.503					
6DB	I	0	0.045	0.204	6.221	0.045*	I-II	720.5	0.142
	II	0	0.133	0.322			I-III	639.5	0.013*
	III	0	0.233	0.439			II-III	718.5	0.262
6P	I	0	0.035	0.221	5.147	0.076			

	II	0	0.148	0.342		
	III	0	0.168	0.387		
	I	0.9	0.933	0.356		
6 Furcation	II	0.9	0.943	0.298	0.209	0.901
	III	0.9	1.058	1.009		
	I	0	0	0		
7MB	II	0	0.128	0.381	5.396	0.067
	III	0	0.110	0.304		
	I	0	0.135	0.454		
7DB	II	0	0.123	0.323	2.085	0.353
	III	0	0.225	0.486		
	I	0	0.135	0.379		
7P	II	0	0.255	0.442	2.573	0.276
	III	0	0.278	0.514		
	I	0.9	0.940	0.320		
7 Furcation	II	0.9	0.943	0.311	1.012	0.603
	III	0.9	1.003	0.290		

Note: \* significant; 5, Second premolar; 6, first molar; 7, second molar; DB, distobuccal; MB, mesiobuccal; P, palatal.

**Descriptive statistics and Class difference of the cortical bone density:**

The mean density of the sinus floor above root apices according to classes. The highest density of the sinus floor found in class I above the second premolar root (mean value, 671.700), while the

lowest density found in class III above the second molar root (mean value, 660.050). The ANOVA test showed statistical significant difference in density found at the first molar root, and by using Tukey’s HSD test, the difference in density found between class I and III, as well as between class II and III as in (Table 3).

**Table 3: Density of the sinus floor above root apices on CBCT according to classes**

Roots	Classes	Descriptive Statistics		Classes difference			
		Mean	S.D.	ANOVA			
				F-test	p-value		
5	I	671.700	144.715	0.072	0.931	Tukey's HSD	
	II	668.250	120.810			Classes	p-value
	III	660.050	155.381			I-II	0.993
6	I	570.450	91.608	3.206	0.044*	I-III	0.047*
	II	567.425	107.997			II-III	0.049*
	III	511.850	143.839				
7	I	520.950	117.687	1.824	0.166		
	II	547.500	110.302				
	III	492.475	154.242				

Note: \* significant; 5, Second premolar; 6, first molar; 7, second molar; DB, distobuccal; MB, mesiobuccal; P, palatal; d.f: 59



**Descriptive statistics and Gonial angle difference of the distance between floor of maxillary sinus and root apex of maxillary posterior teeth:**

The longest distance between sinus floor and root apices found in normal gonial angle patients with no protrusion at second

premolar roots (mean value, 1.172), while the more protruded roots into the sinus were the mesiobuccal roots of second molar that found in small gonial angle patients (mean value, -3.328). In general, no statistical significance difference in distance among different groups of gonial angle as in (Table 4).

**Table 4: Distances (mm) between root apices and the sinus floor on CBCT in different gonial angle groups**

Roots	Gonial angle	Descriptive Statistics			Comparison	
		N	Mean	S.D.	F-test	p-value
5	Low	18	-0.156	5.422	1.052	0.352
	Normal	82	1.172	3.850		
	High	20	0.170	3.873		
6MB	Low	18	-2.956	2.963	1.155	0.319
	Normal	82	-1.983	2.755		
	High	20	-2.755	3.585		
6DB	Low	18	-3.167	3.183	0.634	0.532
	Normal	82	-2.404	2.908		
	High	20	-3.030	4.001		
6P	Low	18	-3.022	3.533	0.107	0.898
	Normal	82	-2.743	2.936		
	High	20	-3.050	4.105		
7MB	Low	18	-3.328	2.606	0.401	0.671
	Normal	82	-2.718	2.524		
	High	20	-2.915	3.136		
7DB	Low	18	-3.011	2.060	2.346	0.100
	Normal	82	-1.851	2.390		
	High	20	-1.305	3.223		
7P	Low	18	-1.544	2.534	1.267	0.285
	Normal	82	-1.434	2.227		
	High	20	-0.480	3.460		

Note: 5, Second premolar; 6, first molar; 7, second molar; DB, distobuccal; MB, mesiobuccal; P, palatal; d.f: 59

**Descriptive statistics and Gonial angle difference of the cortical bone thickness:**

The mean thickness (mm) of the sinus floor above root apices according to gonial angle. The greatest thickness of inferior wall seen in large gonial angle at the furcation area of the second molar roots (mean value, 1.085), while the lowest thickness found in normal gonial angle at the mesiobuccal root of the second molar teeth (mean

value, 0.065). The Kruskal Wallis H Test showed a significance found at the distobuccal, and palatal root of the second molars. Through using Mann Whitney test, the difference in thickness in the distobuccal root of second molar found between small and large gonial angle, while in the palatal root of second molar, the difference found between normal and large gonial angle as in (Table 5).

**Table 5: Thickness of the sinus floor above root on CBCT according to gonial angle**

Roots	GA	Descriptive Statistics			Class difference		GA	Mann-Whitney U	p-value
		Median	Mean	S.D.	Kruskal Wallis H Test	p-value			
5	Low	0	0.578	0.753	3.086	0.214			
	Normal	0.9	0.722	0.632					
	High	0	0.480	0.625					
6MB	Low	0	0.156	0.458	1.067	0.587			
	Normal	0	0.222	0.457					
	High	0	0.155	0.401					
6DB	Low	0	0.228	0.447	1.074	0.584			
	Normal	0	0.124	0.334					
	High	0	0.105	0.263					
6P	Low	0	0.156	0.368	1.651	0.438			
	Normal	0	0.098	0.313					
	High	0	0.160	0.352					
6 Furcation	Low	1	1.022	0.349	2.161	0.340			
	Normal	0.85	0.985	0.746					
	High	0.85	0.905	0.258					
7MB	Low	0	0.100	0.424	1.297	0.523			
	Normal	0	0.065	0.243					
	High	0	0.120	0.305					
7DB	Low	0	0	0	8.105	0.017*	Low-Normal	630	0.086
	Normal	0	0.166	0.460			Low-High	117	0.006**
	High	0	0.285	0.438			Normal-High	668	0.059
7P	Low	0	0.189	0.403	9.131	0.010*	Low-Normal	703	0.639
	Normal	0	0.177	0.440			Low-High	129.5	0.088
	High	0.25	0.440	0.482			Normal-High	555.5	0.003**
7 Furcation	Low	0.8	0.922	0.308	2.592	0.274			
	Normal	0.9	0.940	0.282					
	High	1.05	1.085	0.379					

Note: \* significant, \*\* highly significant; 5, Second premolar; 6, first molar; 7, second molar; DB, distobuccal; MB, mesiobuccal; P, palatal.

**Descriptive statistics and Gonial angle difference of the cortical bone density:**

The mean density of the sinus floor above root apices according to gonial angle. The

highest density of the sinus floor found in normal gonial angle above the second premolar root (mean value, 673.793), while the lowest density found in small gonial angle above the second molar root (mean value, 476.222) show in (Table 6).

**Table 6: Density of the sinus floor above root apices on CBCT according to gonial angle**

Roots	Gonial angle	Descriptive Statistics			Comparison	
		N	Mean	S.D.	F-test	p-value
5	Low	18	661.889	163.913	0.430	0.652
	Normal	82	673.793	142.845		
	High	20	641.750	103.593		
6	Low	18	567.333	86.562	0.283	0.754
	Normal	82	548.805	120.949		
	High	20	538.750	136.841		
7	Low	18	476.222	141.452	1.622	0.202
	Normal	82	522.537	119.271		
	High	20	550.850	155.020		

Note: 5, Second premolar; 6, first molar; 7, second molar; DB, distobuccal; MB, mesiobuccal; P, palatal; d.f: 59

## DISCUSSION

The CBCT supplies accurate images with no distortion and overlapping of the nearby structures of the bone that surround root apices, so that CBCT has been used in diagnosis and treatment planning widely<sup>(15)</sup>.

### Distance:

This study showed a significant difference regarding the sagittal jaw relationship at the distobuccal, and palatal roots of the first molars.

All roots of patients with a small gonial angle showed a more protrusion into the sinus than normal and large gonial angle. This was not agreed with Ahn and Park<sup>(15)</sup>, who revealed that all roots of patients with a large gonial angle showed a significantly closer relationship to the sinus floor or more protrusion of the roots into the sinus than the roots of patients in the normal and small gonial angle groups. During the treatment of open-bite cases, intrusion of the maxillary molar teeth is required which is difficult, because of the close distance between the maxillary posterior root tips and the sinus floor<sup>(18)</sup>. Patients that have small gonial angle need light intrusion force in order to decrease resorption of root. Clinicians must pay attention when determining the amount and direction of the orthodontic forces during treatment<sup>(15)</sup>.

### Thickness:

According to class differences the smallest and greatest thickness of the MSF that had been found over the mesiobuccal root of second molar, and over the furcation of first molar apex, respectively. This study agreed with Estrela et al<sup>(14)</sup>, in which the smallest thickness had been found over the mesiobuccal root of second molar, but disagreed with Yoshmine<sup>(19)</sup> in both greatest and smallest thickness. Harrison<sup>(20)</sup> reported that the minimum thickness of inferior wall of the maxillary sinus found over the second molar root which was consistent with the present study,

while in the study of Kwak et al.<sup>(21)</sup> the cortical thickness over the distobuccal root of the second molar was the thinnest which disagreed with the results of this study obtained from class difference. The differences between these studies were because of the high thickness of MSF in this study found over the furcation area of both first and second molars in addition to other reasons as difference in methodology, number of subjects, and ethnicity.

A statistical significance had been found in second molar roots in gonial angle differences only. It is interesting to observe that the area of greatest distance between the root tips of maxillary posterior teeth and the MSF coincided with the area of the greatest thickness near to the apex (second premolars), and the area of lowest distance teeth and the MSF coincided with the lowest thickness near to the apex (second molars).

### Density:

The density of sinus floor was measured by placing the mouse on the MSF over the roots of second premolar, and above the furcation areas of both first and second molar roots, the value of the density appeared on the lower right corner of screen A statistical significance found in density over the furcation of first molar in which subject with class III had the lowest density of all classes. When observing the gonial angle difference, the greatest density of the floor of maxillary sinus was observed above the root apex of second premolar in subject with normal gonial angle with (mean value, 673.793). No statistical significance had been found in density over all the roots. There are no previous studies conducted the measurement of density of the MSF, so that, the results of this study cannot be compared with other studies.

## CONCLUSION

The more protruded root into the sinus floor were the mesiobuccal root apices of the second molars



and the palatal root apices of first molars, and the farthest from the floor of sinus were second premolar root apices. The greatest thickness of maxillary sinus floor found over the bifurcation area of both first and second molar roots, while the smallest thickness appeared over the mesiobuccal and distobuccal root apices of second molars. The greatest density of maxillary sinus floor found over the second premolar root apices and the smallest appeared over the furcation of second molar root apices. In class difference, the density of maxillary first molar in class III were significantly lower than class I and II, while the distance of both distobuccal and palatal roots of maxillary first molar and the thickness of distobuccal roots of maxillary first molar were significantly higher in class I, and class III, respectively than other classes. In gonial angle difference, the density and distance had no significant difference in all groups, while the thickness of distobuccal and palatal roots of maxillary second molar were significantly higher in large gonial angle than small and normal angles.

## REFERENCES

- Kosumarl W, Patanaporn V, Jotikasthira D, Janhom A. Distances from the root apices of posterior teeth to the maxillary sinus and mandibular canal in patients with skeletal open bite: A cone-beam computed tomography study. *Imaging Sci Dent* 2017 Sep; 47(3): 157-64.
- Mattar E, Hammad L, Faden A, Khalil H. Relation of maxillary teeth to the maxillary sinus in normal Saudi individuals living in Riyadh. *Biosciences, Biotechnology Research Asia* 2010; 7(2): 695-700.
- Singh V. *Textbook of anatomy: head, neck and brain*. 2nd ed. Elsevier: New Delhi; 2014. P. 259-64.
- Wehrbein H, Bauer W, Schneider B, Diedrich P. Experimental bodily tooth movement through the bony floor of the nose—a pilot study. *Fortschr Kieferorthop* 1990; 51: 271-6.
- Heravi F, Bayani S, Madani AS, Radvar M, Anbiaee N. Intrusion of supra-erupted molars using miniscrews: clinical success and root resorption. *Am J Orthod Dentofacial Orthop* 2011; 139(4): 170-5.
- Laursen MG, Melsen B, Cattaneo PM. An evaluation of insertion sites for mini-implants: a micro-CT study of human autopsy material. *Angle Orthod* 2013; 83: 222-9.
- Wehrbein H, Diedrich P. The initial morphological state in the basally pneumatized maxillary sinus—a radiological- histological study in man. *Fortschr Kieferorthop* 1992; 53: 254-62.
- Gulsahi A, Paksoy CS, Ozden S, Kucuk NO, Cebeci ARI, Genc Y. Assessment of bone mineral density in the jaws and its relationship to radiomorphometric indices. *Dentomaxillofacial Radiology* 2010; 39: 284-9.
- Eberhardt J, Torabinejad M, Christiansen E. A computed tomographic study of the distances between the maxillary sinus floor and the apices of the maxillary posterior teeth. *Oral Surg Oral Med Oral Pathol* 1992; 73: 345-6.
- Koymen, R; Gocmen-Mas, N; Karacayli, U; Ortakoglu, K; Ozen, T; Yazici, AC. Anatomic evaluation of maxillary sinus septa: surgery and radiology. *Clinical Anatomy* 2009; 22: 563-70.
- Lemagner F, Maret D, Peters OA, Arias A, Coudrais E, Georgelin-Gurgel M. Prevalence of apical bone defects and evaluation of associated factors detected with cone-beam computed tomographic images. *J Endod* 2015; 41: 1043-7.
- White S, Pharoah M. *Oral Radiology principles and interpretation*. 6th ed.: Mosby: St Louis; 2009. P. 597-610.
- Foster TD. *A textbook of orthodontics*. 3rd ed. Blackwell Scientific Publications: Oxford London; 1990. P. 76-84.
- Estrela C, Nunes CA, Guedes OA, Alencar AH, Estrela CR, Silva RG, Pécora JD, Sousa-Neto MD. Study of anatomical relationship between posterior teeth and maxillary sinus floor in a subpopulation of the brazilian central region using cone-beam computed tomography - part 2. *Braz Dent J* 2016; 27(1): 9-15.
- Ahn NL, Park HS. Differences in distances between maxillary posterior root apices and the sinus floor according to skeletal pattern. *Am J Orthod Dentofacial Orthop* 2017; 152(6): 811-9.
- Mahl CRW, Licks R, Fontanella VRC. Comparison of morphometric indices obtained from dental panoramic radiography for identifying individuals with osteoporosis/osteopenia. *Radiol Bras*. 2008; 41(3): 183-7.
- Okşayan R, Aktan AM, Sökücü O, Haştar E, Ciftci ME. Does the Panoramic Radiography Have the Power to Identify the Gonial Angle in Orthodontics? *The Scientific World Journal* 2012; 2012:219708.
- Hart TR, Cousley RR, Fishman LS, Tallents RH. Dentoskeletal changes following mini-implant molar intrusion in anterior open bite patients. *Angle Orthod* 2015; 85: 941-8.
- Yoshimine, S; Nishihara, K; Nozoe, E; Yoshimine, M; Nakamura, N. Topographic analysis of maxillary premolars and molars and maxillary sinus using cone beam computed tomography. *Implant Dentistry* 2012; 21: 528-35.
- Harrison DFN. Surgical anatomy of maxillary and ethmoidal sinuses—a reappraisal. *Laryngoscope* 1971; 81: 1658- 64.
- Kwak HH, Park HD, Yoon HR, Kang MK, Koh KS, Kim HJ. Topographic anatomy of the inferior wall of the maxillary sinus in Koreans. *Int J Oral Maxillofac Surg* 2004; 33: 382-8.

**الخلاصة:**

**الخلفية:** إن فهم الخصائص المورفولوجية بين أرضية الجيب الفكي وقمم الجذور الخلفية العلوية له أهمية بالغة في تقويم الأسنان التي تشمل التشخيص وتخطيط العلاج. كان الهدف من هذه الدراسة هو تقييم المسافات من قمم الجذر الخلفي للفك العلوي إلى الجدار السفلي لجيب الفك العلوي وسمك وكثافة أرضية الجيوب الفكية باستخدام صور التصوير المقطعي المخروطي والعلاقات بين جذور الفك العلوي وجيب الفك العلوي وفقاً لزاوية الفك الأسفل ونمط الهيكل العظمي.

**مواد وطرق البحث:** تم فحص صور ثلاثية الأبعاد لكل جذر، وتم قياس المسافات على طول المحور الرأسي الحقيقي من قمة الجذر إلى أرضية الجيوب، وسمك وكثافة أرضية الجيب الفكي في 60 مريضاً (30 ذكور، 30 أنثى) تتراوح أعمارهم بين 18 و25 سنة. تم إجراء تقييم للاختلافات بين المجموعات التي صنفت حسب زاوية الفك الأسفل ونمط الهيكل العظمي وفقاً للترابط بين الاختبارات الإحصائية المتوسطة.

**النتائج:** أظهرت النتائج أن كثافة الضرس الأول في النمط الهيكلي الثالث أقل بكثير من النمط الهيكلي الأول والثاني، في حين كانت المسافة في كلا الجذور البعيدة الوجنية وجذور أعلى باطن الفم من الأضراس الأولى وسمك الجذور البعيدة الوجنية من الضرس الأول أعلى بشكل ملحوظ في الأنماط الهيكلية الأولى والثانية على التوالي من الأنماط الأخرى. الكثافة والمسافة لم تختلف بشكل ملحوظ في كل المجموعات. بينما سمك الجذور البعيدة الوجنية وجذور أعلى باطن الفم للأضراس الثانية كانت أعلى بشكل ملحوظ في زاوية الفك الأسفل الكبيرة من الزوايا الصغيرة والعادية.

**الاستنتاج:** أدخلت أضراس الفك العلوي في حالة وجود مسافات صغيرة بين قمم الجذور وأرضية الجيب يمكن أن يكون صعباً وبطيئاً بسبب تغلغل الجيوب الأنفية الفكية.