

DIRECT EFFECT OF RED LASER IRRADIATION ON TESTICULAR AND EPIDIDYMIS TISSUE FUNCTION IN MALE RABBITS

Ihsan Ali Habeb^{*}, Zainab Waheed^{**}, Mosa F. Abbas^{***}

^{***} ^{*} Department of Surgery and Obstetrics, College of Veterinary Medicine, University of Basrah, Basrah, Iraq

^{**} Department of Pathology, College of Veterinary Medicine, University of Basrah, Basrah, Iraq

(Received 9 December 2018, Accepted 31 December 2018)

Keywords: Red laser, Testicular tissue, Epididymis.

Corresponding Author: ihsan.ali.habeb@gmail.com

ABSTRACT

This study was designed to evaluate the effect of red laser irradiation on testicular and epididymis tissue. Twenty rabbits, male mature were used in the present study. The animals were divided in to four groups. First group as control and second, third and fourth groups exposed to red laser irradiation 5 min, 15 min, 30 min respectively. Histological sample were taken after necropsy method of all experimental animals for preparation slide processes to examine under light microscope. The result of experiment showed histological changes induced by exposure the animals to red laser (650nm-10w) which present as versus changes and these pathological changes is directly fit with period of exposure which appear as degeneration, oedematous, hyperemia and necrosis in to testicular and epididymis.

INTRODUCTION

Laser has many biomedical applications since it can be used in medical fields, in bio-stimulation of various organs, at low energy level in speeding up the wound healing process. It has the ability to stimulate the formation of epithelial cells and reduces the inflammatory phase during the healing process (1). A green semiconductor diode laser is a one laser used in many purposes, recently was used in medical surgery; there wave length between (450nm -632nm) with different energy (1-1000 watt) (2). Some green

laser irradiated on platelet activation and glycoprotein (3). Other researchers were used double beam green laser in renal surgery in some cases (4). While oncologists were used double beam green laser (532nm) to treat skin cancer and cosmetic medicine (5).

Rabbits are easy to handle. These advantages permit longitudinal evaluation of sperm production, semen morphology and biochemistry, and longitudinal fertility testing with known numbers of diluted spermatozoa, and often introduced into studies before they reach sexual maturity(6). This may be an advantage if the maximum susceptibility to a test compound is desired. The spermatogonia start to divide at 7 to 8 weeks of age, the blood-testis barrier forms by 10 weeks of age, the testes descend and the tubules develop lumina at 12 weeks of age. Spermatids and spermatocytes are first seen at 14 to 15 weeks of age, tubules appear histologically mature by 18 weeks of age, the testes continue to grow and increase sperm production until 6 months of age. Strain-related variation in the time required for maturation of the testis has been reported. In the rabbit, eight cellular associations of developing male gametes are recognized in histologic sections of seminiferous tubules (7). These eight associations make up the spermatogenic cycle. The length of the cycle of the seminiferous epithelium lasts 10.7 days in the rabbit. Approximately 48 days or 4.5 cycles are required for a committed type A spermatogonium to differentiate into mature spermatozoa that are released into the lumen of the seminiferous tubule (8). An additional 10 to 14 days (1 to 1.5 cycles) are required for the spermatozoa to pass through the epididymis into the ejaculate. The work aimed to evaluate the effect of laser irradiation on testicular and epididymis tissue function in male rabbits.

MATERIALS AND METHODS

This study was conducted at Basra University - College of Veterinary Medicine, Department of Surgery and Obstetrics. In the present study, twenty male rabbits, 7±3 month's old, reared at similar condition at 27±5°C, and their food was green grass and dried bread.

The male rabbits were kept in cages for 10 days prior to the beginning of the experiment for adaptation and randomly divided into four groups. First group included five animals as a control. The second group included (5) animals exposed to red laser radiation for five minutes daily for 30 days. The third group was exposed to red laser

radiation for 15 minutes daily for 30 days. The four group was exposed to red laser radiation for 30 min daily for 30 days. Sample of testicular tissue were collected for

histopathological examination. Histological biopsies were kept in neutral formalin solution. According to (9), the formalin fixed samples were processed, sectioned, and stained. The procedure was carried out in the laboratory of Histopathology, Department of Pathology, College of Veterinary Medicine, University of Basra. The thickness of the microtome sections ranged from 4 micrometers. The prepared slides were their stained with Hematoxylin and Eosine stain. In this experiment, red lasers were used on the testes and epididymis their effect on the structures of the tissues of the male rabbits with it time.

RESULTS

The present study, which were designed on four groups and each group of five animals after exposure to the red laser, showed fixed times and variable periods.

Control group

Their animals did not exposed to red laser radiation, along exposure time considerable as control group then animals were sacrificed and testes were taken and epididymis organs from pelvic cavity, slides prepared from testes and epididymis shows normal histological structures (Figure 1, 2).

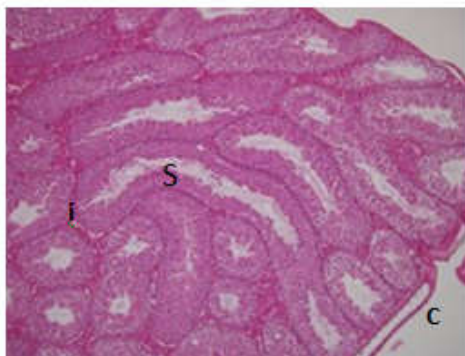


Fig. (1): Section of normal testicular tissue, seminiferous tubules (s) and interstitial tissue (i) with slightly thick of capsule (c).
H&E ×10.

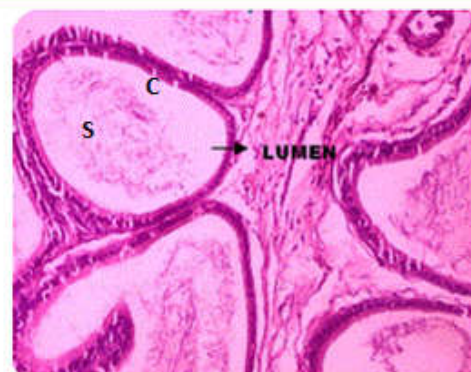

Fig. (2): Section of normal epididymis tissue showing tubules with ciliated cuboidal cells(c) and the lumen full with sperm(s).

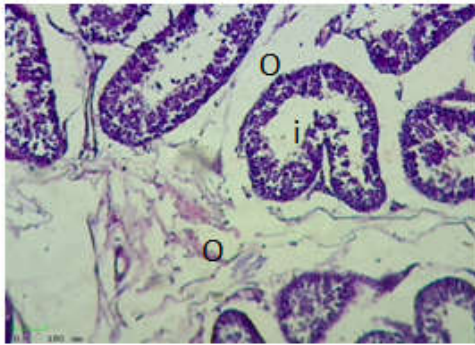


Fig.(3): Cross section of testicular tissue showing edema (o) and mild inhibition of spermatogenesis(i).

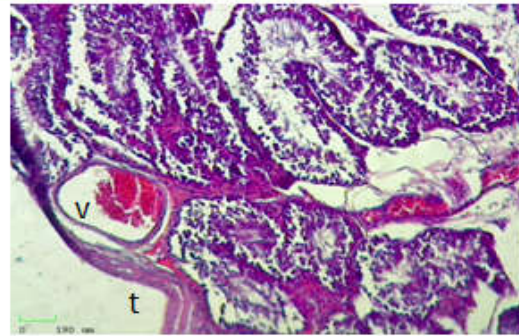


Fig.(4): Cross section of testes showing Congestion of blood vessels (v) with thickening capsule(t). H&E $\times 10$.

Second group

Animals of second group which was exposed to red laser radiation wave for 5 min showed suppression of spermatogenesis, were odema in interstitial space and decrease in lining cells (Figure 3), but under the capsule there are vacuolated seminiferous cells with congested blood vessels (Figure 4).In the epididymis, had irregular lumen of lining cells surrounded with fibrosis (Figure 5), and there are liquifactive necrosis of cells (Figure 6).

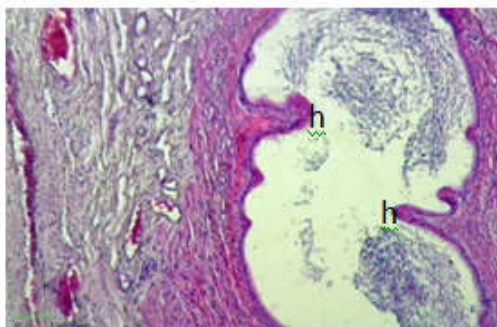


Fig.(5) : Section of epididymis of second group showing thickening of wall due to hyperplasia (h) of epithelial cells and excessive vacuolization of capillaries (H&E $\times 10$).

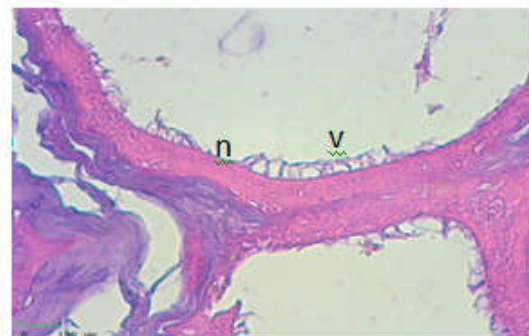

Fig. (6): Section of epididymis shows vacuolation (v) and necrosis of epithelial cells lining (n) (H&E $\times 40$).

Third group

The seminiferous tubules are irregular and some of them are atrophied with decreased connective tissue as well as leydig cells odema (Figure 7), but the epididymis had liquifactive necrosis (Figure 8).

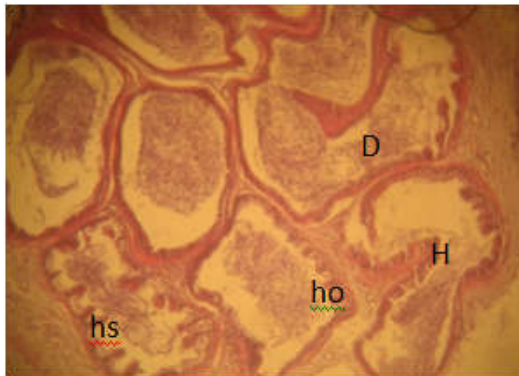

Figure (9): Showing histological changes in epididymis of male rabbit's; hyperplasia of epithelial cells (H) which lead to dilated (D) of some duct, hypoplasia of some other (ho), there are also papillary projection of hyperplastic cells of epithelial lining (hs) (H&E ×40).

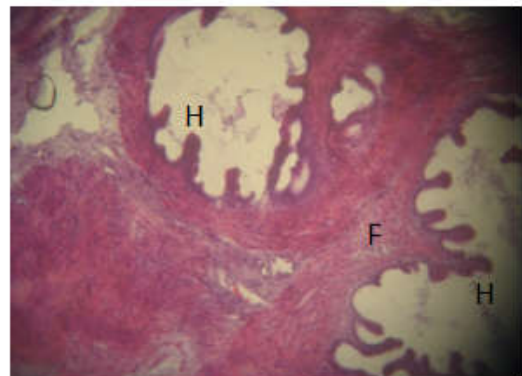


Figure (10): Showing histological changes of epididymis of male rabbit's sever fibrosis (F), hyperplasia of epithelial cells (H) with proliferation (H&E ×40).

Four groups

There is severing suppression of spermatogenesis with increase vascularization in scrotal membrane. In additional congestion, increase vacuolation, increase fibrosis and projected in lumen of epididymis (Figure 9, 10, 11).

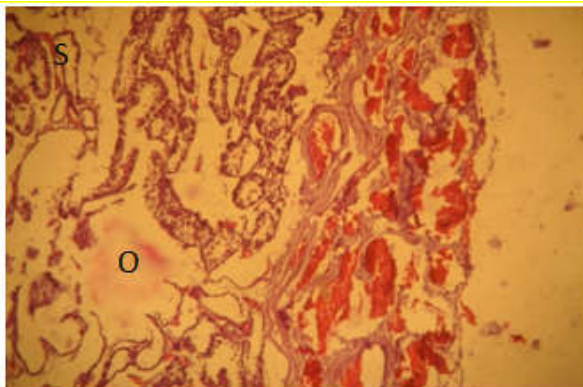


Figure (11): Showing histological changes testes of male rabbit's which shows sever congestion; sever hemorrhage; edema(O); sever atrophy, and sever vacuolated and there are suppression of seminiferous tubules(S) (H&E×10).

DISCUSSION

Laser has the ability to stimulate the proliferation of epithelial cells (10). The irradiation of diode red laser (650nm-10w) in rabbits affected on both qualitative and quantitative changes of epithelial cells in seminiferous tubules, spermatogenesis process, reduction in testicular interstitial tissues, and epididymis due to inhibition of testosterone hormone formation process. This finding might be explained by the effect of laser on (LH) receptors in testicular interstitial tissue (11), causing inflammatory process of testes (orchitis) and (epididymitis) occasionally. One or both scrotal sacs may be affected, with acute, painful swelling to twice normal size although the testes may not be grossly enlarged. The swelling persist for a considerable time and the testis undergoes liquefactive necrosis and eventually destroyed, the seminal vesicles may be affected and their enlargement can be detected on rectal palpation (12). The inflammation due to injury to the cells and organelles membrane can occur in many ways. One of the most common and important is free radical injury. These molecules are highly reactive, transient chemical species, generated as by-products of normal oxidative metabolism or by exposure to radiation, most, but not all, are reactive oxygen radicals are also produced by phagocytic cells in inflammatory lesions and account for significant damage to surrounding tissue, presence of inflammatory cells with edema in the loose scrotal fascia, exudate in the tunica vaginalis and early granulation tissue formation (13). In chronic stage, the tunics of the testes become thickened and fibrous with adhesions develop between them. There are circumscribed indurations in the epididymis and these granulomata may also be present in the testicle. In advanced stages, they undergo caseation necrosis characterized by thickening due to increased granulation tissue, fibroblast proliferation, collagen synthesis, neovascularization, early epithelidization and edema, and enlarged hard (14).

Testosterone is produced by leydig's cells of the testes and it is the most important male hormone for the development of sexual characteristics (15). Hypogonadism resulting with defective seminiferous tubules and leydig's cells function may cause infertility in animals due to reduced production of spermatogenic cells (16). There are numerous studies suggesting that chronic exposure of IM exhibit defects in the gonads of animals (17). In the present study, histopathological observations confirmed that IM caused

testicular damage in test group animals. Animals treated for 10 days showed empty seminiferous tubules in the lumen and interstitial space became widened, probably due to elimination of leydig's cells.

التأثير المباشر لإشعاع الليزر الأحمر على أنسجة الخصية والبربخ في ذكور الأرانب

إحسان علي حبيب*، زينب وحيد**، موسى فاضل عباس*

*** قسم الجراحة والتوليد، كلية الطب البيطري، جامعة البصرة، البصرة، العراق

** قسم علم الأمراض، كلية الطب البيطري، جامعة البصرة، البصرة، العراق

الخلاصة

صُممت هذه الدراسة لتقييم تأثير اشعاع الليزر الأحمر على أنسجة الخصية والبربخ. تم استخدام ٢٠ من الأرانب الذكور الناضجة في الدراسة الحالية. تم تقسيم الحيوانات إلى أربع مجموعات، المجموعة الأولى كسيطرة و ٢، ٣، ٤ مجموعات تعرض للإشعاع بالليزر الأحمر ٥ دقائق و ١٥ دقيقة و ٣٠ دقيقة على التوالي يوميا لمدة ٣٠ يوم. تم أخذ عينة نسيجية بعد تشريح جميع حيوانات التجربة لتحضير شرائح نسيجية لفحصها تحت المجهر الضوئي. نتيجة التغيرات النسيجية الناتجة عن تعرض الحيوانات إلى الليزر الأحمر (٦٥٠ نانومتر - ١٠ واط) والتي تظهر في مقابل التغيرات، وهذه التغيرات المرضية تتناسب مباشرة مع فترة التعرض التي تظهر على شكل احتقان أو فقر دموي أو نخر في التراكيب النسيجية للخصية والبربخ.

REFERENCES

1. **Meikha, N.H. (2005).** Stimulation Burn Healing Using 790 Diode laser in Rabbits. M.Sc. Thesis. Laser Institute for Higher Education. University of Baghdad.
2. **Huang Y M, Zhou F, and Zhai G, (2003).** Effects of red laser and green laser irradiation on optical properties of an azo-containing bent-core liquid crystal. Engineering materials, 5: 428-429.
3. **Gresner P, Watala C, and Sikuroval L, (2005).** The effect green laser light irradiation on whole blood platelets. Journal of photochemistry and photobiology B:biology, 77(1): 43-50.

4. **Genina E A, Bashkator A N, Simoneko G V, Odoevskay O D, Tuchin V V, and Altshuler G B, (2004).** Low intensity indocyanine-green laser phototherapy of acne vulgaris: pilot study. *Journal of biomedical optic*, 9(4): 828-834.
5. **Brinkmann R, Sliney H D, Liue W, and Vincelette R L, (2012):** Real-time temperature determination during retinal photocoagulation on patients. *Journal of biomedical optics*, 17(6): 121-132.
6. **H. Abu, A. I. Kisani and T. Ahemen (2016):** Evaluation of sperm recovered after slaughter from cauda epididymides of red Sokoto bucks. *Veterinary World*, EISSN: 2231-0916; Pp. 1440-1444.
7. **Sandro C. Esteves and Alex C. Varghese (2012):** Laboratory handling of epididymal and testicular spermatozoa: What can be done to improve sperm injections outcome. *J Hum Reprod Sci*. 2012 Sep-Dec; 5(3): 233–243.
8. **Senger P.L., Johnson L., Smith M.F., Tatum M., Katz L.S. and Fields M.J.(2005):**textbook of pathways to pregnancy and parturition. Second revised edition Pp.216-237.
9. **Bancroft D.J. and Gamble M. (2002):** Theory and practice of histological techniques. 5th London; Harcourt publishers limited; Pp.181-182.
10. **Nazhad H. Q.; Nadem H. M. and Basheer M. A. (2016):** Effect of he-ne laser on blood serum testosterone and testicular tissue in adult male rats. *Journal University of Zakho*, Vol. 4(A), No.1, Pp. 25-31.
11. **Arthur. G.H. Noaks .D.E. Pearson. H. and Parkinson.T.J (1998):** Veterinary reproduction and obstetrics seventh Ed.W.B. Saunders Company limited 553-559.
12. **Otto M. Radositis, Clive C Gay, Kenneth W. Hinchcliff, Peter D. Constable (2007):** Veterinary medicine, textbook of the diseases of cattle, horses, sheep, pigs and goats.Pp.970-971.
13. **Basavaraj M.K. ; Ashoh S.G. and Pandit S.K.(2011):** Efficacy of low level laser therapy on wound healing in patients with chronic diabetic foot ulcers- A Randomized control trial. *Indian J. Surg.* Dot 10.1007.
14. **Handerson and Blood Radostits (1990):** Veterinary medicine, textbook of the diseases of cattle, horses, sheep, pigs and goats. printed and bound in Great Britain at the pitman press Ltd, Bath. Pp.615-616.
15. **Mycek M.J, Harvey R.A. and Champe, P.C., (1997):** Lippincott's Illustrated Rivew: Pharmacology Edn 2, LippincottRaven, and Philadelphia.

16. **Omiama S.E.(2004):** Protective Effect of Vitamin C and Glutathione against the Histopathological Changes Induced by Imidacloprid in the Liver and Testis of Japanese quail. Egyptian journal of Hospital Medicine., 16:39-54.
17. **Matsuda K, Buckingham SD, Kleier D, Rauh JJ, Grauso M, Sattelle DB et al.(2001):** Neonicotinoids: insecticides acting on insect nicotinic acetylcholine receptors. Trends Pharmacology Science; 22(11):573-580.