

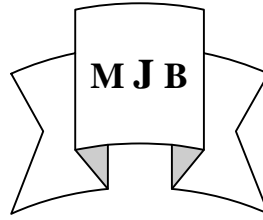
Spiral Artery Blood Flow in the Central and Peripheral Area of Placental Bed in the Normal Third Trimester by using Color-Doppler Ultrasound

Mohammed U. Hamza

Rasha K. Al-Yassin*

College of Medicine, Babylon University, Head of Department of Anatomy

*Al-Khadumia Teaching Hospital, Baghdad IRAQ.



Abstract

- ◆ To assess the ability of colour/pulsed Doppler Ultrasound to assess the impedance of blood flow through spiral arteries in the central and peripheral area of the placental bed.
- ◆ This study has shown that there is statistically significant lower impedance values of blood flow in spiral arteries were obtained in central compared with peripheral area of placental bed, so we can compare the spiral artery flow velocity waveform in normal pregnancy and complicated pregnancies.

الخلاصة

الهدف من اجراء هذه الدراسة هو تقييم فاعلية جهاز الدوبلر لتقييم الممانعة لجريان الدم في الشرايين الحلزونية في الجزء المركزي والمحيطي للمشيمة وظهرت هذه الدراسة ان هناك اختلاف في جريان الدم في الشرايين الحلزونية في الجزء المركزي للمشيمة عنه في الجزء المحيطي في الحالات الطبيعية للحمل عن طريق قياس معاملات المقارنة (Resistance Index) والتنباض (Pulsatility Index). ولذلك يمكن مقارنة هذه القياسات مع النساء ذات الحمل الغير طبيعي.

Introduction

- ◆ Duplex and colour Doppler ultrasound are non-invasive techniques capable of producing much information about the condition of blood vessels and flow within them. [1]
- ◆ The placenta is an organ with multiple functions vital to normal fetal development, its metabolic functions are complex and it continuously undergoes throughout gestation changes in weight,

structure, shape, as well as function in order to support prenatal life. [2], Fig. (1).

- ◆ The uterine spiral arteries constitutes one of the most reactive in the body (27) and spiral arteries are continually changing in response to the hormonal and local manifestation of the uterine cycle. In pregnancy and the puerperium the uterine vessels generally undergo even more spectacular alternation
- ◆ Cytotrophoblast invade the uterine spiral arteries reaching the decidual segment by 4-6weeks (primary wave invasion) and reaching the upper third of the myometrial segment by 16-18 weeks

(second wave invasion). Fig. (2).

- ◆ The end result is conversion of these small arteries to distended channels of low resistance but high conductance (28), capable of increasing, the blood supply to the fetoplacental unit in the third trimester to ten-times that of non-pregnant level. Fig. (3).
- ◆ Colour doppler ultrasound has enabled precise investigation of fetomaternal circulation. In early pregnancy decrease of peripheral impedance, as well as, increase of blood flow velocity was found in all segments of uteroplacental circulation with gestational age. [4]

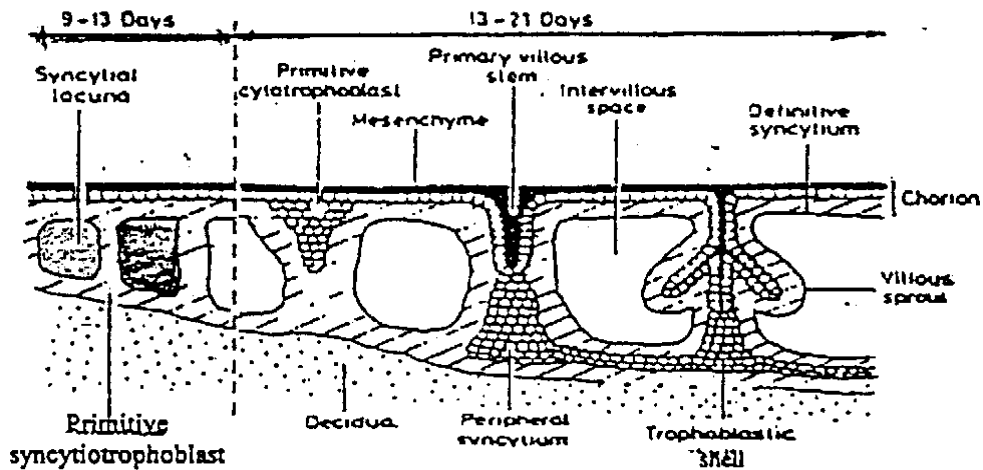


Figure 1 Diagrammatic representation of the development of the placenta

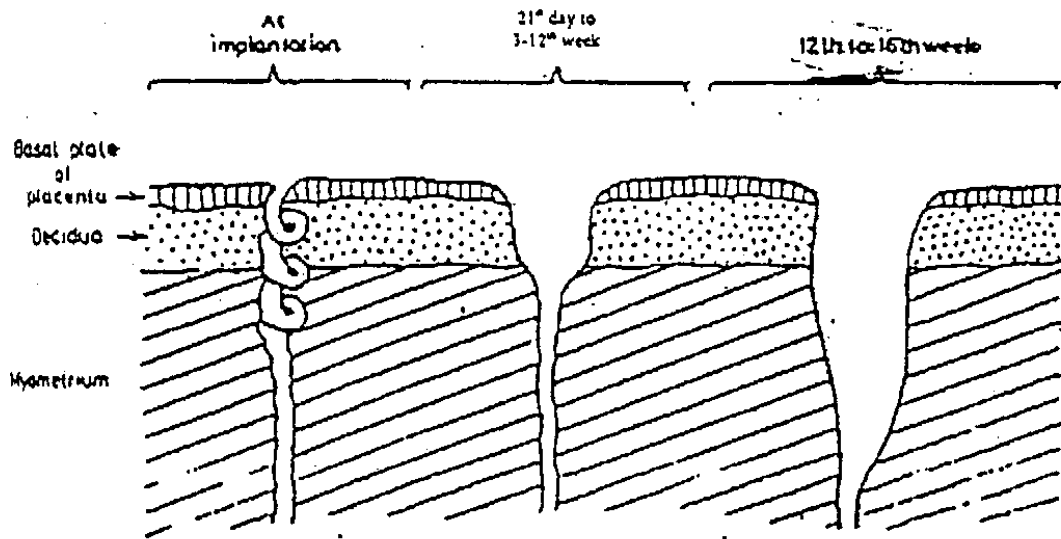


Figure 2 Diagrammatic representation of the conversion of the spiral arteries into uteroplacental arteries.

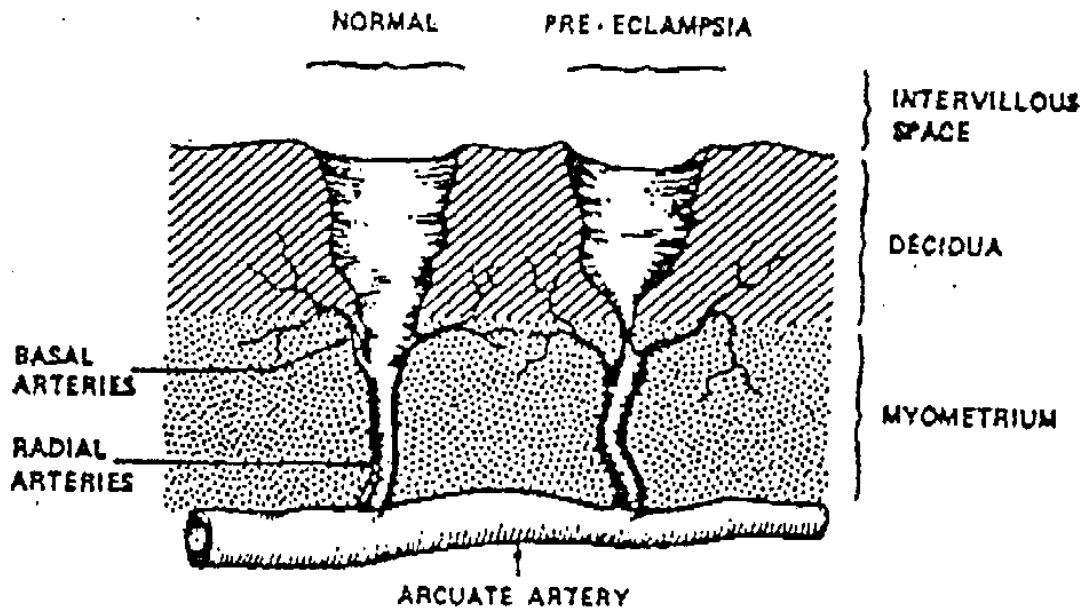


Figure 3 Incomplete transformation of the spiral arteries in pregnancy – induced hypertension (on the right) compared to those of an uncomplicated pregnancy (on the left).

Purpose of the study:

- ◆ To assess the ability of colour/ pulsed Doppler ultrasound to assess the impedance to blood flow through spiral arteries in central and peripheral area of the placental bed.
- ◆ To assess spiral artery flow velocity waveform in normal pregnancies.

Subject and Methods:

- ◆ This study was conducted at department of obstetrics and gynecology in cooperation with department of radiology in Al-Yarmouk Teaching Hospital.
- ◆ 20 pregnant women in their third trimester of gestation. (between 28-34 week gestation). They were apparently healthy women, hadn't alternation in blood pressure or proteinuria and all were normal on physical examination with no medical problems and normal vital signs.
- ◆ After obtaining a clear pulsed Doppler signals, the image frozen, resistance index (RI) and pulsatility index (PI) were obtained.
- ◆ After the delivery of the placenta, the membranes around its edge trimmed off, the umbilical cord has been cut at its insertion site and the adherent blood

clots were removed from the maternal surface of the placenta, finally, it was weighted.

Results:

- ◆ The values of resistance index in central and peripheral area of placental bed. (Table I).
- ◆ The resistance index values in spiral arteries were significantly lower in the central parts of placental bed (mean 0.214 ± 0.015) compared with peripheral area (mean 0.255 ± 0.012). [$t = 3.5743$, $df = 38$, $p < 0.001$].
- ◆ Table (II) shows the values of pulsatility index in central and peripheral area of placental bed. The pulsatility index in the spiral arteries were significantly lower in the central parts of the placental bed (mean 0.264 ± 0.018) compared with peripheral area (mean 0.294 ± 0.024) [$t = 2.615$ $df = 38$, $p < 0.02$].
- ◆ The mean gestational age at time of birth was 38.3 ± 1.342 Table (III).
- ◆ A significantly higher birth weight was found (3245.0 ± 627.306).
- ◆ A significantly higher placental weight was found (562.65 ± 90.481)
- ◆ A more significantly correlation was found between peripheral resistance index and pulsatility index with birth

weight and placental weight. An increase in their values were associated with significant reduction in birth weight and placental weight, as well as earlier gestational age at the time delivery.

Discussion:

- ◆ In our study, statically significant lower impedance values of blood flow in spiral arteries were obtained in central compared with peripheral area of placental bed.
 - ◆ This is in concordance with the results of Matijeuc et al (1995) that impedance of the central spiral artery is lower than that of peripheral spiral artery. [5]. Also he stated that the central and peripheral area of the placental bed should be investigated separately in all studies.
 - ◆ This implies that physiologic development of the central spiral arteries is more complete at that time than that of peripheral arteries.
 - ◆ Hsich et al's (2000) found no difference between impedance of the central versus the periopheral spiral arteries. [6]
 - ◆ Our observation are in concordance with histological data for normal pregnancy. [7]
- This is in concordance with the results of Murakoshi et al (1996). In their study,

the abnormal spiral artery resistance index is found to have a better diagnostic accuracy for adverse prenatal outcome.

- ◆ Lack of Doppler signal from the spiral arteries correlates with bad condition of neonate after delivery.
- ◆ So in assessing the fetal status using Doppler ultrasound, the central and peripheral areas should be examined separately.
- ◆ Most of studies carried on the spiral arteries had been conducted in early pregnancy. In our study, the patients were examined in their third trimester.
- ◆ We believe that spiral artery flow velocity waveform provides more accurate information about uteroplacental circulation in the evaluation of physiological changes and the relationship with abnormal pregnancy such as preclamptic.

Conclusions:

- 1- The colour/pulsed Doppler ultrasound can assess the impedance of blood flow through spiral arteries in central and peripheral areas of the placental bed.
- 2- We can compare the spiral artery flow velocity waveforms in normal pregnancy and pregnancies complicated by pregnancy induced

hypertension or intrauterine growth retardation.

References:

- 1- Asim Kurjak, M.D: Three dimensional and power doppler image in the assessment of vascularity (2000) P. 7.
- 2- Teasdale-F. , Am. J. Obstet. Gynecol. 1989: 137 (5) 560.
- 3- Elliot E. Phillip Josephis Barnes DBE, Michell N.: Scientific foundation obst. And gynecol. London. William – Heinemann medical book, third edition (1986).
- 4- Olofsson. P; Laurn: RN, Marsal KEur. J. Obst. Gyncecol. Reprod. Biol. 1993 May; 49 (3): 161.
- 5- Matijevic – R; et al, Obst. Gynecol. 1995 Aug; 86 (2): 298.
- 6- Hsieh et al., Journal of clinical ultrasound, Feb. 2000; 28: 78.
- 7- Pijneuborg R. et al.,Planta 1981: 2: 303.
- 8- Murakoshu et alUltrasound – obstet. Gynecol. 1996 Feb; 7 (2); 122.
- 9- Xu-J; Wen. L.; Ma-T,Chung-Haa-Fu-Ctian-Ko-Tsa-Chih. 1998 April; 33(4): 209.
- 10- Nillson A. et al., J. Ultrasound Med. 1997; 16: 275.

Table I Resistance index (RI) values in central and peripheral spiral arteries in normotensive group. Values are given as a Mean ± standard deviation (SD).

	Control
Central RI	0.214 ± 0.015
Peripheral RI	0.255 ± 0.012
	T = 3.5743 Df = 38 P < 0.001

Df = degree of freedom

Table II Pulsatility index (PI) values in central and peripheral spiral arteries in normotensive group. Values are given as a Mean \pm standard deviation (SD).

	Control
Central PI	0.264 \pm 0.018
Peripheral (PI)	0.294 \pm 0.034
	T = 2.615 Df = 38 P < 0.02

Df = degree of freedom

Table III Mean birth weight (grams), placental weight (grams) and gestational age at birth (weeks) in normotensive group. The values are given as a Mean \pm standard deviation (SD).

	Control
Birth weight	3245.00 \pm 627.306
Placental wt.	562.65 \pm 90481
GA	38.3 \pm 1.342