

Radiographic and microscopic evaluation of the efficacy of two different techniques in obturation of internal resorption defects (An *in vitro* comparative study)

Ragheed M Basheer
BDS, MSc (Assist Lect)

Department of Conservative Dentistry
College of Dentistry, University of Mosul

ABSTRACT

This study was designed to determine the effectiveness of lateral compaction and ultrasonic condensation obturation techniques for internal resorption defects, for which 20 extracted human maxillary central incisors teeth were selected. They were instrumented up to size 55 file. Their roots were sectioned transversely 6 mm from the apex and hemicircular cavities were prepared in both sections using #6 round bur. The sections were glued back together using cyanoacrylate thus obtaining root canal with cavities simulating internal resorption. The teeth were randomly divided into 2 groups of 10 teeth each. The following obturation techniques were evaluated: Lateral compaction (Group I), and ultrasonic condensation (Group II). Ultrasonic condensation gave good results. Obturated internal resorption defects were filled mainly with gutta percha. Statistical analysis showed that there was significant difference between Groups I and II. Results with lateral condensation were inferior compared to ultrasonic condensation technique for obturation of simulated internal resorption defects. Therefore, the latter technique is recommended to be used to obturate the defects of internal resorption defects in clinical practice.

Key Words: Resorption, obturation, ultrasonic technique.

Basheer RM. Radiographic and microscopic evaluation of the efficacy of two different techniques in obturation of internal resorption defects (An *in vitro* comparative study). *Al-Rafidain Dent J.* 2005; 5(1): 83-87.

Received:

6/9/2004

Sent to Referees:

12/9/2004

Accepted for Publication:

15/3/2005

INTRODUCTION

Internal root resorption presents itself as an irregular resorptive defect in root canals. It is characterized by resorption of internal aspect of root by multinucleated giant cells adjacent to granulation tissue in pulp. Chronic inflammatory tissue is common in pulp but causes internal resorption only if odontoblastic layer and predentin are lost or altered. Reasons for loss of predentin layer is not obvious but trauma has been suggested as the etiological factor in most case, the only treatment modality is removal of the inflammatory pulp followed by its obturation. The presence of organic debris and bacteria in these irregularities may interfere with success of endodontic treatment. Another problem encounter-

ed is the fact that the complete extent of the defect cannot be determined either clinically or radiographically, which further calls for finding a perfect way of obturating these defects.⁽¹⁾

The literature describes various obturation techniques, which have been advocated by different authors to obturate internal resorption defects. Frank and Wiene⁽²⁾ have suggested the use of heavy lateral and vertical condensation of gutta percha for such cases. Gutman *et al.*⁽³⁾ have suggested the use of Thermafil obturation technique. Wiene⁽⁴⁾ recommended the use of thermo-mechanical compaction. This has led to some confusion as to which technique to choose for obturating these defects.

The purpose of this study was to evaluate the efficacy of two obturating techniques (lateral compaction and ultrasonic condensation) in such conditions.

MATERIALS AND METHOD

For this study 20 freshly extracted human maxillary central incisors were selected. Part of the crown was removed to get a standard root length of 20 mm. Access cavity was prepared in each tooth using high speed diamond burs (Qualye Dental, England).

The working length was calculated clinically using size 15 K file (Dentsply, Maillefer, Swiss) inserted within the canal until it appears from the apex kept 1 mm short of the apex. All teeth were instrumented at the working length to file # 55. Sodium hypochlorite solution (5.25%) was used as an irrigant between instruments. Following instrumentation, experimental internal resorption defects were created using the following procedure:⁽⁵⁾ A guide mark was placed on the buccal surface of each tooth using carborundum disc size 3/4 (Associated Dental Product Ltd, Kempton, Purton, UK). Each tooth was sectioned transversely 6 mm from the apex, using diamond disc with water spray. Hemicircular cavities were prepared using #6 round bur at the opening of the root canal. Both sections were then glued back together using cyanoacrylate glue (Superglue, Quickstar, Furkan Kirtasiye Ltd, STI, China) by pairing the guide mark. Figure (1) showed radiograph of the tooth after complete preparation of simulated internal resorption defect. Care was taken to maintain the patency of the canal by using minimal amount of glue and by using size 55 file post gluing.

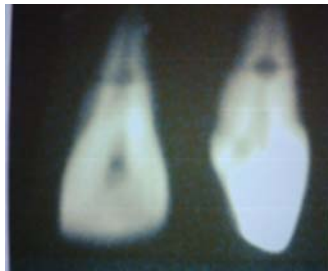

Figure (1): Buccolingual and mesiodistal radiographs of simulated internal resorption defect

The teeth were divided randomly into 2 groups, 10 teeth for each:

Group I: Lateral compaction (later-al condensation technique): After painting the canal wall with sealer (Dorifill Root Canal Sealer, Dürdent, Austria) using lentollospiral (Quayle Dental, England), size 55 gutta percha cone coated and cemented as a master cone, lateral compaction was done using finger spreader and accessory gutta percha cones, excess gutta percha was removed using a heated ball burnisher and was compacted vertically using hand plugger.

Group II: Ultrasonic condensation technique: After painting the canal walls with sealer using lentollospiral, size 55 gutta percha cone was used as master cone. Ultrasonic scaler (Pizon master 400, Parkway, Electro Medical System, EMS, USA) with spreader tip was used and energized along the gutta percha. Accessory cones were placed and were compacted using ultrasonic tip as a spreader and then compacted with finger pluggers.

The teeth then radiographed in buccolingual and mesiodistal aspects to evaluate the quality of obturation at the area of internal resorption defects.

Radiographical Evaluation

Radiograph of each tooth was analyzed under magnification (10×) and were grouped as follows:

Total obturation: The internal resorption defect was obturated completely in both buccolingual as well as mesiodistal radiographs and no empty spaces were visible (Figure 2).

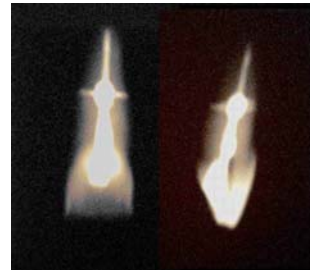


Figure (2): Buccolingual and mesiodistal radiographs of obturation of simulated internal resorption defect by ultrasonic condensation technique

Partial obturation: The obturated internal resorption defect showed empty spaces in the mass of the filling material or between the gutta perch and dentinal walls in either buccolingual or mesiodistal radiograph (Figure 3).



Figure (3): Buccolingual and mesiodistal radiographs of obturation of simulated internal resorption defect by lateral condensation technique

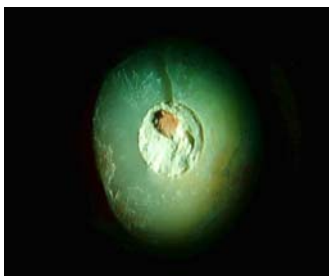
Stereomicroscope Evaluation

After the radiographic assessment the teeth were sectioned at previous level using a sharp blade (Martin, Germany). The sections were examined under reflected light stereomicroscope (10×) (Biolab BLS 120 Hamilton, Altay Co, Germany). In both sections the nature of filling material predominant at internal resorption defects were recorded and they were grouped as:

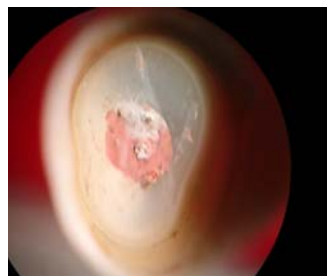
Type I: Predominant filling material was sealer (Figure 4 A).

Type II: Predominant filling material was gutta percha (Figure 4 B).

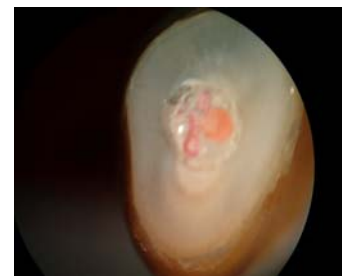
Type III: Equal amount of gutta percha and sealer (Figure 4 C).



(A) Predominant filling material was sealer



(B) Predominant filling material was gutta percha



(C) Equal amount of gutta percha and sealer

Figure (4): Stereomicroscopical photograph of incisors sectioned at simulated internal resorption defect level

Data were analyzed statistically using least significant difference test (Fisher's exact probability test) at $p \leq 0.01$ level.

RESULTS

The radiographic and stereomicroscopic results obtained are summarized in Ta-

bles (1) and (2) respectively. Ultrasonic condensation showed good results. Statistical analysis of the radiographic data as well as stereomicroscopic data indicated that there was significant difference between ultrasonic condensation and lateral compaction.

Table (1): Radiographic evaluation of the efficacy of obturation of internal resorption defects

Type of Group	Total Sample Number	Total Obturation	Partial Obturation
Group 1	10	3	7
Group 2	10	9	1

Group 1: Obturation using lateral condensation technique.

Group 2: Obturation using ultrasonic condensation technique.

Table (2): Stereomicroscopic evaluation of the type of the material obturating of the internal resorption defects

Groups of the Samples	Type 1	Type 2	Type 3
Group 1	3	3	4
Group 2	0	8	2

Type 1: The predominant amount of filling material was sealer
 Type 2: The predominant amount of filling Material was gutta percha
 Type 3: Approximately equal amount of both gutta percha and sealer

According to Table (1), it could be found that ultrasonic condensation technique was more effective in producing total obturation of simulated internal resorption defects comparing with lateral condensation; the difference was significant.

Table (2) and Figure (5) showed the nature of filling material in the simulated

internal resorption defects: Most of samples obturated with ultrasonic condensation technique were filled mainly with gutta percha, while in lateral condensation technique the samples were mainly filled with sealer the difference was also significant.

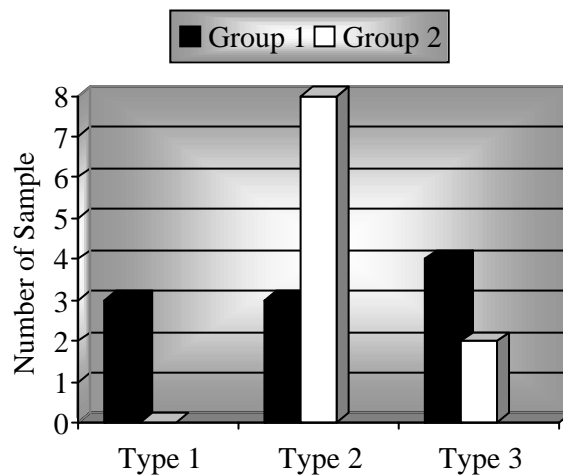


Figure (5): Stereomicroscopical photographic evaluation of incisors sectioned at simulated internal resorption defect level

DISCUSSION

The success of root canal therapy depends upon total and complete obliteration of root canal space by a dimensionally stable and biologically compatible material.⁽¹⁾ The normal root canal anatomy may be altered in various pathological processes making this task very difficult and at times impossible to achieve by normal methods of obturation. One of such conditions is internal resorption, which presents as an irregular defect in the root canal making that

area inaccessible to normal method of cleaning and shaping as well as obturation. Internal resorption is a condition which is triggered by inflammatory process in vital pulp leading to sequence of event involving dentinoclastic activity which causes resorptive defect in root canal. Trauma seems to be the initiating factor in majority of cases.⁽⁶⁾

In the present study, maxillary central incisors with simulated internal resorptive defects located in the middle third of the

roots were used, since these are the teeth and areas in which internal resorption is most frequently seen.⁽⁷⁾ Treatment of internal resorption is complicated by two factors.

1. The area of the resorption is inaccessible to normal method of cleaning and shaping as well as obturation.
2. The correct extent of the resorptive defect cannot be estimated by radiograph as they are essentially a two dimensional image of a three dimensional object.

Further, in a clinical setup, radiographs are only possible in buccoligual view whereas irregularities may be more visible in mesiodistal view.⁽⁵⁾ In this study all teeth were radiographed in both buccolingual and mesiodistal view. As stressed by Gutman *et al.*,⁽³⁾ obturated internal resorption defect should contain more gutta percha than the sealer as the latter is more prone to shrinkage and dissolution. This is more important when obturating internal resorption which may have a perforating lesion.

Lateral compaction gave poorer results than ultrasonic technique which is in accordance with Goldberg *et al.*⁽⁵⁾ Lateral compaction was chosen for the study as it is the most commonly used technique.⁽⁸⁾

Cohen and Burns⁽¹⁾ as well as Moreno⁽⁹⁾ have suggested the use of ultrasonics for obturation. Ultrasonic condensation showed good results as it has the ability to thermoplasticize gutta percha in the canal, thus allowing it to flow in the irregular defects of internal resorption defect.

CONCLUSION

Results with lateral condensation were inferior compared to ultrasonic condensation technique for obturation of simulated internal resorption defects. Therefore,

the latter technique is recommended to be used to obturate the defects of internal resorption defects in clinical practice.

REFERENCES

1. Cohen S, Burns RC. Pathways of Pulp. 6th ed. CV Mosby Co, St Louis. 1994; Pp: 183-185, 501- 502.
2. Frank AL, Wiene FS. Nonsurgical therapy of perforative defects in internal resorption. *Endod Dent Traumatol.* 1999; 18: 60-87.
3. Gutman JL, Saunders WP, Saunders EN, Nguyen L. An assessment of plastic Thermafil obturation technique. Part 2. Material adaptation and sealability. *Int J.* 1993; 26: 179-183.
4. Wiene FS. Endodontic Therapy. 5th ed. CV Mosby Co, St Louis. 1996; Pp: 456-457.
5. Goldberg F, Massone EJ, Esmoris M, Alfie D. Comparison of different techniques for obturating experimental internal resorptive cavities. *Endod Dent Traumatol.* 2000; 19: 116 -121.
6. Walton RE, Torabinajed M. Principle and Practice of Endodontics. WB Saunders Co, Philadelphia. 1984; p: 224.
7. Caliskan MK, Turhun M. Prognosis of permanent teeth with internal resorption: A clinical view. *Endod Dent Traumatol.* 1997; 13: 75-81.
8. Tagger M, Tamse A, Kartz A, Kerzen BH. Evaluation of apical seal produced by a hybrid root canal filling method combining lateral condensation and thermatic compaction. *J Endod.* 1984; 10: 299-303.
9. Moreno A. Thermomechanical softened gutta percha root canal filling. *J Endod.* 1977; 3: 186.