

---

## **FACTORS INFLUENCING THE MANAGEMENT OF THE FLEXOR TENDON INJURIES IN THE HAND**

**Avadis A. Muradian**

F.I.C.M.S. Lecturer in Orthopaedic, Department of Surgery, College of Medicine, and specialist Orthopaedic Surgeon, Basrah General Hospital, Basrah; IRAQ.

### **Summary**

Thirty-three patients with flexor tendon injuries in 68 fingers were studied. They were 78.8% males 21.2% females. Age was range between 16 - 45 years. Patients were assigned into two zone groups; zone II & V. Twenty six fingers (38.2%) were in zone II, and 42 (61.8%) were in zone V. Primary repair was done in 42.6% and delayed in 57.4%. Both tendons (FDS\* & FDP\*\*) were repaired in 43 fingers, isolated FDP were repaired in 25 fingers. Postoperatively, only 31 fingers were managed with early active extension/passive flexion technique. The final results were evaluated by Louisville criteria and were Satisfactory (excellent and good) in 41 fingers (60.4%). The results were correlated to the involved zones, timing of the repair, type of the repair and the post-operative management program. It is concluded from this study that it is preferable to repair both tendons if possible by delayed primary repair with early mobilization when a trained surgeon and surgical resources are available.

\**Flexor digitorum sublimis*

\*\**Flexor digitorum profundus*

---

### **Introduction**

**T**he repair of the flexor tendon injuries is of prime importance and at the same time the return of satisfactory finger performance after repair remain one of the most difficult and challenging problems from the time of laceration until the return of full function<sup>1,2,3,4</sup>.

The anatomy, nutrition and healing of the flexor tendons should be well known to the surgeon dealing with the injuries

in this area, recently most surgeons have focused on the benefits of the meticulous exposure, nontraumatic repair, type and biomechanics of the suture technique and of the early post repair motion, on which the success ultimately dependent<sup>2,5</sup>.

The purpose of this study is to evaluate the factors effecting on the out come of the tendon repair.

### **Materials and Methods**

This is a prospective study conducted from January 1999 to August 2001, at Basrah General Hospital, 33 patients

---

#### **Correspondence to:**

Dr. Avadis A. Muradian  
Department of Surgery, College of Medicine  
University of Basrah, Basrah; IRAQ.

with cut flexor tendons in the hand were studied, there were 26 male (78.8%) and 7 female (21.2%) patients, the average age of the patients was 27 years (range, 16 to 45 years).

Thumb injuries, crush injuries, joint injuries, fractures and patients below 15 years were excluded from this study, flexor tendons were injured in 68 fingers, 54.8% of the injury was in the right hand (Table I), lacerated tendons were assigned in to two zones only, zone II and V, 26 fingers (38.2%) were in zone II and 42(61.8%) in zone V, and most common digit injured was the index 21(38.9%) (Table II).

Sex	No.	%
Male	26	78.8
Female	7	21.2
Side	No.	%
Right	18	54.5
Left	15	45.5

Table I. Sex and side

Fingers	No.	%
2 <sup>nd</sup>	21	30.9
3 <sup>rd</sup>	19	28
4 <sup>th</sup>	16	23.5
5 <sup>th</sup>	12	17.6
Total	68	

Table II. Fingures involved in the injury

All the patients underwent surgery, table III shows that, the injured tendons were repaired primarily (on the day of injury) in 29 Fingers (42.6%), and delayed in 39(57.4%), the techniques of the tendon repair employed included direct end-to-end suture with modified kessler technique and mattress suturing (when multiple tendons injured)using 4/0 or 5/0 prolene. Both tendons (FDS and FDP) were repaired in 43 fingers (63.2%)while isolated FDP repair in 25 (36.8%), a dorsal plaster splint was used to immobilize the hand and the wrist for a period of 4 to 8 weeks, post operatively

in 31 fingers (45.5%) early passive mobilization by the kleinert active extension-passive flexion technique was used, while the remaining 37 fingers (54.5%) were managed with simple immobilization with active extension-active flexion program.

Zone	Primary Repair	Delayed Primary repair	Combined repair FDS & FDP	Isolated repair FDP	Early Mobilization	Simple Immobilization
II	10	16	14	12	11	15
V	19	23	29	13	20	22
Total	29	39	43	25	31	37
%	42.6	57.4	63.2	36.8	45.5	54.5

Table III. Repair according to timing, type of repair and postoperative management.

In the assessment of the functional outcome after repair, we use the Louisville criteria of pulp to palm distance and the sum of extension lag of the metacarpophalangeal and interphalangeal joints, the rating were defined as follows, "excellent"-flexion within 1cm of distal palmer crease (DPC) with less than 15 degrees of extension deficit, "good"-flexion within 1.5 cm of (DPC) with less than 30 degrees of extension deficit, "fair" flexion within 3 cm of DPC with less than 50 degrees of extension deficit, "poor" Pulp-to-palm distance over 3 cm or extension deficits over 50 degrees.<sup>6</sup>

## Results

The post operative follow-up period of the 33 patients range from six to fourteen months, in the overall, excellent results were obtained in 13 fingers (19.2%), good in 28(41.2%), fair in 9(13.2%) and poor in 18(26.4%) (Table IV).

Result	Fingers	
<b>Excellent</b>	13 (19.2%)	Satisfactory
<b>Good</b>	28 (41.2%)	41 (60.4%)
<b>Fair</b>	9 (13.2%)	unsatisfactory
<b>Poor</b>	18 (26.4%)	27 (39.6%)

**Table IV. Overall results of surgical treatment.**

Table V shows that excellent-to-good results were found in 30 fingers (71.5%) with tendon repair in zone V, while in zone II only 11 fingers (42.3%) were good. In the early primarily repaired group only in 9 fingers (31%) the result was good, and fair-to-poor in 20(69%) out of 29 fingers, and in delayed intervention group excellent-to-good outcomes were in 32(82%) of 39 fingers. Table VI shows , of the 43 fingers which had both tendons repaired, the excellent to good results were in 22 fingers (51.2%), and in the 25 fingers with only FDP tendon repair the results were good in 19 fingers(76%).

Postoperatively, 24 fingers (77.4%) of the 31 fingers had excellent to good results when early passive mobilization by the kleinert method was performed. In those who were managed with simple immobilization with active extension-active flexion program depending on the ability of the patient, out of 37 fingers we achieved excellent to good results in 17 fingers (46%).

Complications generally were observed in 27 fingers (39.7%) (TableVII), tendon adhesions with contractures which limits the fingers extension were identified in 17 fingers (63%), more in zone II ( 10 fingers), the repair was performed primarily (13fingers), when both tendons were repaired (15 fingers) and when simple active extension-active flexion program was used ( 12 fingers),

in which surgical exploration was required to release the adherent flexor tendons.

Tendon ruptures occurred in 10 fingers (37%), which were equal in both zones, 7 fingers when repaired primarily, 6 fingers when both tendons were repaired, and in 8 fingers with simple immobilization program.

		Excellent	Good	Satisfactory	Fair	Poor	Unsatisfactory	Total
Zone	<b>II</b>	---	11	11	6	9	15	26
	<b>V</b>	13	17	30	3	9	12	42
Timing	<b>Primary</b>	---	9	9	4	16	20	29
	<b>Delayed primary</b>	13	19	32	5	2	7	39

**Table V. Results of the repair according to the involved zone and timing**

		Excellent	Good	Satisfactory	Fair	Poor	Unsatisfactory	Total
Type of repair	<b>FDS &amp; FDP</b>	13	9	22	5	16	21	43
	<b>FDP alone</b>	---	19	19	4	2	6	25
Post Op.	<b>Early mob*</b> .	9	15	24	1	6	7	31
	<b>Simple immob**.</b>	4	13	17	8	12	20	37

\*Mobilization, \*\*Immobilization

**Table VI. Results of the repair according to the type of repair and postoperative management**

		Adhesions	Ruptures	Total
Zone	II	10	5	15
	V	7	5	12
Timing	Primary	13	7	20
	Delayed primary	4	3	7
Type of repair	FDS and FDP	15	6	21
	FDP alone	2	4	6
Post-operative	Early mob.	5	2	7
	Simple immob.	12	8	20
Total		17	10	27
%		63	37	39.7

Table VII. Complications

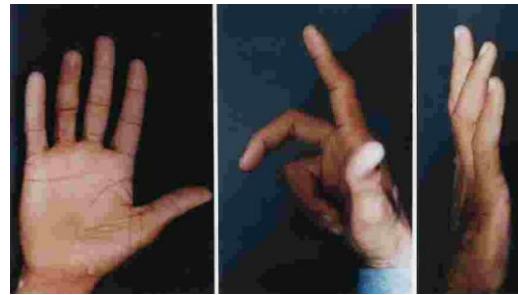


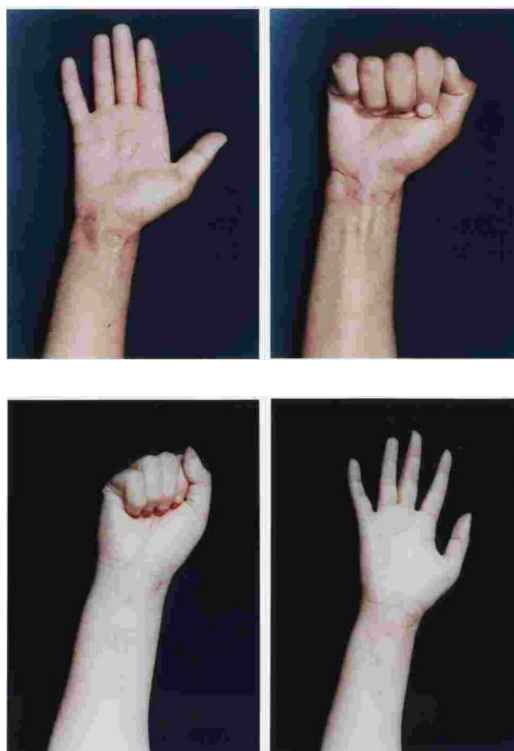Figure 3. Repair of both tendons in zone II of the ring finger.

**Discussion**

Nearly most flexor tendon injuries are open, and accurate prediction of the outcome of the surgical treatment is not always possible<sup>1,3,7</sup>.

In this study 29 fingers (42.6%) with acute flexor tendon injuries repaired primarily at the day of injury (night repair) by the emergency surgeon, only in 9 fingers (31%) satisfactory outcome were achieved, with higher rate of adhesions and ruptures in 20 fingers (69%), while excellent to good outcomes were obtained in 32 fingers (82%) when the repair was delayed and performed by trained surgeon familiar with the flexor tendons relationship in the hand. Brug (1997) achieved (84.8%) excellent to good results in primary repair, and (80.3%) in delayed primary<sup>8</sup>, in his study most of the primary repair was performed by surgeons experience in hand surgery. It has been stated that immediate tendon repair is an accepted procedure once the circumstances permits,<sup>3,9</sup> and the surgeon managing these injuries must realize the importance of the zone, number of fingers and tendons injured, and the severity of the swelling, and the experience provides further support to successful treatment which requires awareness about the anatomy of tendon blood supply and the pulley system, adequate exposure, and precise application of non traumatic surgical as well as suture technique<sup>1,2,6,10,11,12</sup>.

Our results confirm that immediate primary tendon repair (especially at



Figures 1&2. Repair of both tendons in zone V

night) with unfamiliar surgeon has been associated with higher rate of failure that requires re-operation which carries more surgical technical difficulties and risk of more damage and complications. Previous studies demonstrated that flexor tendon repair should be considered a surgical emergency, they postulated that equal or better outcomes can usually be achieved by delayed primary repair, than that of late night repair and the notion of tendon repair are absolutely a surgical emergency has been effectively overcome<sup>3,6,9,14</sup>.

To repair both FDS and FDP tendons or the repair of FDP alone is questionable, because of the problems of adhesions, and ruptures which will limit the range of recovery of the fingers flexion, especially in the fingers with both tendons injured in zone II<sup>3,11</sup>. Recently many studies demonstrated that in most instances it is better to repair both tendons rather than FDP alone, because of the advantage of preserving the blood supply of FDP, providing better independent interphalangeal joint (I.P.J) movements and reduce the risk of rupture<sup>2,3,15</sup>. Meals (1985) advocated that it is better to repair both tendons<sup>14</sup>, while Tang (1994), suggested better to repair only FDP when both tendons are injured in zone II(2c) to reduce the risk of adhesions and ruptures.<sup>16</sup> In our series, excellent to good outcomes were obtained in (68.9%) of the fingers when both tendons were repaired in zone V (Fig.1 and 2), and good was in (14.3%) of the fingers when both repaired in zone II, while in the repair of FDP alone in zone II showed good results in (75%) of the fingers, so tendon repair in zone II remains the most problematic and controversial area, but in the repair of FDP alone we found the return of PIP joint flexion to acceptable degrees taken more longer period, and the repair of both tendons in zone II achieve better flexion of PIP joint, but at the same time we loss some degrees of extension (Fig.3). On

the basis of our results all the excellent outcomes were observed in zone V when both tendons were repaired. However in most series<sup>2,3,12,14,15,17</sup> including our own, it has been found that the repair of both tendons in zone V is preferable, and if possible in zone II, which requires proper surgical technique and early extensive post operative rehabilitation program. Indeed James, mentioned that the complications resulting from reckless tendon surgery can result in greater functional impairment than if no repair have been attempted at all.<sup>9</sup>

The program of the postoperative management is an important factor affecting the functional outcome of the hand, several studies have shown that the early controlled finger mobilization limits the formation of peritendinous adhesions and also the greater the increments of the stress at the repair site and tendon excursion, the faster the tendon will achieve normal tensile strength and increase the range of motion of the fingers<sup>3,6,9,18</sup>. There are many regimens for the rehabilitation of flexor tendon injuries, and previous articles pointed that superior results followed tendon repair that were managed by one of the several early mobilization protocols<sup>2,12,13,19,20</sup>. The Kleinerts active extension-passive flexion technique is the post operative management that has the most acceptance in our study, and was used in 31 fingers (45.5%) for a period not less than 4 weeks with full activity encouraged after 8 weeks, 77.4% of the fingers gained satisfactory functional results while the remaining 37 fingers (54.5%) were managed with active flexion and active extension program depending on the patient, in which only 46% of the fingers regained satisfactory function. Kitsis (1998), achieved 95% excellent to good results by using Kleinert dynamic splint in the postoperative treatment,<sup>12</sup> on the other hand many authors stated

that one of the problems of Kleinert's elastic band mobilization was flexor contracture of the I.P joint which limits the fingers extension,<sup>21,22,23</sup> this problem has been encountered in 19.3% of the fingers in our series, because this depends mostly on the cooperation, and psychological characteristics of the patient, they must understand this exercise program in addition gentle passive and active exercise of the uninjured fingers are encouraged.

Adhesions and ruptures are the most common complications that limit the return of tendon function despite of the advances in the operative and postoperative techniques.<sup>2,3,7,12,16</sup>

In this study these complications were found in 27 fingers (39.7%) which was higher than Kitis(1998) study(23.3%).<sup>12</sup> Adhesions were in 17 fingers(25%).

Many reviews believe that factors influence adhesion formation around tendon suture include trauma to tendon and its sheath, tissue crushing, tendon ischemia, and type of tendon immobilization, these adhesions between tendon and its surroundings cause more postoperative difficulties than other problems<sup>9,12,14</sup>. We found that adhesions were more in zone II in which both tendons were repaired at the day of injury and also influenced by the postoperative rehabilitation program. Tendon ruptures were occurred in 10 digits (14.7%), was higher than in the Small (9%), and Elliot (5.8%) studies<sup>22,25</sup>, because of the non cooperation, poor compliance patients and with early removal of the splints. These tendon ruptures were equal in both zones and affected by the time and type of the repair, and was more in those when the early mobilization program was not performed. On the bases of the previous reports the strength of the repair is reliant on the strength of the suture technique and suture material

during the inflammatory phase of tendon healing<sup>9,10,12</sup> and occurs most frequently when the patient advised attempts to make a strong passive extension on the relatively weak repair, and in those immobilized in short splint<sup>7,13,12,26,27</sup>.

In summary, this study concludes that the zone and tendons injured, timing and type of the repair, and postoperative mobilization technique had significant effect on the final outcome of the flexor tendon repair, we found that the most favorable outcomes were obtained in those when the repair performed a few days after injury rather than night repair, and when both tendons repaired in zone V, while the functional improvement was less and with high rate of complications when both tendons repaired in zone II, and consideration should be given to the this zone, especially when both tendons injured, so the knowledge and the experience of the surgeon in this area is important, and the use of early passive mobilization by the Kleinert technique has proved to be effective, also this cannot succeed without the patient cooperation, in addition to this, author recommend the referral of all flexor tendon injuries in zone II to a surgical unit with trained surgeons, to prevent or to minimize the rate of complications, they believe that even with the most meticulous surgical intervention may not produce a favorable outcome.<sup>11,14</sup>

Finally in the most published studies, the final results were assessed on the basis of especial criteria systems, and we found that the best indicator in addition to those is the patients ability to use the fingers for performance of different kinds of daily activities, so the rating may be fair according to certain criteria but the function might be just acceptable to the patient for the performance of some activities for daily living.

## References

- 1.Hart RG. Flexor tendon injuries of the hand. *Emerg. Med Clin North Am* 1993; 11(13): 621-36.
- 2.James W. Flexor tendon injuries: II-operative technique. *J Am Acad Orthop Surg* 1995; 3: 55-62.
- 3.James W. Management of acute flexor tendon injuries, *Orthop. Clin North Am* 1983; 14(4): 827-46.
- 4.Kraft S. Lesions of zone II flexor tendon: splints and rehabilitation. *Helv Chir Acta* 1992; 58(4): 451-3.
- 5.Taras JS. Treatment of flexor tendon injuries. *J Hand Ther* 1999; 12(2): 141-8.
- 6.Chow JA. Controlled motion rehabilitation after flexor tendon repair and grafting. *J. Bone and Joint Surg* 1988; 70-B: 591-95.
- 7.Taras JS. Complications of flexor tendon injuries. *Hand Clin* 1994; 10(1): 93-109.
- 8.Brug E. Primary management of flexor tendon injuries of the hand. *Unfallchirurg* 1997; 100 (8): 602-12.
- 9.James W. Flexor tendon injuries: I-Foundations of treatment. *J Am Acad Orthop Surg* 1995; 3:44-54.
- 10.Bhatia D. Factors affecting the strength of flexor tendon repair. *J Hand surgery (Br)* 1992; 17 (5): 550-2.
- 11.Haugstvedt JR. Treatment routines of flexor tendon injuries. *Tidss Nor Laegeforen* 1993;113(19): 2394-6.
- 12.Kistsis CK. Controlled active motion following primary flexor tendon repair. *J Hand Surg* 1998; 23(3): 344-9.
- 13.Steinberg DR. Acute flexor tendon injuries. *Ortho Clin North Am* 1992; 23(1): 152-40.
- 14.Meals RA. Current concepts review flexor tendon injuries. *J Bone and Joint Surg* 1985; 67(4): 817-21.
- 15.Boulas Hj. Strength and functional recovery following repair of flexor digitorum superficialis in zone 2. *J Hand Surgery* 1993; 18B: 22-25.
- 16.Tang JB. Flexor tendon repair in zone 2C. *J Hand Surg (Br)* 1994; 19 (1): 72-5.
- 17.Philip E. Campbells operative orthopedic ch 66: Flexor and extensor tendon injuries 9th edition 3318-62 Mosby 1998.
- 18.Silva MJ. Effects of increased in vivo, excursion on digital range of motion and tendon strength following flexor tendon repair. *J Orthop Res* 1999; 17(5): 777-83.
- 19.Wittebmann M. Washington regime after care of flexor tendon injuries in zone 2. *Hand Milks. Ochir Phast Chir* 1996; 28(4): 191-7.
- 20.Yii NW. A prospective study of flexor tendon repair in zone 5. *J Hands Surg (Br)* 1998; 23(5): 642-8.
- 21.Burge, PD; Elastic band mobilization after flexor tendon repair; splint design and risk of flexor contracture, *J Hand Surgery (Br)* 1990; 15 (4): 443-8.
- 22.Elliot D.The rupture rate of acute flexor tendon repairs mobilized by the controlled active motion regimen. *J Hand Surg* 1994; 19 (5): 607-12.
- 23.May EJ. Rate of recovery after flexor tendon repair in zone II. *Scand J Plast Reconst Surg Hand Surg* 1993; 27(2): 89-94.
- 24.John W, Orthopaedic knowledge update 4, ch 31: wrist and hand trauma, 1994.
- 25.Small JO. Early active mobilization following flexor tendon repair in zone 2. *J Hand Surg* 1989; (Br) 14(4): 383-91.
- 26.Komanduri M. Tensile strength of flexor tendon repairs in a dynamic cadaver model. *J Hand Surg (Am)* 1996; 21(A): 605-11, 1996.
- 27.Gerbino PG. Complications experienced in the rehabilitation of zone I flexor tendon injuries with dynamic traction splinting. *J Hand Surg* 1991; 16(4): 680-6.