

## HISTOLOGICAL STUDY ON THE STRUCTURAL CHANGES OF PLACENTA IN SMOKING IRAQI MOTHERS

**Khalida K Jbara**

Assistant professor, Department of Anatomy, Histology & Embryology, College of Medicine, University of Basrah, Iraq.

### Abstract

The placenta was chosen as a possible sample for detection of degenerative changes by tobacco smoking in the human pregnant female. Passive smoking mother during pregnancy is associated with increase of collagen content of the villi, decrease fetal weight, increase in the number of villi, increase of trophoblastic apoptosis and increase in the thickness of materno-fetal barrier. Sections, 3-5 micron thickness of 40 full term placentae of passive smoking mothers and 30 number of gestational matched placenta were used as control, they were studied under light microscope. Appreciable degenerative changes were found in the group of passive smoker females, the main findings were: thickening of the basement membrane of placental villus, increase in the collagen content of the villus, and increase in the syncytial budding, increase in the materno-fetal barrier thickness and extensive loss of trophoblast. This study concluded that tobacco is harmful to the human tissue and vascular system in general suggesting that smoking results in deteriorating organ structure and function.

### Introduction

The term placenta originates from the Latin word for (Flat cake), The placenta is an essential part of the relationship between the mother and the fetus, lying at interface between mother and baby<sup>1</sup>. It is part of the so called fetal supply line approximately the third month after conception until birth. Placental functions as respiratory, excretory and nutritive organ between fetus and mother. It also produces various hormones which are necessary for continuation of normal pregnancy<sup>1</sup>. Placenta plays a major role in the exchange of toxic substances through circulation Demire, et al, (1994) & Olds, et al. (1994)<sup>2,3</sup>. Exchange of materials between fetus and mother occurred as fetus-maternal barrier, which is composed of fetal vascular endothelium cells and their basement membranes, connective tissue of the

villous, the sub-epithelial basement membrane and its covering of cyto and syncytiotrophoblast<sup>4</sup>.

Tobacco in any form is harmful to almost all system of the body. Smoking habit has increased in recent years. Katzung (1998)<sup>5</sup>, mentioned that out of 3,000 active ingredients in smoke, nicotine is the most dangerous and it can effect the placental tissue. It also affects the fetus directly as it crosses the placental barrier easily due to high fat solubility<sup>6</sup>.

According to Lethrovitra (1983)<sup>7</sup> on the other hand mentioned that, cigarette smoke contain about 300 active ingredients, and carbon monoxide have obstetrical importance. As the placenta is the most important organ between mother and fetus during prenatal period the toxic effect of nicotine may be manifested in it<sup>8</sup>.

## Materials and Methods

About 40 samples of full term placentae from smoker subject immediately collected after delivery the samples were obtained during two years period from the department of Obstetric and Gynecology of (Ben Ghezwan Hospital) in Basrah city.

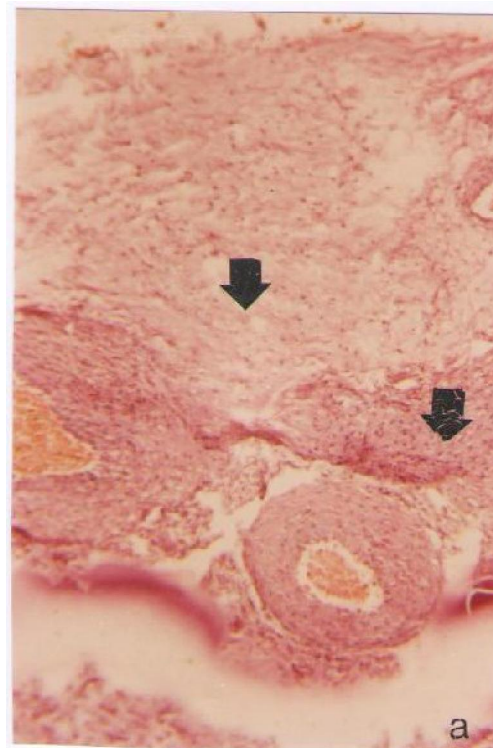
Placenta were collected from passive smoker women who smoked from 10 to 30 cigarettes per day, and 30 samples of non smoking placenta were collected from women with no history of smoking or any other complications before and during pregnancy which were used as control for comparison. All subjects included in this study were healthy looking uniparous or multiparous mothers aged between 17-43 years. The gestational age, fetal weight. Parity were taken from clinical case sheets. About 1 cm thickness were cut from each placenta fixed in (10 %) formalin for 24-48 hours, dehydrated in graded series of ethyl alcohol, cleared in xylene, then infiltrated with and embedded in paraffin. 3-5  $\mu$  paraffin sections were cut and fixed on glass slides with albumin and stained either with heamatoxylin and eosin or periodic acid Schiff reagent and examined by light microscope.

## Results

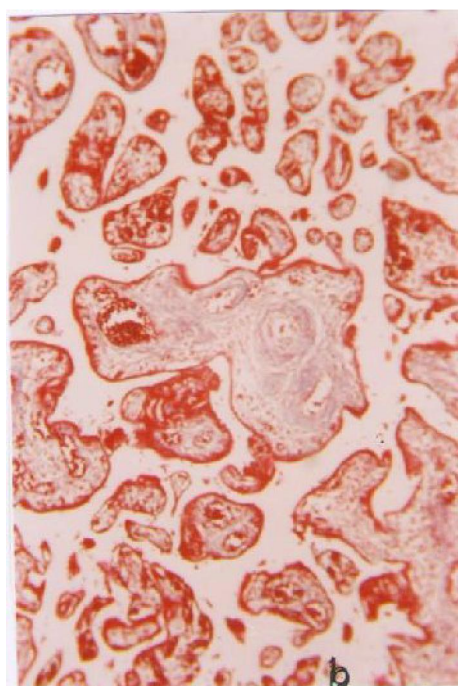
Our results revealed that the placental apparent shape in both control and passive smoker groups were found similar.

The stroma of the placenta consist of collagen fibers, connective tissue and their nuclei. At some places in smoker placenta it was very thick and show large accumulation of collagen when compared to control (Fig 1). In other places it was difficult to differentiate between trophoblastic basement membrane and the fetal capillary, the trophoblastic basement membrane in case of control was thin and was situated between the stroma and syncytiotrophoblast whereas it appeared thicker in smoking mothers

**Figure 1.A:** show large amount of collagen fibers in smoker placenta. Arrows X (742.5)



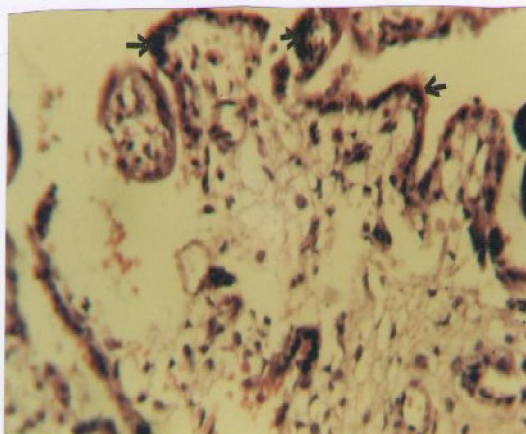
**Fig.1.B:** control X (553.5)



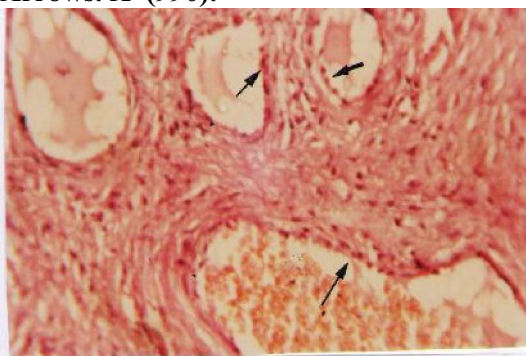The thickness was found irregular in most of terminal villi studied (Fig. 2). The capillaries usually lined by endothelial cells, in case of control, the lumen of the capillaries appeared smooth and the endothelial cells were running transversely along the margin of the

lumen while in passive smoker it was irregular and endothelial cells were protruding into the lumen of the capillaries (Fig 3).

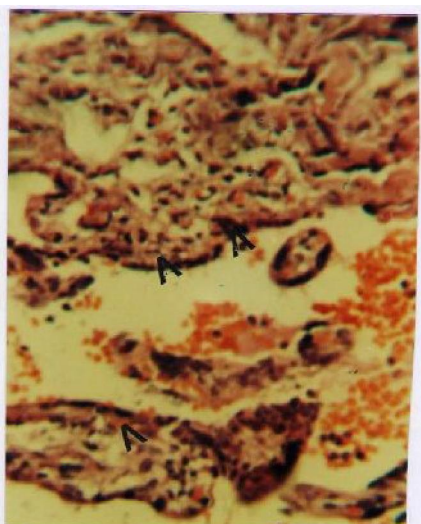
**Figure 2: Show thicker trophoblastic basement membrane in smoker placenta. Arrows. X (990)**



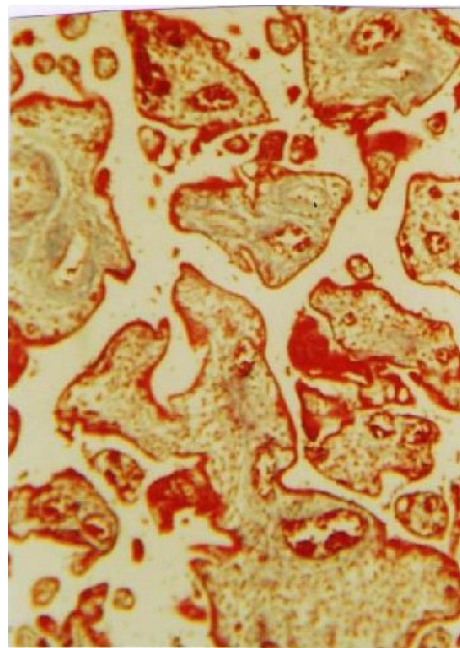
**Fig. 3: Shows protrusion of endothelial cells of blood vessel in smoker placenta. Arrows. X\*(990).**



**Fig. 4. A: Shows Syncytiotrophoblast, degenerated, Pyknotic and dead X (726).**

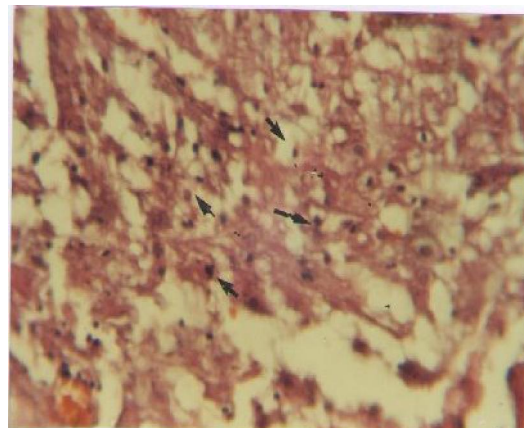


**Fig.4.B: control. X (553.5)**



Syncytiotrophoblast appeared necrotic, degenerated, with darkly stained nuclei when compared to control mothers (Fig 4). On the other hand, however the results also show reduction in fetal birth weight in smoker placenta and it was found significantly differed p value < 0.000. Smoking was also associated with an significant increase in the average number of chorionic villi, large numbers of syncytial buds, and high incidence of apoptosis of parenchymal cells (Fig 5) per unit area in smoke group when compare to control and the results were statistically significant as shown in (Table I).

**Figure 5: Shows large number of parenchymal cells apoptosis. Arrows X (990).**



**Table I**

Parameters	Smoker Mean ±SD	Control Mean± SD	P Value
Mean No. of Chorionic villi per 78.5 mm <sup>2</sup>	11.3140±0.52798	4. 5190±0.43062	0.0000<
Mean No. of apoptosis. per 78.50 mm <sup>2</sup>	109.900±17,3233	53.5000±8.44919	0.0000<
Mean. No. of syncytial knots per 78.5 mm <sup>2</sup>	17.3000 ± 2.90784	4.000 ±1.15470	0.05<
Mean thickness of the barrier in mm.	15.7031 ± 2.86938	10.4969 ±5.56209	< 0.000
Mean Fetal weight in kg.	2.931 ± 0.67786	3.5662 ±0.69998	0.000<

## Discussion

In smoker placentae morphological changes consist in large part of an intensification of degenerative and aging process observed in normal placenta of older women. These changes include increase in stromal fibrosis, high number of villi per unit area, excessive thickening of sub-trophoblastic basement membrane, enlarged and more syncytial buds per unit area and very high incidence of apoptosis in parenchymal cells of placenta.

These findings are similar to those reported by Kerr et al (1972)<sup>9</sup>, who reported atrophy and involution of tissues and organs undergoing extensive apoptosis.

Muhammed, et al, 2003<sup>10</sup>, how observed extensive aging and degenerative changes in smoker placenta he concluded that the extensive parameter aging and degenerative changes in smoker placenta decrease the functional components of an organ, reducing its nutritive and excretory functions, which leads to low birth weight babies in smokers.

Plarrer et al (1999)<sup>11</sup>. Rath,G.et al (2003)<sup>12</sup> have noticed increase in placental weight and corresponding decrease in fetal weight in tobacco smoking mother, these results agreed with our findings which show significance decrease in fetal weight in smoker placenta than non smoker, this could be due to compensatory mecha-

nism which involves in the increase in the size of placenta. Burton 1989,<sup>13</sup>: had observed a significant reduction in the diameter of lumen of the capillaries of terminal villi was observed, protrusion of endothelial cells into the lumen of the capillaries, may resulting the reduction of the diameter of capillaries in passive smokers. as the placenta is the most important organ between mother and fetus during prenatal period the toxic effect of nicotine may be manifested effect in it<sup>8</sup>. Eric, et al 1999,<sup>14</sup>, concluded that nicotine is the main alkaloid in tobacco, concentrate in placental tissue<sup>15</sup>, and active smoking during pregnancy is associated in all trimesters with placental ultrastructure lesions including decreases in syncytiotrophoblast microvilli and pinocytotic activity, fetal syncytial necrosis, and degenerated cytoplasmic organelles (16 & 2), Identical changes were observed at term in the placentae of women who gave up smoking early in pregnancy, implying that trophoblastic cellular alteration were irreversible<sup>12</sup>. Those finding suggest that tobacco smoking affect progressively placental development, starting with the trophoblast that in direct contact with maternal circulation.

Although the smoking habit in Iraqi women is low, but most of our histological findings on terminal villi of smoking mother were found similar to the findings observed by other

researchers on the direct effect of smoking in placenta. However, this study on local Iraqi smoking women is a first step towards understanding the dangerous effect of smoking during pregnancy. Structural changes to the placenta are considerable as compared to non smoking mothers who endanger the health and life of fetus and mother.

### Conclusion

On the bases of results of the present study, it is concluded that the normal aging process in placenta which is adaptive response to increasing work-

load as pregnancy advances can turn into histological structural changes when exposed to abnormal environment and chemical like nicotine, and carbon monoxide. These finding indicates that the high levels of tobacco exposure during pregnancy cause irreversible structural changes in the cellular function of the villous trophoblastic barrier. These changes in placenta can result in abnormal outcome of pregnancy if placenta remains exposed to such stimuli.

### References

1. Beaconsified P, Birdwood G. The placenta. Scientific American (1980); August, 80-90.
2. Demir R, Demir AY, Yinanc M. Structural changes in placental barrier of smoking mother, A quantitative and ultrastructural study. Path. Res. Prac. (1994); 190: 656-67. (Medline).
3. Olds D. L, Henderson C.R. and Tattelbaun, R. Intellectual impairment in children born to women who smoke cigarettes during pregnancy. Pediatrics. (1994); 93 : 221-227.
4. Guyton Ac. Textbook of medical physiology 8th ed. Philadelphia; WB. Saunders, (1991); PP 917-9.
5. Katzung BG. Basic and clinical pharmacology 7th ed. San Francisco Appleton and Lange, (1998); pp 90-2.
6. Hill AB, A short textbook of medical statistic, 10th ed. London; EIBS. (1977); pp 127-36.
7. Lethrovitra P, Fross M, Karinion V and, Ruuramo I. Acute effect of smoking on foetal heart rate variability. British J Obstetric Gynecology. (1983); 90; 3-6.
8. Lieberman E, Germay I, Lang J.M and Cohen A.P. Low birth weight at term and the timing of fetal exposure to maternal smoking. American journal of public health. (1994); 84: 1127-31.
9. Kerr JFR, Wylie AH, Cume AR. Apoptosis: a basic biological phenomenon with wide reneing implications in tissue kinetics. Br. J. cancer.(1972); 26; 239-57.
10. Muhhamed Ashfaq, Muhammad Zahoor, Muhhamed Nawaz. J ayub medcol. (2003); sep 15: 12-5 Abbottabad.
11. Plarrer C, Macara L, Leiser, R. and Kinkdom. J. Adaptive angiogene in placenta of heavy smoker. Lancet (1999); 534.
12. Rath, G., Jain A. K., Bastia B., Sood M. and Mukherjee A. The effects of passive smoking on the terminal villi of human placenta. J Anat, soc. India (2003); 50 (1) 19-23.
13. Burton G. J. The effect of maternal cigarette smoking on placental structure & function in mid to late gestation. Oxford medical publication. 1 992; 60-80.
14. Eric Jauniaux, Beatrice, Ganesh ,A. Erik, G. Fetal amino acid and enzyme levels with maternal smoking. Obstetrics & Gynecology (1999); 93: 680-683.
15. Lambers Ds, Clark KF. The maternal and fetal physiologic effects of nicotine. Sem Prinatol (1996); 20: 115-26.
16. Sastry Bv.; Placental toxicology: Tobacco smoke, abused drugs, multiple chemical interactions and placental functions. Reprod Fertil Dev (1991);3:355-72. (Medline).