

EFFECTS OF ETHANOLIC EXTRACT OF *TARAXACUM OFFICINALE* LEAVES ON SOME PHYSIOLOGICAL AND REPRODUCTIVE PARAMETERS OF LOCAL ADULT MALE RABBITS

Jassim M.A.Al-Kalby' AL-Saeed,M.H.,Nawras A. Alwan

Department of physiology and pharmacology, College of Veterinary Medicine,
University of Basrah,Basrah, Iraq

(Received 26February 2007,Accepted 18July 2007)

Keywords:Fertility,AST,Sperm count.

ABSTRACT

The twenty adult local male rabbits of mean body weight of 1 kgm and mean age of 6 months were randomly allocated into two groups of ten animals, each group was fed during the period of experiment on a standard diet . The first group was regarded as control and received 3ml of physiological saline orally for a month. The second group was drenched ethanolic extract of *Taraxacum officinale* (500 mg/kg/day) for one month . Those male were joined with females after treatment for a week to study the effect on fertility and reproductive efficiency. The following results were obtained:

The ethanolic extract of *Taraxacum officinale* caused highly significant increase ($p<0.01$) in AST and significant decrease ($P<0.05$) in ALT of intact treated male rabbits.The ethanolic extract has a significant decrease in the testicular weight, seminiferous tubules diameter and decrease in sperm count.The prolonged drenching of *T.officinale* extract caused infertility. Prolonged drenching of *T.officinale* extract showed clear histological changes on all organs studied (pituitary,thyroid glands and testes) as compared with control.

INTRODUCTION

Taraxacum officinale Linn belong to the family Asteraceae (compositae) (1). It has been used as food preservatives, as well as aprotective and curative remedy for numerous disorders (2). The herb is widely grown in different parts of the world such as Asia, Europe, America, Austeralia and New Zeland (3). It has a common name "Dandelion" or "lion's tooth" (4).

Phytochemical studies on *Taraxacum officinale* revealed the presence of ressin, essential oil (1), pectose enzyme, fatty acids including mellisiic and β -

hydroxyphenyl acetic acid; alkaloids; sitosterol; stigmasterol; saponin; taxasterol; homotaraxsterol; inulin; levulin; sugar and wax (5).

Dandelion leaves are high in vitamins A,B,C,D,Iron, silicon, zinc, manganese, magnesium, phosphorous, calcium and potassium (2).

In the traditional system of medicine, it is recommended in a wide range of ailments including infections (both fungal and bacterial) (6). In rheumatism (7). Gastro-intestinal problems like dyspepsia, flatulence, loss of appetite (8). It has also been used as diuretic stimulant. It was also used as laxative; antiarthritic; against eczema and in liver disorders (8). Dandelion's bitter compounds increase the gall bladder's production of bile. This improves the liver function and body's metabolism of fat. The popularity of the plant was highly enhanced by ideological belief in the herb as a cure for multiple diseases. In fact, this plant had occupied special place for its wide range of medicinal value in the Islamic civilization, due to the saying of the Holy prophet, Mohammed (peace be upon him) that the plant is full of medicinal values (9). It gained immense popularity.

Consequently, dandelion has been extensively studied particularly in the Islamic world, which justifies its broad traditional therapeutic values. It was found to have antimicrobial (6), hypoglycemic (10), anti-inflammatory and renal protective properties (8).

This study aimed to study the cholesterol inhibitory effect of *Taraxacum officinale* and also to find their effect on serum enzymes and to explore their effect on reproductive efficiency and on structural characteristics of pituitary-thyroid-testes axis of adult local male rabbits compared with intact adult male rabbits control.

MATERIALS AND METHODS

Preparation of ethanolic herbal extract: The ethanolic extract of *Taraxacum officinale* leaves was prepared by taking 50 g of dried leaves which were obtained from local garden at Basrah, powdered and combined with 500 ml of ethanol, this combination was concentrated below 50 °C under reduced pressure in arotavapour to get the ethanolic extract (11).

Experimental animals:

Twenty healthy adult local male rabbits of mean body weight of 1 kg and mean age of 6 months were housed in individual cages in a room with constant humidity

and temperature about (22±2°C) under 12 hour light to dark cycle and fed for one week on standard diet and tap water *ad libitum*. The animals were randomly divided into two groups , ten animals each.

The first group was regarded as control which were received 3ml of physiological saline orally for each animal by gastric tube daily for one month. The second group was drenched ethanolic extract of *Taraxacum officinale* leaves (500mg /kg/day) for one month dissolved in 3ml of physiological saline.

For fertility study, male rabbits caged for 7 days with females of proven fertility in a ratio of 1: 2. Vaginal smears were examined every day morning after the period of joining and the day of presence of spermatozoa was regarded as day 1 of pregnancy as described by (14). Mated male rabbits were randomly distributed into various groups and treated orally with the tested extract for 30 days post coitus.

Measurement of serum AST, ALT activity and cholesterol level.

Blood samples were collected from each animal at the end of the experiment to separate the serum to measurement of aspartate amino transferase (AST) , alanine amino transferase (ALT) activity and cholesterol level by using special kits and spectrophotometer on length wave 540nm as described by (Reitman, and Frankel, 1957).

After that female animals of each treated group and controls were killed and the pituitary, thyroid glands and testes were removed to get their weights then were kept in 10% formaline for fixation to be ready for histological

Statistical analysis:

Data were analysed by one way analysis of variance ((ANOVA)) test.

RESULTS

A.Effect of ethanolic extract of *Taraxacum officinale* on some enzymatic activity and cholesterol level in intact male rabbits.

The influence of prolonged oral administration of ethanolic extract of *Taraxacum officinale* on the enzymatic activity and cholesterol level are demonstrated in table (1). The results showed that the ethanolic extract of the plant used caused highly significant increase ($p \leq 0.01$) in serum (AST) level, whereas contrary effect of the extract was seen with ALT. It seems that the extract caused significant decrease

($p \leq 0.05$) of the (ALT) enzyme in the intact treated rabbit . Results in table (1) also showed that drenching ethanolic extract of *Taraxacum officiale* caused highly significant decrease ($p \leq 0.05$) in cholesterol level of intact rabbits compared with control.

Table (1): Effect of ethanolic extract of *Taraxacum officiale* on some enzymatic activity and cholesterol level in intact male rabbits. (N=10)

Treatment groups	AST (IU/L)	ALT (IU/L)	Cholesterol mg/100ml
Control (normal saline) to intact animals	8±0.52	10.5±1.24	235±0.36
500 mg/kg/day of <i>Taraxacum officiale</i> to intact animals	29.2±3.10**	7±0.10*	135.1±0.32**

**=($P < 0.01$) ,*=($P < 0.05$), N=number of animals

B-Effect of ethanolic extract of *Taraxacum officiale* on reproductive efficiency of male rabbits.

The influence of prolong oral administration of ethanolic extract of *Taraxacum officiale* on reproductive efficiency are demonstrated in table (2). Results showed that the drenching ethanolic extract of *Taraxacum officiale* negatively affected male rabbits and caused their reproductive efficiency reach zero (infertility).

Table (2): Effect) of ethanolic extract of *Taraxacum officiale* on some reproductive parameters (N=10)

Treatment groups	No. of new borns	Weight of new borns	Mal formation	Mortality rate	No. of pregnant females	Fertility rate (%)
Control (normal saline)	4.33 ± 0.5	23.83 ± 1.16	0	0	20	100%
Treatment (<i>taraxacum officinale</i>)	0	0	0	0	0	0%

N=number of animals

C- Effect of ethanolic extract of *Taraxacum officiale* on testicular weights.

The influence of prolonged oral administration of ethanolic extract of *Taraxacum officinale* on weights of testes are demonstrated in table (3). The results showed that the ethanolic extract had high significant decrease ($p < 0.01$) on weights of both testes of male rabbits.

Table (3): Effect of ethanolic extract of *Taraxacum officinale* on testicular weights of intact male rabbits. (N=10)

Treatment groups	Weight of left testes (gm)	Weight of right testes (gm)
Control (normal saline)	1.85±0.05	1.95±0.02
Treatment (<i>taraxacum officinale</i>)	0.63**±0.05	0.75**±0.08

** = ($p < 0.01$) , N=number of animals

D. Effect of ethanolic extract of *Taraxacum officinale* on epididymal spermatozoa.

Table (4): Effect of ethanolic extract of *Taraxacum officinale* on epididymal spermatozoa characteristics. N=10

treatment	Studied characters					
	Viability%	Sperm count $\times 10^6$	Intact sperms(%)	Live sperms(%)	dead sperms(%)	abnormal sperms(%)
Control	90.00 \pm 2.24	210.30 \pm 1.67	80.65 \pm 1.47	75.11 \pm 3.74	27.04 \pm 3.21	15.34 \pm 1.41
treatment	34.16 \pm 2.38*	90.50 \pm 0.42*	63.82 \pm 2.80*	24.50 \pm 2.12*	75.40 \pm 4.12*	41.01 \pm 2.78*

*= (p<0.05).

Table (4) demonstrates that ethanolic extract of *Taraxacum officinale* caused significant decrease (p<0.05) in all characters of epididymal spermatozoa compared with control group.

D- Histological changes produced by ethanolic extract of *Taraxacum officinale*:

1. Effect on pituitary gland:

The pituitary gland of control group represented by numerous sinusoidal capillaries which are seen in pars anterior as well as normal groups of chromophobes cells and normal capsule. There are predominance of acidophilic and basophilic cells (figure 1), but groups received the extract of *Taraxacum officinale* showed several histological changes such as decreased number of chromophobes with less number of sinusoidal capillaries in addition to presence of empty spaces between the tissue structures; those changes may lead to pituitary insufficiency caused by hypopituitarism (figure 2).




Figure (1): Section of pituitary gland of control group showing 1.chromophobes 2.sinusiod capillaries (400X) H&E. stain.




Figure (2): Section of pituitary gland of group drenched ethanolic extract of *T. officinale* for 30 days showing (1- decreased number of chromophobes 2- less number of sinusoidal capillaries 3- presence of empty spaces between tissue structures). (400X) H&E stain.

2-Effect on thyroid gland:

The thyroid gland of the control group showed a large number of follicles of different sizes. These follicles are filled with colloid which takes the acidophilic stain (fig. 3).

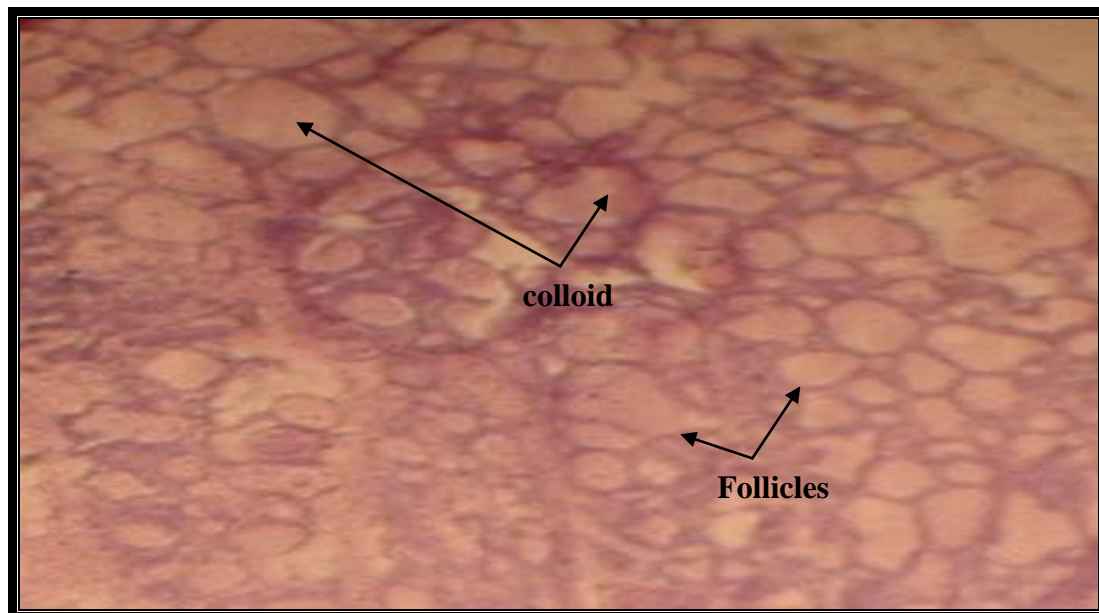


Figure (3): Section of the thyroid gland of the control group showing: Large number of the thyroid follicles filled with colloid (100X) H&E stain.

Thyroid gland of intact animal group treated with 500 mg/kg/day *T. officinale* for 30 days shows: 1- different sizes of thyroid follicle 2- filled with colloid 3- interlobular connective tissue 4- presence of fibrous tissue .

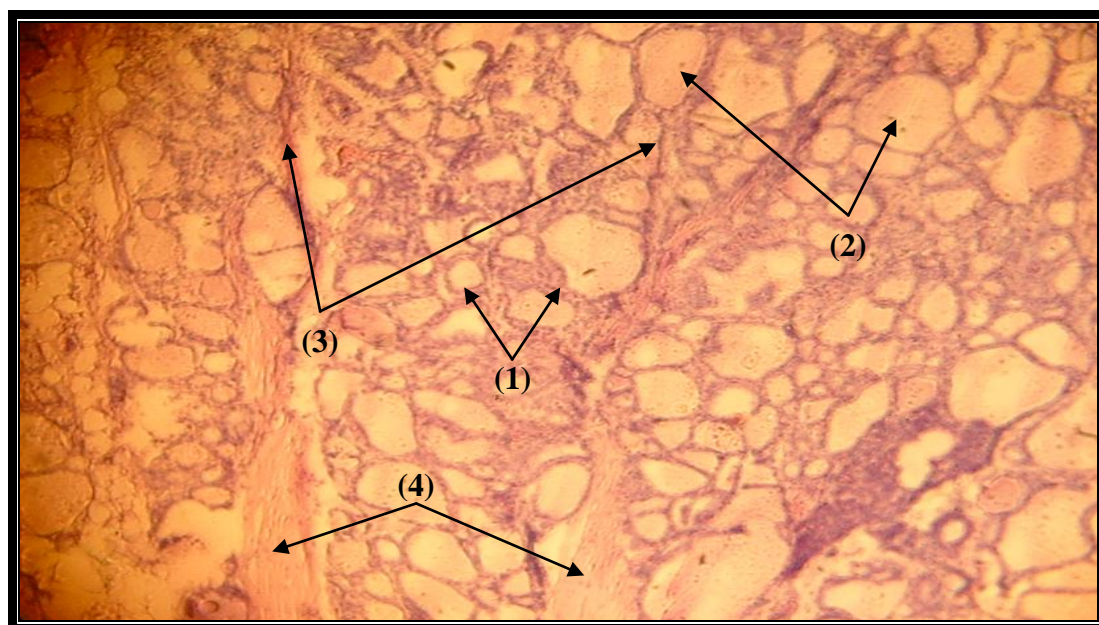
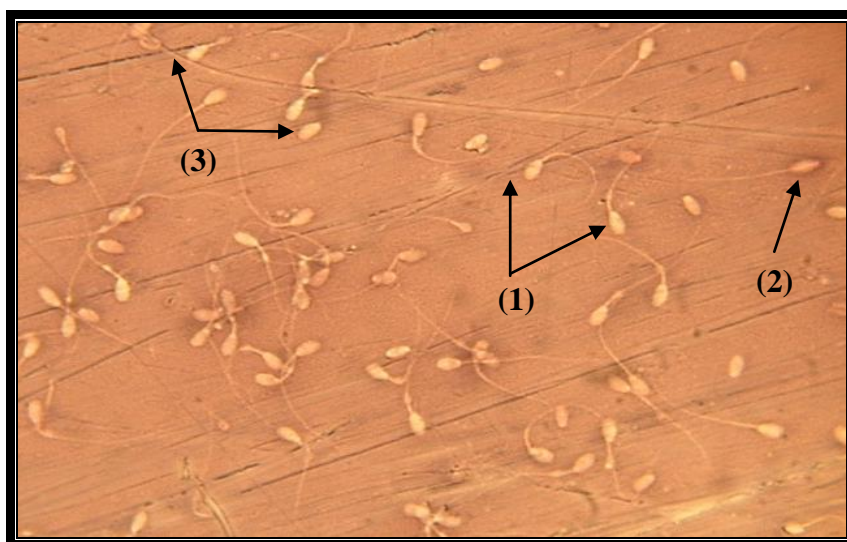


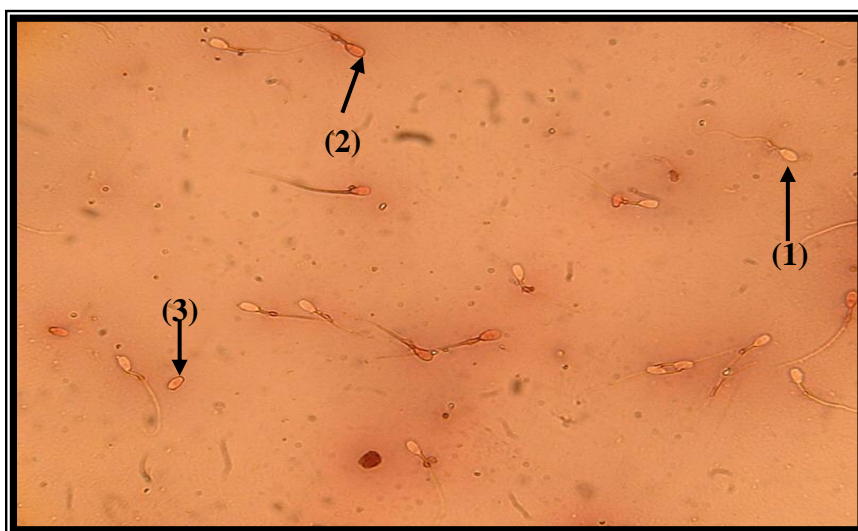
Figure (4): Section of the thyroid gland of the animal treated with *T. officinale* (100X) H&E stain.

3- Effect on epididymal spermatozoa

The effect of ethanilc extract of *Taraxacum officinale* on sperm charcters illustrated in figure (6) and table (4) . There was marked decrease ($P<0.05$) in viability, sperm count, intact sperms and livesperms and significant increases ($P<0.05$) in dead and abnormal spermatozoa compared with control group.



Figure(5) :Spermatozoa of control group showing(1. Live spermatozoa 2. Dead spermatozoa 3. Abnormal spermatozoa). (400x) eosin&nigrosin stain.



Figure(6):Spermatozoa of rabbit male treated with *T.officinale* extract, showing(1. Live spermatozoa 2. Dead spermatozoa 3. Abnormal spermatozoa). (400x) eosin & nigrosin stain.

4- Effect on the testes:

histological section of the testes of control group showing normal seminiferous tubules(ST), spermatogonia(sp), primary spermatocytes (ps) and secondary spermatocytes (ss) and leydig cells (interstitial cells) (LC) (fig. 7)

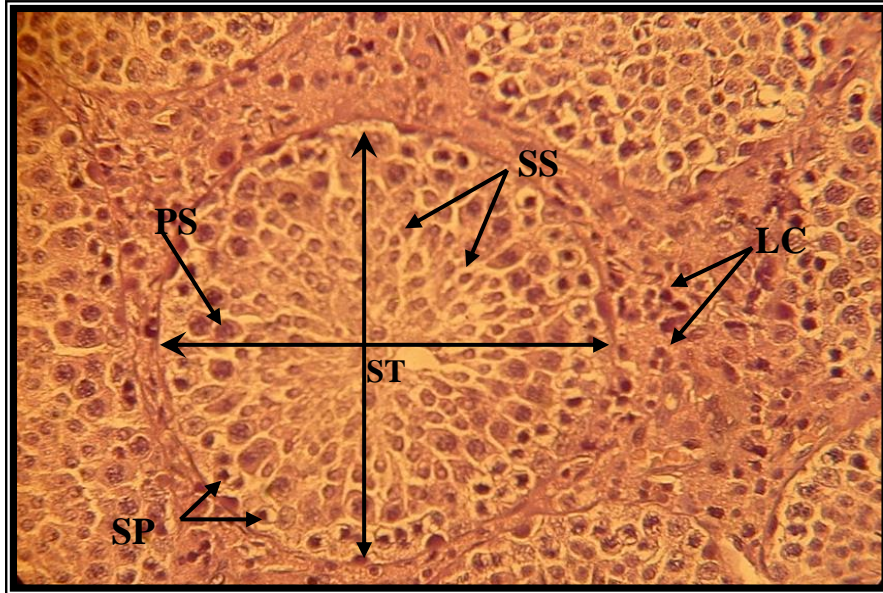


Figure (7): section of testes of anormal control group.(400x)E&H stain .

Histological section of treated testes, shows vacuolation in spermatogonia (VS), decrease number of leydig cells (LC) and degeneration of seminiferous tubules (ST) (fig. 8).

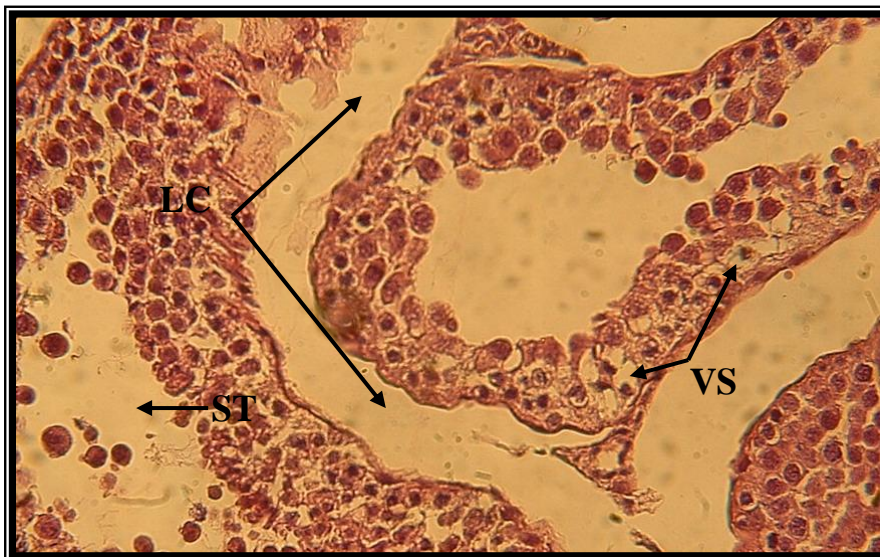

Figure (8): Section of testes of treated animals (400X) H&E stain.

DISCUSSION

The obtained results showed that ethanolic extract of *taraxacum officinale* has significantly increased activity ($p < 0.01$) of serum aspartate amino transferase (AST) and significantly decreased activity ($p < 0.05$) of serum alanine amino transferase (ALT) of intact male rabbits ; these effects may be attributed to the influence of the extract and drug on the heart and liver. These effects on enzymatic activity may be related to the alkaloid and saponin content of the used plant (*T. officinale*) which may affect liver and heart, so they may have caused the changes in the enzymatic activity found in this study. These results are in agreement with findings of (12) which found that thymus capitatus could affect the enzymatic activity due to their content of alkaloids and saponin. The effect of *taraxacum officinale* on cholesterol may be attributed to the chemical components of the studied plant which may conjugate with bile acids in the intestine which can inhibit the action of bile acids with fat content of the food leading to increase the excretion of those bile acids with waste products and thus stimulate the conversion of cholesterol to bile acids in the liver; these findings are generally agreed with previous studies on other plants such as (*Allium sativum*) (13,14 and 15). Those authors had suggested the inhibitory effects of garlic on serum total cholesterol which may be due to an inhibitory effect of this plant on cholesterol synthesis.

The obtained results denoted in this study that significant decrease testicular weight of male rabbits treated with ethanolic extract of *T.officinale* and decrease seminiferous tubules diameters compared with control group lead to loss their fertility due to their effects on pituitary gland and thyroid glands which reflects the effects on testes of treated male rabbits because all these organs are in the same axis. Those results were observed through gross and microscopic changes in the studied organs which clearly noticed in figures 1-8; those results and changes certainly lead to disturbances in gonadotropins from pituitary (FSH) and (LH) which in turn lead to disturbances hormones of testosterone secreted from affected testes (Leydig cell) resulting in clear changes in the spermatogenesis and decrease sperm count due to inhibition of sperm production from seminiferous tubules. Shown in figures illustrated in the results; those changes resulted in a 100% loss of fertility of those treated males compared with the controls. This result may be due to content the extract of *T. officinale* affected on most metabolism activity of body and lead to decrease energy, the energy

according important factor in process of reproductive (17), may be disturbance of hormone testosterone by affected of pituitary gland lead to decrease metabolism of general body or decrease metabolism of sperm cells(17). Several authors mentioned that athanolic extract of *T. officinal* contain phenoles; alkaloids and saponin and those contain may affect the reproductive efficiency. These results are in agreement with that of (16) when found that phenole compound in gossypol acetic acid had number of effects on reproductive physiology of mammals and affecting fertility and sterility of both male and female due to toxic effects on early formed embryos as well as its spermicidal effects .

تأثير المستخلص الكحولي لنبات الهندباء البري في بعض المعايير الفسلجية و التناسلية في ذكور الأرانب المحلية البالغة

جاسم محمد أحمد الكلي) منى حميد محمود السعيد نورس عبدالاله علوان

فرع الفسلجة، كلية الطب البيطري، جامعة البصرة، البصرة، العراق.

الخلاصة

تم إجراء هذه الدراسة على عشرين ذكراً من الأرانب المحلية البالغة الخالية من الأمراض سريريا بمعدل وزن 1 كغم ومعدل عمر ستة أشهر، وزعت عشوائياً إلى مجموعتان كل مجموعة احتوت على عشر ذكور . غذيت جميع المجموعات طيلة فترة التجربة على عليقة قياسية . اعتبرت المجموعة الاولى كمجموعة سيطرة أو مقارنة وجرعت 3 مللترات من المحلول الملحي الطبيعي لمدة شهر وجرعت المجموعة الثانية الخلاصة الكحولية لأوراق نبات الهندباء البرية بواقع 500 ملغم/كغم/اليوم لمدة شهر كامل . وضعت جميع ذكور التجربة في الأسبوع الأخير منها مع إناث خصبة لغرض دراسة تأثير المعاملات المختلفة على الخصوبة والكفاءة التناسلية لذكور أرانب التجربة.

توصلت الدراسة إلى أن الخلاصة الكحولية لأوراق نبات الهندباء البرية أدت إلى ارتفاع معنوي ($p \leq 0.01$) في مستوى أنزيم AST وانخفاضا معنوياً ($p \leq 0.05$) في مستوى ALT في مصل الدم. أن التجريع الطويل الأمد لمستخلص الايثانول لأوراق نبات الهندباء البرية أدى إلى توقف خصوبة ذكور الأرانب (عدم حصول الحمل) وانخفاضا معنوياً ($p \leq 0.05$) في أوزان خصي ذكور الأرانب مصحوباً بانخفاض معنوي في تركيز النطف في مجموعة الحيوانات المعاملة . أن التجريع الطويل الأمد لمستخلص الايثانول لأوراق نبات الهندباء البرية لذكور الأرانب أدى إلى حدوث تغيرات واضحة في التراكيب النسيجية لجميع الأعضاء المدروسة (النخامية- الدرقية- الخصي) مقارنة بأعضاء مجموعة السيطرة.

REFERENCES

- 1- **Simon, J.E.(1990).** Essential oil and eulinary herbs. P.P: 472-483. In Janick, J. And Simon, J.E. (1993).(eds). New crops. John Wiley & Sons, Inc.
- 2- **Akeel, M. (1996).** Teb Al-emam Ali. 1st edition, Dar Al-Mahaga "El-bedaa" for press, Burit, Lebanon, P.P:100-105. (in Arabic).
- 3- **Al-Rawi, A. and Chakravarty, H.L.(1964).** Medicinal plants of Iraq. Ministry of Agriculture, Baghdad, Iraq.
- 4-**Saad, S.I. (1975).** Classification of flowering plants. 2nd edition. The General Egyption Book Co. Alexandria.
- 5-**Nassimy, M.N. (1984).** The prophetic Medicine " Al Teb Al-Nabawy and moder medicine, vol. III, 1st edition. The United Comp. For dist. Damascus, Syria.
- 6- **Cowan, M.M. (1999).** Plant products as antimicrobial agents. Clinical Microbiology Reviews, P.P:564-582.
- 7- **Rawaiha, A. (1978).** Herbs therapy. 5th ed., Dar Al-Kalam for press, Burit, Lebanon. (in Arabic).
- 8- **Al- Maiyah, A.A. (2001).** Moder plant taxanomy. 1st ed. Central for press, University of Basrah-University of Taez. (in Arabic).
- 9- **Al-Bukhari, A. (1976).** " Collection of authentic prophetic saying, Division 71 (the book of Medicine). Chapter 7" published by Hill Yayinlari, Ankara, Turkey, 2nd edition.
- 10- **Brinker, F. (1998).** Herb contraindications and drug interaction. . 2nd sandy, OR: Eclectic Institute Inc.
- 11- **Harborne, J.B. (1984).** Phytochemical methods. Chapman and Hall, London, O.K., P.P.:566-568.
- 12- **Kandil, O.; Radwan, N.M.; Hassan, A.B.; El-Banna, H.A. and AZIZA, N.M. (1993).** Toxicity of some plants. Vet.Med.J. Giza, vol. 14, No.2:9-14.
- 13- **Gebhart, R. (1993).** Multiple inhibitory effect of garlic biosynthesis in hepatocytes. Lipids, 28:613-619.
- 14- **Al-kakey, I.S. (1999).** Effect of some hypoglycemic plants on lipid peroxidation, glutathione content and certain biochemical aspect in normal and alloxan diabetic male rabbits. Ph.D. Thesis. College of Science. University of Mousl.
- 15- **Yeh, Y.Y. and Liu, L. (2001).** Cholesterol- lowering effect of garlic extracts and organosulfur compounds: Human and animal studies. J.Nutr., 131:989S-993S.

- 16-Montomat, L.A.; Fag, C.A. and Petra, O.M. (1982).** Effect of cotton extract on sperm morphology. *Andrologia*, 52:101-105.
- 17-Ihen,G .S.; Ye, Y. &Wei, Z.J.(1995).** Recent progress in research on Trpteryginm a male antifertility plant. *Contraception* 2:121 -9.(abstract).
- 18- Reitman, and Frankel, S (1959);** Colorimetri method for the determination of serum glutamic oxaloacetic and pyruvic transaminase ; *Amer. J. Clin. Path.*, 28 : 56 – 63.