

## **MIXED PARASITIC INFECTION ON NATIVE MOUNTAIN GOATS ( BIG HORNE GOATS) OF DOHUK AREA**

Al-nakshabandi, A. A. , Al- bayati S. M.

College of veterinary medicine University of Dohuk , Dohuk , Iraq

(Received 4 November 2007, Accepted 18 November 2007)

**Keywords:** Sarcocystosis, Anorexia, Goat

### **BSTRACT**

Horne goat of the north mountains of Iraq (Kurdistan – Iraq) Big one of the little wild ruminants seen in this area. Several captured heads of these animals suffering from severe dramatic changes in their health like anorexia, hyperthermia and common depression followed by death. The post mortem investigation showed a mixed parasitic infection ( Sarcocystosis , Hydatid cyst disease and Hydatigenosis ) which registered for the first time in that animals and in that region which have a healthy and epidemiological importance .

### **INTRODUCTION**

The wild ruminants of mountain became to be one of the rare founded Animals especially in the north of Iraq (Kurdistan –Iraq) because of the general situation in that area. One of these ruminants is the Big -Horne goat (Fig. 1). These animals severely hunted to reach near the extinction .

This study investigate the mixed parasitic infection in that hunted Animals for the first time in Iraq.

### **MATERIALS AND METHODS**

1- Animals: Several big Horne goat animals( six heads ) which seen to be older than two years (depending domestic goat dentition), and captured in the animal zoo of Dohuk (governorate in the north of Iraq). Suffer from hyperthermia ( near 41.5 C ) with obvious engorged in the sclera blood these animals showed a clinical signs of anorexia for 2 days , vessels and common depression ( reduce in the activity and careless signs) , followed by death (naturally or by emergency slaughter) for the period of 3ed to 4thed months of the year 2007.

The killed animals investigated for the possible cause of those cases by using routine post mortem (P.M.) methods.

2- Specimens and methods: The carcasses open at the chest and abdominal cavity and within organs examined for the presence of more expected parasitic infection (in concerned to lung, liver and G. I. T.) and photographed.

Samples of these organs were taken by cutting 0.5 – 1 cm of infected area and putted on 10% Formalin solution for histological techniques (1), and fresh samples (20-30 gm ) of these organs taken for further lab. Exam by Trichinoscopy(2 ) and squeezing (7) .

## RESULTS

The all big Horne goats ( Fig 1 ) seen to be infected with mixed parasitic infections as follow while there is no ectoparasite observed :

1- Sarcocystosis : The esophagus of dead animals showed the macrocytic ( seen by naked eye ) and microcytic cyst of *Sarcocystis* spp.

( Fig 2 ) as in used of trichinoscopy .

The squeezing method release the cystozoites( Fig. 2 ) from the microscopically cysts .

The normal histotechniques by using H & E stain showed the microcysts

(Fig 4 ) with distance of 10 x 30 micrometer .

2-Hydatid cyst of *Echinococcus granulosus* : the lungs of the dead animals showed to be severely infected with hydatid cysts . The cysts seen as a unilocular with a central fluid – filled cavity lined by a thin layer which could be represented the germinal layer and surrounded by fibrous tissue capsule ( Fig 5 ).

3- Hydatigenosis : Several *Cysticercus tenuicollis cysticerci* cysts (Fig 6) which is the larval stage of *Taenia hydatigena* , and seen to be hanged in the marginal border of the liver and the insider face of the abdominal cavity. The cyst of *C. tenuicollis* when open seen to contain a thin – walled bladder with single scolice and filled with clear fluid .

## DISCUSSION

1- The big Horne goats of current study could be identified as a separated species or may be subspecies of genus *Capra ibex* found in rugged country on mountain ranges from central Asia to the Himalayas, S Europe, and NE Africa as defined by the Columbia Encyclopedia(3, 4 ) which could be refer as *Capra ibex kurdstani* because it have special characters make it differ from American , Siberian , Himalayan , Spanish, Alps , and Ethiopian .

2- the sarcocystosis resemble results of previous studies ( 5 , 6 ) when they found that sarcocystosis in native goats is distributed very widely .the study agreed with al-bayati (7 ) for squeezing method and histological ( 5 , 7 ) study for the occurrence of parasite cysts, cystozoites liberated from cyst

3- Hydatidosis agreed with previous studies ( 8 , 9 ,10 ,11 ) in the occurrence of hydatid cyst within or hooked to liver and lungs which explain the mode of infection via blood vessels through penetration of intestine layers by embryo freed from hexacanth ovum ingested by intermediate host in grassing . the unilocular hydatid cysts may be related to the species of parasite occur in area , where the difference in size and volume of hydatid fluid could be attributed to various stage and time of infection as well as re infection for several times .

4- *Taenia hydatigena* infection which related to *Taenia hydatigena* , agreed with previous studies (12 ,13 , 14 , 15 ,16 ) and seen with current study to have typical appearance as the cyst hanged with internal face of the upper abdominal cavity or attached to liver with various size and volume but all with singled elongated head ( 3-5 X 1-2 mm) . That variation may reflected the different time of infection with parasite which lead to different growth rate.

## CONCLUSION AND RECOMMENDATION

The big Horn goats of Kurdistan region as it rare founded small wild Ruminants( and could be represented a separated sub species of *Capra ibex* ) suffer from several parasitic infections some of it have zoonotic importance as that seen for the first time with this study.

Sarcocystosis , Hydatidosis and Taenia hydatigeneosis registered for the first time with these animals and all have related to human health as they are very important to the epidemiological aspects .

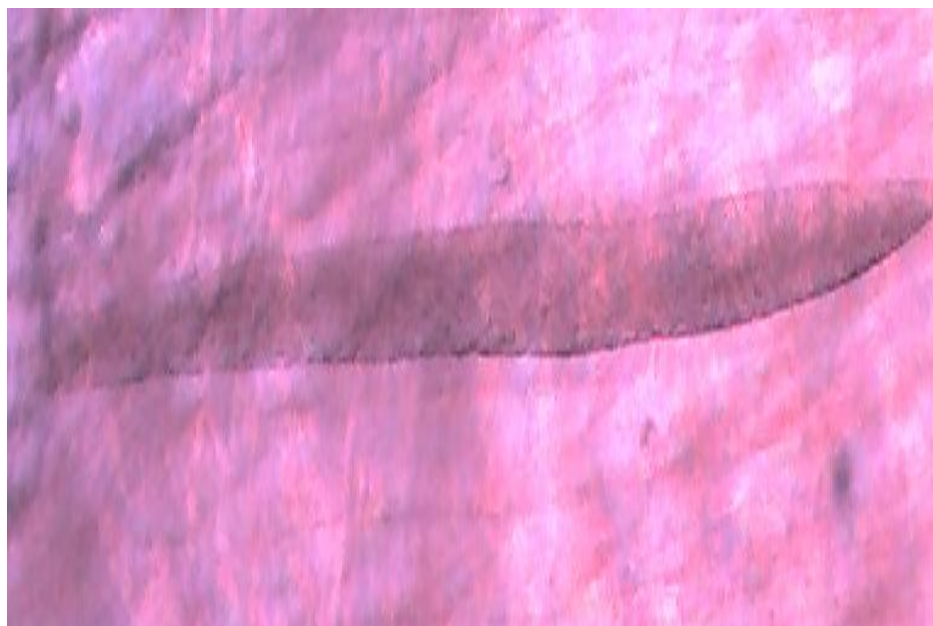
The big Horn goats of Kurdistan need to be investigated widely for its Biology and diseases because of its importance at various level of interests .

## ACKNOWLEDGEMENTS

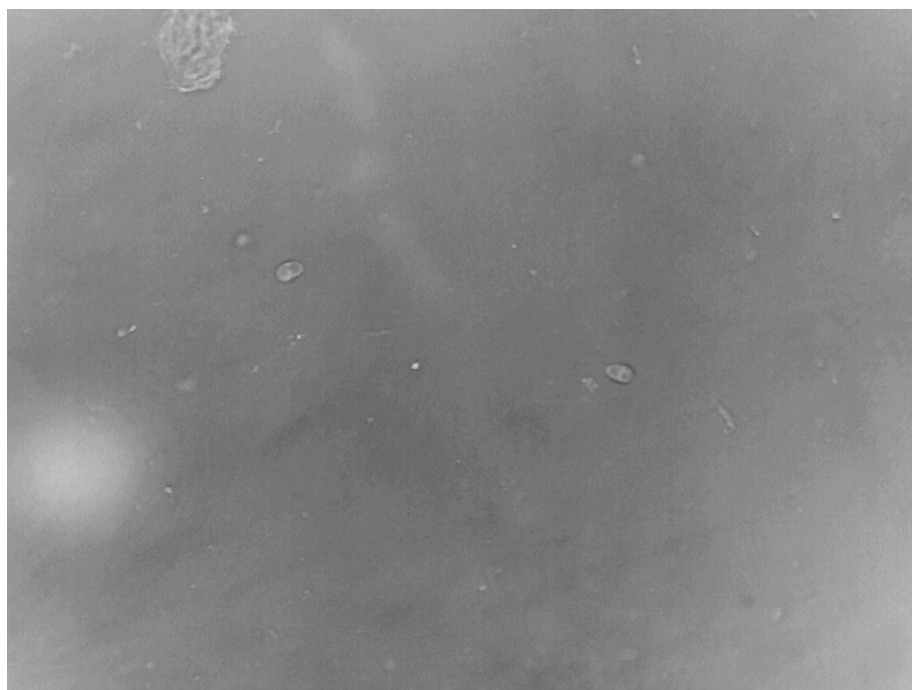
Many thanks for zoo animals administrator for helping to keep hunted animals in Dohuk governorate / Kurdistan-Iraq .



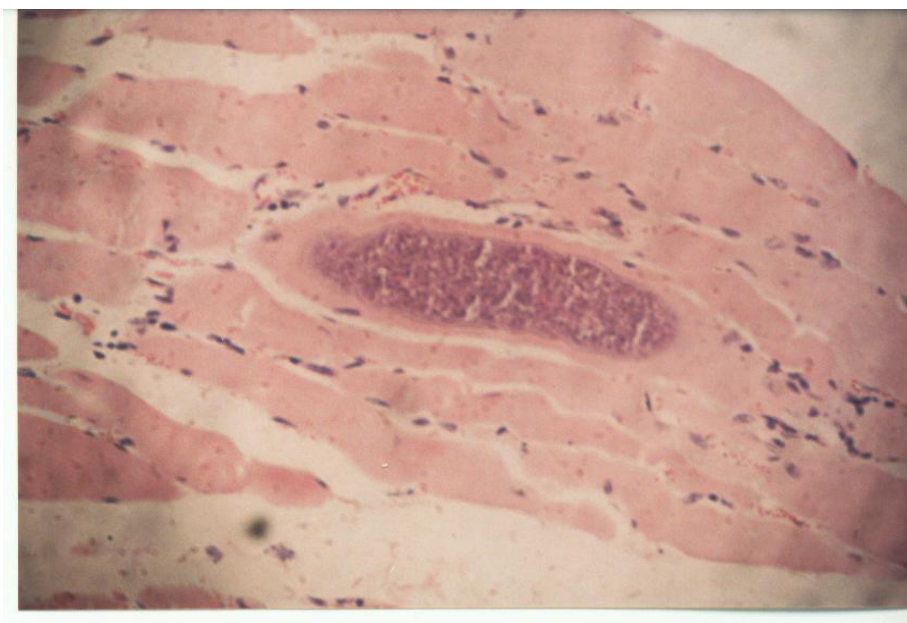
**Fig. (1) :** The big Horn goat of Kurdistan ( *Capra ibex kurdistani* ?)



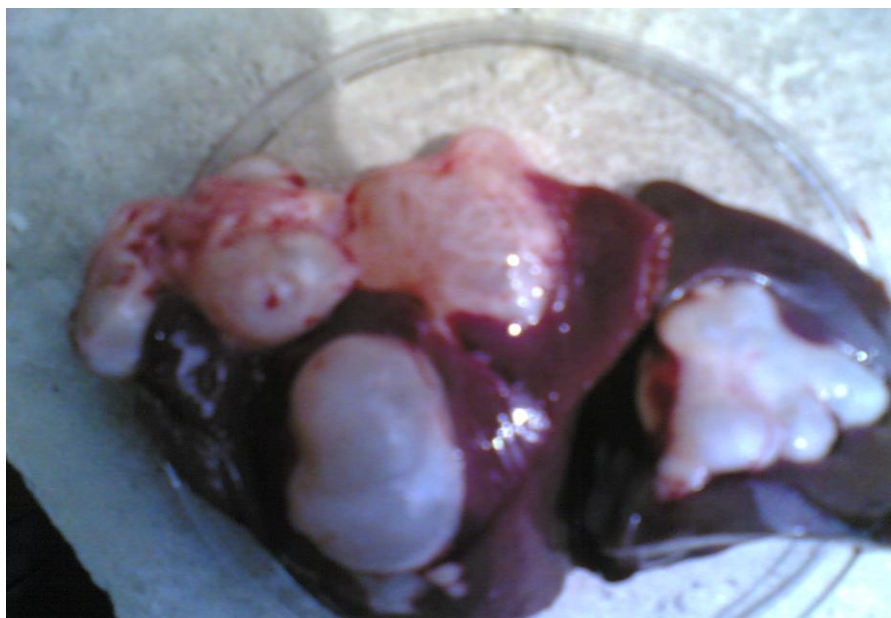**Fig. (2) :** The *Sarcocystis* spp. Cyst by Trichinoscopy ( X 10 )

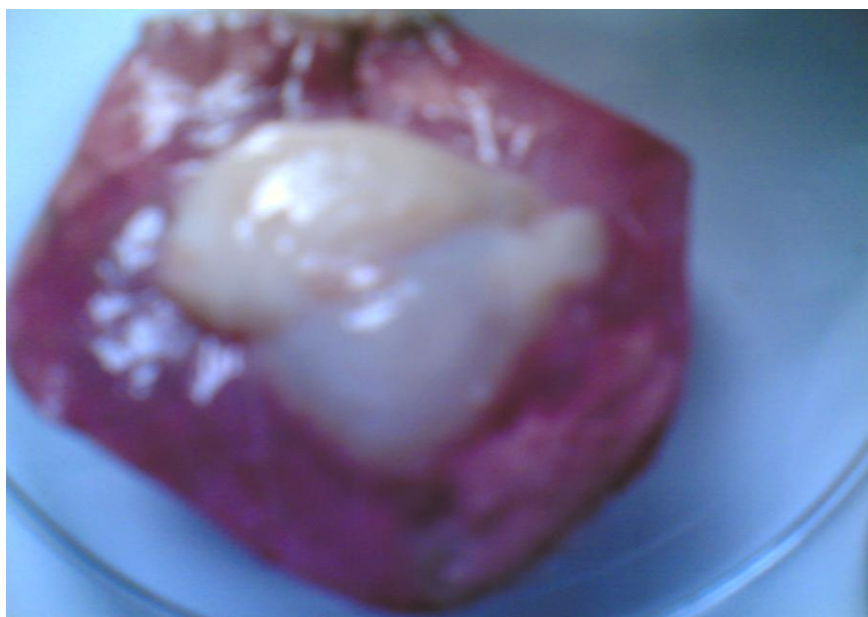


**Fig. ( 3 ) :** The cystozoites of *Sarcocystis* spp. Cyst by squeezing method ( X 40 ) .




**Fig.(4) :** The *Sarcocystis* spp.by histological ( H & E ) technique (X10).





**Fig.(5) :** The hydatid cysts of liver ( upper ) and lung (down )from Big Horne goat.



**Fig.(6) :** The *Cysticercus tenuicollis* cysticerci (bladder ) of *Taenia hydatigena* From big Horne goat ( clear single scolex seen ) .

## الاصابة الطفيلية المختلطة في الماعز الجبلي المحلي ( الماعز ذو القرون الكبيرة ) في منطقة دهوك

اصيل انور النقشبندي ، سعد محي البياتي  
كلية الطب البيطري ، جامعة دهوك ، دهوك، العراق

### الخلاصة

ان الماعز الجبلي للجبالي الشمالية في العراق ( اقليم كردستان ) والذي يعد واحدا من المجترات الصغيرة النادرة في تلك المنطقة اظهر في عدد منها والتي تم اصطيادها حديثا انها تعاني من تغيرات امراضية شديدة مثل القهم وارتفاع الحرارة والخمول العام متبوعا بالهلاك واطهر فحص مابعد الهلاك ان الحيوانات تعاني من اصابة طفيلية مختلطة ( داء الحويصلات السنوبرية وداء الاكياس المائية وداء الكيس المائي وحيد الروؤيس ) والتي تم تسجيلها لأول مرة في هذه الحيوانات وفي هذه المنطقة ولهذا اهمية صحية ووبائية .

### REFERENCES

- 1- Drury , R.A.B. and Wallington , E.A. ( 1980 ) . " Carleton s histological technique " , 5<sup>th</sup> ed. , Oxford University Press,UK.
- 2- Daoud , I. S. ( 1976 ) . Studies of some factors governing survival of sarcocystosis . M. Sc. Thesis , Liverpool University , UK.
- 3- Hatter , I. ; Harcombe , G. ; Stanlake , L. ; Bethune , A. and Blood , D. A. (2000) . Big Horne sheep in British Columbia , In : The electronic Encyclopedia , 6<sup>th</sup> ed. ( 2003 ) . Columbia University Press.
- 4- Weinberg, P.J. ; Fedosenko , A . k. ; Arabuli , A. B. ; Myslenkov ,A.V. ; Romashin , A. V. ; Vdoshina , I. V. and Zheleznov , N. K. ( 1997 ) . The commonwealth of independent states ( former USSR ) pp. : 172 – 193 , in ; Shackleton , D . M. (ed.) and IUCN / SSC aprine specialist group : Wild sheep and goats and their relative. IUCN, Gland. Swiss.
- 5- Barham , M.; Stutzer , H . : Karanis , P. ; Latif , B. M. and Neiss , W.F. (2005 ) . Seasonal variation in *Sarcocystis* species infection in goats in northern Iraq . , Parasitol., 130 : 151- 156 .
- 6- Markus , M.U. ; Van Derlugt , J.U. and Dubey , J . (2004 ) . Sarcocystosis , In : Coetzer , J.A.W. ; Thomson , G. R. ; Tustin , R. C. and Mriek , N . P. J. , " infectious disease of livestock with special reference to Southern Africa , Oxford University Press . Southern Africa , Ni city , South Africa .
- 7- Al-bayati, S. M.(1993 ) Study in the epidemiology of bovine sarcocystosis in Baghdad area . Thesis , M. Sc., University of Baghdad , Baghdad , Iraq.

- 8- Latif , B. M. ; Al- delemi , J. K. ; Mohammad , B. S. ; Al- bayati, S. M. and Al- amiry , A.M. (1999) . Prevalence of *Sarcocystis* spp in meat- producing animals in Iraq . , Vet. Parasitol. , 84 : 85 – 90 .
- 9- Franco-Paredes , C.; Nicolls , D. ; Kempker , R. ; Dismuke , R. and Kozarsky , P. (2006) . Pelvic Echinococcosis in a northern Iraqi refugee., J. of Travel Medicine , 13(2) : 119 – 122 .
- 10- Ahmed , S. ; Nawaz, M . ; Gul ,R. Zakir , M . and Razzaq , A . (2006) . Some epidemiological aspects of hydatidosis of lungs and livers of sheep and goats in Quetta , Pakistan . , Pakistan J. of Zoology , 38 ( 1 ) :20 – 26 .
- 11- Mwambete , K. D. ; Ponce-Gordo , F . and Cuesta – Bandera , C . ( 2004 ) . Genetic identification and host range of the Spanish strains of *Echinococcus granulosus* . , Acta Tropica , 91 ( 2 ) : 87 – 93 .
- 12- Sharkhw , T . (2000) . Helminths of goats in Mongolia . , Vet. Parasitol. , 101 :161 – 169 .
- 13- Rafar , M . H.; Tajalli , S . and Jalalzaden , M . ( 2005) . Prevalence and morphology characterization of *Cysticercus tenuicollis* ( *Taenia hydatigena cysticerci* ) from sheep and goats in Iran . , *Veterinary Archiv* . , 75 ( 6 ) : 469 – 476 .
- 14- Dada , B.J.E. and Belino , E.D. (1978) . Prevalence of hydatidosis and cysticercosis in slaughtered livestock in Nigeria . , Vet. Rec . , 103 : 311-312 .
- 15- El – Azazy , O.M. and Fayek , S.K. (1990) .Seasonal pattern of *Fasciola gigantica* and *Cysticercus tenuicollis* infection in sheep and goats in Egypt ., Bull. Anim. Hlth .Prod. Afr. , 38 : 369 – 373 .
- 16- Varma , T.K. and Ahluwalia , S.S. (1986) . Some observation on the prevalence and variation in the morphology and biology of *Cysticercus tenuicollis* of sheep , goats and buffalo origin . , Indian J. Anim. Sci. , 56 : 1135 – 1140 .