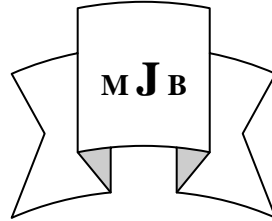


Possible Adverse Cutaneous Effects in Patients Taking Imatinib Mesylate (Gleevec) in Treatment of Chronic Myeloid Leukemia (CML) and Gastro Intestinal Stromal Tumors (GISTs) at Hilla City

Mohammed K. AL – Hattab

College of Medicine, University of Babylon, Hilla, Iraq.

E-mail: alhatab68@yahoo.com



Received 1 April 2013

Accepted 20 May 2013

Abstract

Imatinib mesylate (gleevec) is a drug that used to treat certain cancers. Sixty – two patients with CMLs and GLSTs received gleevec capsules as a chemotherapeutic treatment were studied.. These patients developed one of the following cutaneous diseases mainly as an adverse cutaneous reaction to gleevec therapy for malignant diseases or as an association with it. Melasma (19.3%), Eczema or dermatitis (14.5%), Acne – form rash (12.9%), Folliculitis (9.7%), Erythema nodosum (6.4%), Erythema multiforme (4.8%), Pruritus (4.8%), Pityriasis rosea(3.2%), Psoriasis (3.2%), Chronic urticaria (3.2%), Xerosis of skin (3.2%), Vitiligo(1.6%), Beau's lines of nails (1.6%), Cheilitis (1.6%), Common warts (1.6%), Herpes zoster (1.6%), Tinea incognito (1.6%),Lichenification (1.6%), Prurigo simplex (1.6%) and Palmar keratoderma (1.6%).From this study, gleevec was reported for the first time to cause or trigger the following adverse effects: seborrheic dermatitis , acne – form rash, classical erythema multiforme, atypical pityriasis rosea (pityriasis circinate et marginate of widale) and acquired ichthyosis. Also this work, was the first one showed the association between gleevec and induction of erythema nodosum in Iraq. Gleevec was one of the considerable causes of melasma in Iraq.

Key words: Gleevec , Adverse effects, Chronic myeloid leukemia, Gastro intestinal stromal tumor.

الخلاصة

التأثيرات الجانبية المحتملة لعقار الأيماتنيب (الكليفيك) المستخدم في علاج مرضى سرطان الدم وأورام الجهاز الهضمي في مدينة الحلة . تم دراسة ٦٢ حالة من مرضى سرطان الدم وأورام الجهاز الهضمي المتعاطين لعقار الكليفيك والمحالين من مركز الأورام في مستشفى مرجان التعليمي إلى قسم الأمراض الجلدية والتناسلية في نفس المستشفى حيث كانوا يعانون من أمراض جلدية متنوعة ناتجة كتأثيرات جانبية لهذا العقار .

تراوحت أعمار المرضى ما بين ٢١ - ٧٢ سنة وكان عدد الذكور ٣٨ (٦١,٣%) وعدد الإناث ٢٤ (٣٨,٧%). كان عدد المصابين بسرطان الدم ٤٨ (٧٧,٤%) وأورام الجهاز الهضمي ١٤ (٢٢,٦%). تراوحت فترة العلاج بعقار الكليفيك ما بين ٢ شهر - ٤ سنوات وجرعة العقار تراوحت ما بين ٤٠٠ - ٨٠٠ ملغم في اليوم. أثبتت الدراسة عن حصول بعض الأعراض الجانبية المؤثرة على الجلد نتيجة أخذ عقار الكليفيك ولأول مرة حيث لم تثبت مسبقاً في دراسات سابقة وهي كالآتي: التهاب البشرة الدهني ، الطفح الشبيه بحب الشباب ، الاحمرارية المتعددة الأشكال التقليدية ، النخالية الوريدية ، داء السمكة المكتسب، وكذلك أثبتت الدراسة عن ارتباط عقار الكليفيك بالإصابة بالاحمرارية العُقدية ولأول مرة في العراق ، ويعتبر العقار سبب مهم في الإصابة بمرض الكلف في العراق.

كذلك أثبتت الدراسة ارتباط العقار بأمراض جلدية أخرى كالتهاب بصيالات الشعر، الحكة ، الصدفية ، جفاف الجلد ، وكذلك تقرن باطن الكف أو القدم.

Introduction

Imatinib is a 2-phenylaminopyrimidine derivative chemotherapy medication that belongs to a group of medications, known as tyrosine kinase inhibitors [1]. These are a new kind of treatment known as " targeted therapy " that is different from traditional therapy [2]. Most chemotherapy medications work by killing rapidly dividing cells in the body. Tyrosin kinase inhibitors prevent tumors from growing by reducing the action of proteins that control cell division, growth and survival. These proteins are usually present in larger quantities or more active in cancer cells. By reducing the activity of these proteins, the growth and survival of cancer cells are reduced [1,2].

Imatinib is marketed by Novartis as Gleevec (USA) or Glivec (Europe / Australia / Latin America) as it's mesylate salt [2]. Gleevec has been shown to lower the number of white blood cells circulating throughout the body [3]. In addition, it blocks the growth of white blood cells that carry an abnormal protein linked to chronic myeloid leukemia(CML)[3]. Chronic myeloid leukemia is a myeloproliferative disorder involving the clonal expression of transformed hematopoietic progenitor cells [4]. It is characterized by a reciprocal translocation between the long arms of chromosomes 9 and 22 which generate the Philadelphia chromosome (ph) [4]. This leads to formation of the Bcr – Abl oncogene which encodes the Bcr – Abl protein, leading to constitutive activation of the Abl tyrosinase kinase [5]. Imatinib mesylate, the first selective tyrosinase kinase inhibitor targeting Bcr – Abl protein has shown clinical efficacy in the treatment of CML by inducing complete remission and decreased mortality of CML patients [6]. The Food and Drug Administration (FDA) has approved

imatinib as first line treatment for Philadelphia chromosome positive CML both in adults and children, including after stem cell transplant cases, in blast crisis and newly diagnosed [2].

Imatinib is also used to treat gastrointestinal stromal tumor (GIST) which is a type of tumor that grows in the walls of digestive passages and may spread to other parts of the body[7]. Gain of function mutations of the KIT – receptor were found to be an early and pre – eminent oncogenic event in the vast majority of GISTs [8]. This has led to therapy with imatinib mesylate, a highly selective inhibitor of the protein tyrosin kinase family comprising ABL, Chimeric BCR – ABL, platelet derived growth factor (PDGF) receptors α and β and the product of C – KIT proto – oncogene (KIT) [9]. The FDA first granted approval for advanced GIST patients in 2002. On February 2012, Imatinib was approved for use after the surgical removal of KIT – positive tumors to help prevent recurrence [10].The drug is also approved in unresectable KIT – positive GISTs [2].

Gleevec is also used to treat dermatofibrosarcoma protuberance (a tumor that forms under the top layer of skin), aggressive systemic mastocytosis (a rare disorder caused by too many mast cells in various tissues of the body), myelodysplastic/ myeloproliferative disease and hypereosinophilic syndrome / chronic eosinophilic leukemia [11]. Gleevec is being studied for the treatment of other tumors of blood based cancers including melanoma, brain tumors, lung cancer, ovarian cancer, stomach cancer and certain types of leukemia (Acute lymphoblastic leukemia)[11].

The prescribed dose of imatinib should be administered orally with a meal and a large glass of water. Doses of 400 mg or 600 mg should be

administered once daily, where as a dose of 800 mg should be administered as 400mg twice a day[11].

The most common side effects of imatinib include weight gain, reduced number of blood cells (anemia, neutropenia, thrombocytopenia, headache, odema especially of the lower legs and area around the eyes, easy bruising and bleeding, fast and pounding heart beat, extreme tiredness, nausea, vomiting, abdominal pain, yellowish eyes and skin and musculoskeletal pain [12]. Sever congestive cardiac failure is an uncommon but recognized side effect of imatinib and mice treated with large doses, show toxic damage to their myocardium [13]. If imatinib is used in prepubescent children, it can delay normal growth, although a proportion will experience catch – up growth during, puberty[14]. Gleevec should not be taken or closely monitored when there are certain medical problems including liver disease, congestive heart failure, receiving chemotherapy, kidney disease and a history of bleeding or a stomach ulcer. Pregnant women should not take gleevec and neither breast feeding women[15].

Dermatological side effects of imatinib include: pruritic maculopapular exanthem , follicular mucinosis, erythroderma , graft versus host – like disease, mycosis- fungoides - like reaction, small vessel vasculitis, generalized exanthematous pustulosis, Sweet syndrome, erythema multiforme, skin oedema, pigmentary changes and a lichenoid eruption [16, 17,18].

Aim of the Study

Imatinib mesylate (gleevec) is commonly used chemotherapy for treatment of CMLs and GISTs in oncology unite in Merjan Teaching Hospital. Several cases were referred

to dermatology department for various side effects or associated dermatological diseases during treatment period, so the aim of this work was to shed light on these adverse effects of gleevec therapy in Iraqi patients at Hilla city.

Patients and Methods

Sixty – two patients with CMLs and GISTs who taking gleevec as a chemotherapeutic treatment for them were studied. These patients referred from oncology unite in Merjan Teaching Hospital to the department of dermatology during the period form April 2010 to December 2012 for various cutaneous lesions and adverse cutaneous reactions that patients complained when gleevec was prescribed for them.

A full history from each patient was recorded including age, sex , type of malignancy whether CML or GIST, duration of CML or GIST, duration of gleevec treatment, dose of the drug and duration of adverse cutaneous reactions or skin problems that patients suffered from it. Family history was also asked about regarding CML or GIST or the skin complaint of patients.

A thorough physical examination was conducted to diagnose the type of cutaneous reaction and the affected site of the body whether face, trunk or extremities. Skin biopsies were taken from some patients to confirm the diagnosis and sent for histopatholical examination by hemotoxyline and eosine staining.

Results

A total of 62 patients were enrolled in the study. Their ages ranged from 20 years – 80 years (mean \pm SD, 45.4 , \pm 13.3 years). There were 38 males (61.3%) and 24 females (38.7%). There were 48 patients with CMLs (77.4%) and 14 patients with GISTs (22.6%). All these patients

were treated with gleevec capsules ,the dose ranged from 400 mg – 800 mg / day (4 – 8 capsules / day) .

The period that these patients had CMLs or GISTs since the time of diagnosis ranged from 3 months in a female patient with CML to 6 years in another female patient with CML (mean \pm SD 2.7 \pm 2.7 years). The duration of gleevec treatment ranged from 2 months to 4 years (mean \pm SD, 2.5 \pm 2.5 years).

All the patients had negative family history regarding CMLs or GISTs, or the cutaneous complaint except one male patient with CML when one of his brothers had also CML .

These patients developed one of the following cutaneous diseases mainly as an adverse cutaneous reaction to gleevec chemotherapy for their malignant disease or as an association with it (**table I**).

Table I Adverse cutaneous reactions for gleevec therapy .

| <u>Cutaneous Adverse effect</u> | <u>No. of cases (%)</u> |
|---------------------------------|--------------------------|
| 1- Melasma | 12 (19.3) |
| 2- Eczema (Dermatitis) | 9 (14.5) |
| 3- Acne – form rash | 8 (12.9) |
| 4- Folliculitis | 6 (9.7) |
| 5- Erythema nodosum | 4 (6.4) |
| 6- Erythema multiforme | 3 (4.8) |
| 7- Pruritus | 3 (4.8) |
| 8- Pityriasis rosea | 2 (3.2) |
| 9- Psoriasis | 2 (3.2) |
| 10- Chronic urticaria | 2 (3.2) |
| 11- Xerosis of skin | 2 (3.2) |
| 12- Vitiligo | 1 (1.6) |
| 13- Beau's lines of nails | 1 (1.6) |
| 14- Cheilitis | 1 (1.6) |
| 15- Common warts | 1 (1.6) |
| 16- Herpes zoster | 1 (1.6) |
| 17- Tinea incognito | 1 (1.6) |
| 18- Lichenification | 1 (1.6) |
| 19- Prurigo simplex | 1 (1.6) |
| 20- Palmar keratoderma | 1 (1.6) |

Melasma was seen in 12 patients (19.3%). There were 8 females and 4 males, 10 patients with CMLs and 2 patients with GISTs. Melasma was presented as a brown hyperpigmented patches affecting cheeks, nose, fore head and upper lip, some with butterfly distribution. The duration of melasma ranged from 2 months – 3 years (mean \pm SD, 1.4 \pm 1.1 year). It followed gleevec intake period from 5 months – 4 years (mean \pm SD , 3 \pm 2.4 years).

Eczema was seen in 9 patients (14.5%). Four patients presented with chronic eczema as plaques with fissuring and exfoliation on the dorsum of hands and Feet; 3 patients were with discoid eczema with well demarcated plaques on the extensor surfaces of the hands, forearms and right lower leg, associated with itching. Seborrheic dermatitis was found in 2 patients.

Acne – from rash was seen in 8 patients (12.9%). Clinically, it was either monomorphic in the form of either multiple papules or pustules or

dimorphic in the form of many papules and pustuls affecting the face, chest and upper back at the same time. No comedones were seen within the rash. The duration of acne - form rash ranged from 1 month – 1 year (mean \pm SD , 3 \pm 3months). It followed a treatment period with gleevec from 4 months – 2 years (mean \pm SD, 1.1 \pm 0.8 year).

Folliculitis in a form of multiple boils involving the face, back of the neck, lower abdomen and extremities was seen in 6 patients (9.7%). The duration ranged from 1 – 3 months. It followed a gleevec treatment period ranged from 6 months – 2 years. Two patients had recurrent attack of folliculitis before 6 months.

Erythema nodosum developed in 4 patients (6 .4 %), 3 females and 1 male, 2 patients with CMLs and 2 patients with GISTs. It presented as painful and tender erythematous nodules on both legs, some on the thighs and forearms. The duration ranged from 3 weeks – 2 months (mean \pm SD, 4.7 \pm 2.2 weeks). It followed a treatment episode for gleevec ranged from 3 – 6 months (mean \pm SD, 4.5 \pm 1.7 months). A biopsy was done for these patients and the result revealed septal panniculitis with a lymphohistiocytic infiltrate extends from an interlobular septum into a fat lobule in a lace like fashion. One patient with CML had a similar attack before 3 months, so developed recurrent attack of erythema nodosum.

Erythema multiforme with multiple papules and target like lesions on the dorsum of both hands and face was seen in 3 patients (4.8%). The duration ranged from 2 – 4 weeks (mean \pm SD , 3.3 \pm 1.2 weeks). It followed a gleevec treatment period of about 6 months – 1 year (mean \pm SD, 10 \pm 3.5 months).

Pruritus was seen in 3 patients (4.8%). Two of them localized in the forearms, dorsum of the hands and the back, one patient with generalized pruritus all over the body.

Pityriasis rosea developed in 2 patients (3.2%). One female patient with GIST had a classical presentation of pityriasis rosea on the chest, back and upper arms with herald patch of 2 months duration following a treatment period for gleevec of about 3 months. Another female patient with CML, had a pattern of pityriasis rosea called: pityriasis circinate et marginate of widal in which multiple annular patches with collarrete scales on both thighs of 6 months duration following a treatment period for gleevec of about 9 months.

Psoriasis was found in 2 male patients with GISTs (3.2%). One patient presented with localized keratoderma on the right palm with fissuring and other lesions of psoriasis on the back and extremities of 2 months duration following gleevec intake period of about 6 months. The other patient had psoriasis of scalp of 9 months duration following a treatment period of 1 year.

Chronic urticaria was seen in 2 patients (3.2%). They had daily attacks of wheals all over the body for 3 – 6 months following 1 – 2 years treatment period with gleevec.

Xerosis or dryness of the skin was seen in 2 patients(3.2%). One of them had fish – like scales on the forearms and extensor surfaces of the legs with ichthyosis – vulgaris – like picture which is a type of acquired ichthyosis.

Vitiligo with depigmented patches on the cheeks and forearms appeared after 5 months treatment period of gleevec, Beau's lines of some fingers and toes nails in a female patient with GIST following gleevec treatment of about one and half year, cheilitis, common warts on both hands, thoracic

herpes zoster, tinea incognito, lichenification: thick skin with hyperpigmentation of dorsum of left foot, prurigo simplex: pruritic excoriated papules on the abdomen and extremities following 6 months treatment period of gleevec and palmar keratoderma: yellowish thickening of skin on the left palm since the use of the drug. All of these cutaneous findings were found in one patient for each (1.6%).

Discussion

Gleevec is a very powerful medication, so side effects can be expected to occur [19]. In patients treated with imatinib, 7 – 21 % suffer adverse cutaneous reactions [20]. This incidence appears to be dose – dependent and 5% of such reactions are severe or life – threatening [20]. Imatinib can be reintroduced when it is associated to systemic steroids over a short term, even in patients with severe adverse cutaneous reaction [21].

Melasma was the commonest adverse cutaneous manifestation seen (19.3%). Chloasma – like skin hyperpigmentation was reported as a side effect in one patient with CML in Iranian study [22]. Other causes of melasma were excluded like iatrogenic for example oral contraceptive pills in female patients or endocrine problems. No case of hyperpigmentation of the trunk or extremities was seen in our patients, although it was reported in other studies [23,24]. There are case reports regarding imatinib – induced skin repigmentation of vitiligo lesion [25], imatinib – induced nail pigmentation [26] and imatinib – induced dental pigmentation [27]. Although hypopigmentation of skin has been recognized as a frequent and predictable effect of imatinib, only 1 patient with vitiligo had been reported in our study. It is currently not known how imatinib can induce both loss of

pigment and darkening of skin in different patients. Changes in cutaneous photosensitivity consisting in both hypo – and hyperpigmentation have been observed with imatinib and have been attributed to an interference with the molecular pathway involved in the response to ultraviolet stress [18]. The persistent hyperpigmentation may be due to increased basal melanin pigment, dermal melanin pigment incontinence and chronic inflammation. Imatinib causes diffuse over stimulation of melanogenesis in the skin[24]. How the same drug can produce both hypopigmentation and darkening in the skin is unclear, but a possible explanation may reside in its binding to different receptors in the skin, some with activator and other with inhibitory effects on melanogenesis [24]. Another possible explanation for skin hypopigmentation is c – kit expression in melanocytes [23]. It plays a role in melanogenesis and pigmentation that is a target for imatinib [28].

According to " **e Health Me**", Real world drug out comes, personalized [29]: on Jan, 21 , 2013 : 1, 302 people reported to have side effects when taking imatinib mesylate, among them, 3 patients (0.23%) have eczema(atopic dermatitis), 2 males and 1 female and the age more than 60 years. The time on imatinib when patients have eczema was 1 – 6 months. In our study, 9 patients had eczema (14.5 %), 7 females and 2 males with the age ranged from 31 years to 67 years (mean \pm SD ; 53 \pm 12.4 years), and the time on imatinib when patients had eczema was 4 months – 2 years. The differences between the high number of eczema in our patients compared to what reported in the literature because 7 of our eczema patients had chronic irritant contact dermatitis or discoid eczema may be due to other causes of

contact with irritants or chemicals and detergents especially more common in females and some may have eczema even before taking gleevec as a treatment, but in 2 patients, 31 years old male and 47 years old female, developed seborrheic dermatitis for the first time 4 – 6 months after gleevec intake and in sever form involving the face, chest and scalp, and one of them get good control of seborrheic dermatitis after stopping the treatment for a short time. So, we can conclude that imatinib could be one of triggering drugs for induction of seborrheic dermatitis which was not reported previously. No patient in the study had atopic dermatitis.

Acne – form rash was the next common side effect of imatinib seen in 8 patients (12.9%). It was seen for the first time when the patient started to take gleevec for 4 months – 2 years. The majority of the patients were young adults 23 – 40 years. There was no history of ingestion of drugs that induce acne like systemic steroids or using potent topical steroids on the face or chest for any reason. Behest's disease was excluded in our patients as acne – form rash is one of it's cutaneous manifestations. No case of imatinib – induce acne was reported in the literature except one case of hyperpigmented acne rosacea during gleevec treatment for GIST [30]. So, this high number of acne patients for the first time after gleevec intake may lead to consider that imatinib is one of the drugs that induces acne – form eruption.

Boil folliculitis was seen in 6 patients (9.7%). Cases of diabetes and Behcet's disease were excluded in our patients. This percentage of folliculitis was apparently more common than what recorded about gleevec – induced folliculitis according to " **e Health Me**", Real world outcome [29]7:On

Jan 13, 2013 : 19: 806 people reported to have side effects when taking gleevec, among then 9 patients (0.05 %) have folliculitis and the time on gleevec was 6 – 12 months. The discrepancy between the results was related to relatively less number of our studied patients according to " e Health Me " drug out come and to the time of study period " 2 years " compared to " 11 years " of " e Health Me " in which the side effects were general systemic and dermatological. In our patients , only cutaneous side effects were studied. This discrepancy between the results was also noticed in other side effects when compared with" e Health Me " world drug outcome, for the same reasons.

Erythema nodosum (EN) was found in 4 patients (6.4%). Other cause of EN were excluded like infection for example: streptococcal infection, autoimmune disorders like inflammatory bowel disease or Behcet's disease, pregnancy in female patients and medications for example: oral contraceptive pills and sulfonamides. According to " **e Health Me**" drug outcome : on Jan 21, 2013 : from 19, 806 people reported to have side effects when taking gleevec, 19 patients (0.10%) have EN. The time on gleevec when these patients have EN was less than 1 month in 20% and from 6 – 12 months in 80%. Our patients developed EN when the treatment period of gleevec was 3 – 6 months. To the best of our knowledge, this work was the first registration that imatinib mesylate is one of the drugs which cause erythema nodosum in Iraq and middle east and it should be considered beside other drugs like sulfonamides and oral contraceptives because there are many patients with CML in Iraq in which gleevec is the drug of first choice in their treatment.

Erythema multiforme (E.M) was other side effect of gleevec therapy

occurred in 3 patients (4.8%) following a treatment period of about 6 months – 1 year. We should ask about herpes simplex infection which is the commonest cause or trigger for E.M in Iraq. According to " **e Health Me** " drug outcome: Steven - Johnson syndrome which is a severe form of E.M , with erosions, blisters and disseminated cutaneous eruption, was reported in 2 patients from 1,305 patients had side effects when taking imatinib, when the time on the drug was less than 1 month. In the literature there was no case report about E.M with it's classical presentation of macular or papular lesions with iris or target lesions (E.M minor) as what presented in our study, but what reported was only the severe form (Steven – Johnson's syndrome).

According to " **e Health Me** " drug outcome ; pruritus reported in 16 patients (1.23%) from 1,305 people had side effects when taking gleevec and the time on imatinib when patients have pruritus was less than 1 month in 50% and from 1 – 6 months in 50%. Females and males were equally affected. In our study, 3 patients developed pruritus (4.8%), 2 females and 1 male, when they were on gleevec from 6 months – 1 year. Other causes of pruritus were excluded whether dermatological or systemic.

Pityriasis rosea (PR) was seen in 2 patients (3.2%). In the literature, several cases of pityriasis rosea – like drug eruption induced by imatinib were also reported [31,32]. According to " **e Health Me** " drug outcome: On Jan 8, 2013 : 19, 806 people reported to have side effects when taking gleevec, among them 5 patients (0.03%) have PR. All reported cases of PR were classical or with typical presentation, but in our study, a case of atypical PR was reported (pityriasis circinate et marginate of widal) which lasts for a longer time than the

classical PR and located mainly on both thighs.

Psoriasis was seen in 2 patients (3.2%). According to " **e Health Me** " drug outcome: On Jan 18 , 2013 : 19, 806 people reported to have side effects when they were on gleevec , 31 patients (0.16%) have psoriasis. Psoriasis vulgaris was also reported to be exacerbated by imatinib therapy [33]. The exacerbation of psoriasis was likely due to the increase in Th 1 cells associated with imatinib therapy [33]. According to " **e Health Me** " drug outcome; on Jan 25, 2013 : 1,302 people reported to have side effects when taking imatinib, among them one male patient aged 55 years (0.08 %) had urticaria in 2006. In our study, only 2 male patients (3.2%) had chronic urticaria aged 50 and 60 years with 3 -6 months duration following 1 – 2 years treatment period of gleevec.

Xerosis or dryness of skin was found in 2 patients(3.2%). In " **e Health Me** " drug outcome; on Jan 26, 2013 : 21, 449 people who reported to have side effects when taking imatinib, only 2 patients had xerosis of skin (0.12%). In our study, one of the patients had ichthyosis – vulgaris like picture, so gleevec could be one of the drugs that may cause acquired ichthyosis which was not reported in the literature.

Beau's lines of some fingers and toes nails with palmar keratoderma were seen in one patient for each since the use of gleevec for treatment(1.6%). No case report declared such association with imatinib therapy. The rest of cutaneous manifestations like cheilitis, herpes zoster, prurigo simplex, lichenification, common warts and tinea incognito were seen in 1 patient for each (1.6%). They may be associated accidentally with the use of gleevec therapy for CML patients.

Conclusions

- 1- Gleevec was one of the considerable causes of melasma in Iraq.
- 2- From this study, gleevec was reported for the first time to cause or trigger the following adverse effects: seborrheic dermatitis, acne – form rash, classical erythema multiforme, atypical pityriasis rosea (pityriasis circinate et marginate of widale), acquired ichthyosis and Beau's lines of nails.
- 3- This work, was the first report showed the association between gleevec and induction of erythema nodosum in Iraq and middle east.
- 4- Gleevec should be consider as a cause or trigger for folliculitis, pruritus, psoriasis, xerosis of skin and palmo plantar keratoderma.

References

- 1- Takimoto CH, Calvo E. principles of oncologic pharmacotherapy. In : Pazdur R, Wagman LD, Camphor Usen KA, Hoskins WJ, eds. Cancer Management: A multidisciplinary Approach. 11th ed. 2008 : 2437 – 48.
- 2- abc " FDA high lights and prescribing informations for Gleevec [Imatinib mesylate).
- 3- Deininger MW, Druker BJ. Specific targeted therapy of chronic myelogenous leukemia with Imatinib. Pharmacol. Rev. 2003; 55(3):401-23.
- 4- Faderl S, Talpaz M, Estrov Z. The biology of chronic myeloid leukemia. N Engl J Med. 199 9; 341: 164 – 72.
- 5- Nowell PC. Discovery of the Philadelphia chromosome: a personal perspective. J Clin Investing. 2007; 117: 2033 – 5.
- 6- Madhusudan S, Ganesan TS. Tyrosine kinase inhibitors in cancer therapy. Clin Biochem. 2004 ; 37: 618 – 35.
- 7- Druker BJ, Kinase Tamura S, Buchdunger E. effects of a selective

- inhibitor of the Abl tyrosine kinase on the growth of Bcr – Abl positive cells. Nat Med. 1996; 2(5): 561 – 6.
- 8- Buchdunger E, Cioffi CL , Law N. Abl protein – tyrosine kinase inhibitor STI571 inhibits invitro signal transduction mediated by C – Kit and platelet derived growth factor receptor J pharmacol Exp Ther. 2000 ; 295[1] : 139 – 45.
- 9- Heinrich MC, Griffith DJ, Druker BJ. Inhibition of C – Kit receptor tyrosine kinase inhibitor. Blood. 2000; 96(3): 925 – 32.
- 10- "Prolonged use of imatinib in GIST patients leads to new FDA approval".
- 11- Guilhot F. Indications for imatinib mesylate therapy and clinical mesylate. Oncologist. 2004; 9: 271 – 81.
- 12- Schwab C. Advances in the management of chronic myeloid leukemia with Abl Kinase inhibitors. Oncology Briefings. 2006; 41 – 3.
- 13- Kerkela R, Grazette L , Yacobi R, Cardiotoxicity of the cancer therapeutic agent imatinib mesylate. Nat. Med. 2006 ; 12(8) : 908 – 16.
- 14- Shima H, Tokuyama M, Tanizawa A. Distinct impact of Imatinib on growth at prepubertal and pubertal ages of children with chronic myeloid leukemia. J. pediatr. 2011; (159) : 676 – 81.
- 15- Tsao AS, Kantarjian H, Cortes J, O'Brien S, Talpaz M. Imatinib mesylat causes hypopigmentation in the skin. Cancer. 2003; 98: 2483 – 7 .
- 16- Ayirookuzhi SJ, MaL, Ramshesh P, Mills G. Imatinib – induced sweet syndrome in a patient with chronic myeloid leukemia. Arch Dermatol. 2005; 14:368 – 70.
- 17- Pascual JC, Matarredona J, Miralles J, Conesa V, Borrás – Blasco J. Oral and cutaneous lichen reaction secondary to imatinib: report of two cases. Int J Dermatol. 2006 ; 45 : 1471 – 3.

- 18- Robert C, Soria JC, Spatz A, Lecesne A, Malka D, Pautier P. Cutaneous side effects of kinase inhibitors and blocking antibodies. *Lancet Oncol.* 2005; 29: 208 – 9.
- 19- Uptodate 17.3 , 2009 . Drug information : Imatinib.
- 20- Brouard MV, Saurat JH. Cutaneous reactions to ST1S 71. *N Eng J Med.* 2001; 345:618 – 9.
- 21- Blanca SG, Jose C , Pascual R, Isabel BR, Concepcion R , Gloria VA. Severe skin reaction to imatinib in a case of Philadelphia – positive acute lymphoblastic leukemia blood. 2003; 101 : 2446.
- 22- Valizadeh N. Imatinib – induced facial skin hyperpigmentation in a case of chronic myeloid leukemia. *Shiraz E. Medical Journal.* 2011 ; 12(3):3.
- 23- Arora B, Kumar L, Sharma A, Wadhwa J, Kochupillai V. Pigmentary changes in chronic myeloid leukemia patients treated with imatinib mesylate. *Ann Oncol.* 2004; 15: 358 – 9.
- 24- Alexandrescu DT, Dasanu CA, Farzanmehr H, Kauffman CL. Persistent cutaneous hyperpigmentation after tyrosine kinase inhibition with imatinib for GIST. *Dermatology Online Journal.* 2008; 14(7):7.
- 25- Hui H, Yang – yang Y, YU – houg W. Imatinib mesylate induced repigmentation of vitiligo lesion in a patient with recurrent GIST. *JAAD.* 2008; 59(5) : 580 – 3.
- 26- Prabhast K, Biswas Gh, Prasad N, Koran N, Sastry PS, Parikh PM. Imatinib – induced nail pigmentation in CML. *Indian J Dermatol Venereol leprol.* 2006; 72 (1): 63 – 4 .
- 27- Singh N, Bakhshi S. Imatinib – induced dental hyperpigmentation in childhood CML. *J pediatr Hematol Oncol.* 2007; 29(3) : 208 – 9.
- 28- Tsao AS, Kantarjian H, Cortes J, O'Brien S, Talpaz M. Imatinib mesylate causes hypopigmentation in the skin. *Cancer.* 2003; 98: 2483 – 7.
- 29- " e Health Me "; Real World drug outcomes, personalized. *Dermatology Online Journal.*
- 30- Umut D, Ugur C, Ozlem E, Banu O, I sailay BY, Mustafa B, Suleyman B. Acne rosacea associated imatinib mesylate in GIST patient. *J Oncol Pharm pract.* 2011; 17(3) : 285 – 7 .
- 31- Cho AY, Kim DH, Im M, Lee Y, Seo YJ, Lee JH. Pityriasis rosea – like drug eruption induced by imatinib mesylate. *Ann Dermatol* 2011;23:S360 – 3.
- 32- Brazzelli V, Prestinari F , Roveda E, Barbagallo T, Bellani E, Vassallo C. PR – like eruption during treatment with imatinib mesylate: description of 3 cases. *J Am Acad Dermatol.* 2005 ; 53 (S suppl 1) : S 240 – 3.
- 33- Shimizu K, Kuroda H, Kida M, Watanabe H, Shirao S, Akiyama T. Psoriasis vulgaris exacerbated by Imatinib therapy in CML. *Rinsho Ketsueki.* 2005; 46(10): 1152 – 5.