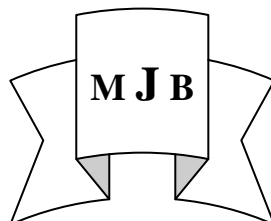


Clinical Evaluation of Bovine Derived Xenograft with a Bioabsorbable Collagen Membrane in the Treatment of Molar Class II Furcation Defects

Zainab Muhi H. Al-Fatlawi Raad Ali Jassim Zeyad Nazar M. Al-Talib
College of Dentistry, University of Babylon, Hilla, Iraq.



Received 2 December 2012

Accepted 30 April 2013

Abstract

The aim of this study is to clinical evaluation bovine derived xenograft with guided tissue regeneration membrane used was osseoguardresorbable collagen membrane in the treatment of human periodontal Class II molar furcation defects. Ten patients(6 males, 4 females) suffering from chronic periodontitis, with Grade II molar furcation defect, were treated using bovine derived xenograft with GTR membrane, completed the study with the following clinical parameters were assessed immediately before the surgical procedure(Baseline) and at 6 months after treatment. These parameters were, Plaque index Score(PII),gingival index (GI) vertical probing depth (VPD) ,clinical attachment level (CAL),gingival recession(GR) and closed horizontal probing depth (CHPD).This therapy resulted in significant VPD reductions and no significant improvement was seen (CAL),(GR) and significant reduction of(CHPD). For the mean values for the of (VPD)(5.3 ± 1.35),(CAL)(3.5 ± 1.4), (GR)(0.3 ± 0.51) and(CHPD)(4.8 ± 0.99) at baseline ,while these parameters at 6 months after surgical treatment were(2.82 ± 1.56),(2.3 ± 1.4), (0.28 ± 0.5)and(2.2 ± 1.54) respectively.

The findings of this study suggest improvement in clinical results when the use of resorbable collagen membrane with bovine derived xenograft in treatment of class II molar furcation involvement.

Key Words: periodontal; regeneration;GTR,furcations; graft, bone,bovine- derived xenograft, bioresorbable membrane.

الخلاصة

الهدف من هذه الدراسة هو لتقييم القياسات السريرية الناتجة عن استخدام الطعم العظمي المشتق من الابقار مع غشاء كولاجين ذاتب في علاج مجموعة من الناس لديهم اضرار في منطقة تشعب او تفرع جذور مصابة سريريا (درجة ثانية) و هذه القياسات تمثلت بعمق الجيب اللثوي العمودي وفقدان التعلق السريري و انحسار اللثة و عمق الجيب العرضي و مقارنة هذه النتائج مع نفس القياسات ولكن بعد مرور ستة اشهر من العلاج باستخدام التجريف الجراحي.العينة تكونت من ١٠ اشخاص مصابين بالتهاب لثوي مزمن يرافقه اضرار فيها منطقة تشعب او تفرع الجذور مصابة سريريا(درجة ثانية). التحليل الاحصائي للقراءة الاولى و القراءة الثانية بعد ستة اشهر اوضحت النتائج ان نقصان عمق الجيب اللثوي العمودي وفقدان التعلق السريري و انحسار اللثة و عمق الجيب العرضي مما يدل على تحسن سريري واضح في علاج هذه الاضرار التي فيها منطقة تشعب او تفرع جذور المصابة سريريا باستخدام التجريف الجراحي و الطعم العظمي المشتق من الابقار .

Introduction

The primary etiology of periodontal diseases is the presence and maturation of a bacterial biofilm eliciting a host response [1]. Treatment to arrest the development of such conditions

involves subgingival mechanical debridement and establishment of a local environment for bacteria compatible with gingival health.

Studies have shown that chronic periodontitis may successfully be treated non-surgically and

surgically.[2] Regardless of the treatment method used, most longitudinal studies have shown that molars are at higher risk for tooth loss than nonmolar teeth.[3-5]

Furcation involvements (loss of bone and connective tissue attachment in the interradicular area of multi-rooted teeth) represent one of the most demanding therapeutic challenges in periodontics. Conventional therapy, directed at regeneration of the attachment apparatus in furcation defects, is unpredictable. Rapid apical growth of sulcular epithelium interferes with attempts at gaining a connective tissue attachment to cementum. Techniques using occlusive membranes placed between the primary flap and the osseous defect are encouraging. These guided tissue regeneration (GTR) techniques isolate the root surface and effectively exclude the epithelium while permitting the periodontal ligament cells to proliferate into the defect.[6-8]

The introduction of bone grafting methods[9-10] and the concept of tissue regeneration[11-13] offered new hope for improved and more predictable treatment of furcation involvement. The combination therapy of a membrane and bone grafting for lower first and second molars has resulted in successful closure of furcations.[14,15] Grade II molar furcation defects mean bone destruction on one or more aspects of the furcation, but a portion of the alveolar bone and periodontal ligament remains intact. or :-horizontal loss of the periodontal tissue support not exceeding 1/3 of the width of the tooth[16]. Of the various furcation involvements, Class II furcations have been shown to be the best candidates for regenerative treatment.[17,18] In assessing the success of these treatment methods, complete closure of the defect is desirable.

A bovine derived xenogenic bone graft (BDX) has been extensively used with positive clinical results over the last decade in the treatment of periodontal infrabony and furcation defects, alone or in combination with membranes or enamel matrix derivatives.[19-25] In a comparative evaluation of BDX with and without a bioresorbable collagen barrier in the treatment of mandibular Class II furcation defects, Reddy et al. (2006) observed that both treatment procedures resulted in statistically significant reduction in VPD and HPD, gain in CAL. They concluded that the findings suggest superior clinical results with Bio-Oss/BG treatment when compared to Bio-Oss treatment in mandibular class II furcation defects. On the other hand, Taheri et al. (2009) had concluded that there is no superiority of the combined use of Bio-Gide and Bio-Oss to the use of Bio-Oss alone in the treatment of mandibular Class II furcation defects, although both therapies resulted in significant gains in attachment level and bone fill.[27]

Therapeutic results can be measured by vertical probing depth (VPD) and clinical attachment level (CAL) improvements, bone regeneration, and evidence of histologic periodontal regeneration. Although histologic evaluation is most accurate, surgical closure of the furcation defect and improvements in VPD and CAL serve as suitable and practical outcome measures.[28,29].

The aim of this study is clinical evaluation of bovine derived xenograft with a bioresorbable membrane in the treatment of human periodontal Class II molar furcation defects.

Material and Methods

Population screening

Subject recruitment started in October 2009 and was completed by the end of

June 2010. The first surgical procedure was carried out in December 2009, and all the 6-month follow-up visits were completed in May 2010. Data entry of all information and statistical analysis were performed by the end of December 2010.

Potential patients (10 patients) were selected from those referred to the periodontal department clinic of the college of dentistry (Babylon university). All patients received a complete periodontal examination, including a full-mouth periodontal probing (Fig 1), radiographic examination (Fig 2). The study inclusion criteria were (i) diagnosis of chronic periodontitis (according to the criteria of the 1999 international classification;) [30]; (ii) presence of class-II furcations, presenting $PD \geq 5\text{mm}$ and bleeding on probing, after nonsurgical therapy; (iii) good general health. Patients who (i) were pregnant or lactating; (ii) required antibiotic pre-medication for the performance of periodontal examination and treatment; (iii) suffered from any other systemic diseases (cardiovascular, pulmonary, liver, cerebral, diseases or diabetes); (iv) had received antibiotic treatment in the previous 3 months; (v) were taking long-term anti-inflammatory drugs; and (vi) were smokers, were excluded from the study).

Non-surgical treatment

All the subjects received a thorough scaling and root planning. The subjects were recalled after one to two months for surgical procedure. All

these treatments were performed by the same operator, with an ultrasonic device. At the same time the subjects underwent motivation session, during which oral hygiene instructions were given, to ensure that the subjects could maintain a proper level of oral hygiene before the surgical procedure.

Clinical parameters

The following clinical parameters were assessed immediately before the surgical

Procedure (Baseline) and at 6 months after treatment. These parameters were, Plaque index Score (PII) [31], gingival index Score (GI) [32] periodontal pocket depth (VPD), Clinical attachment level (CAL), Gingival Recession (GR) and Closed horizontal probing depth (CHPD) were calculated when probing with manual probe. (Fig. 1) All measurements were recorded by the same examiner.

1- Vertical pocket depth (VPD): in millimeters in the mid-furcation area.

2- Clinical attachment level (CAL): the distance from CEJ to the base of the pocket.

3- Gingival Recession (GR): gingival margin position to the CEJ in 3 points of each surface of the tooth.

4- Closed horizontal probing depth (CHPD): the distance from deepest area of Probe. Penetration vertically to buccal or lingual surfaces to connection line of the high light contour of mesial and distal roots.

Each patient was treated by GTR and a bovine-derived xenograft, The GTR membrane used was Osseo Guard Resorbable Collagen Membrane.

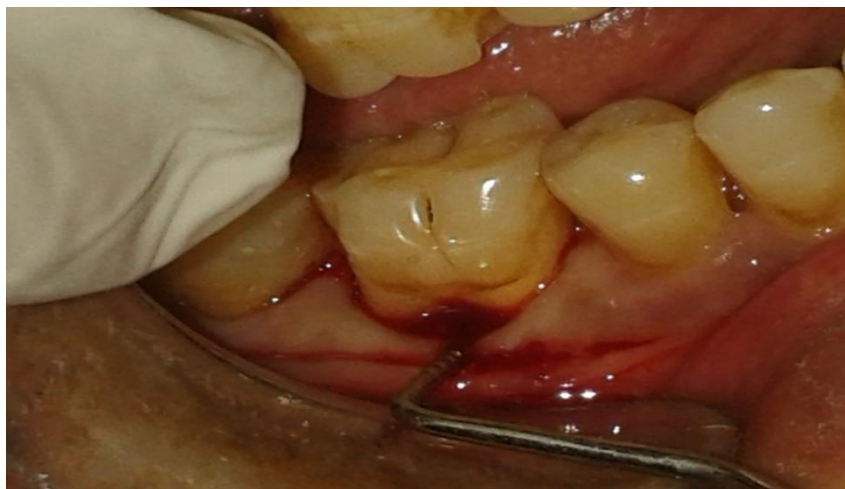


Figure 1 Preoperative view of mandibular right first molar.



Figure 2 Preoperative radiograph of mandibular right first molar.

Surgical procedures

Following local anesthesia, sulcular incisions were made and mucoperiosteal flaps were raised at furcation area. Carefully, the tissue was reflected,

preserving the maximum of interproximal soft tissue. Granulation tissue as well as the visible calculus were removed with hand currettes and with an ultrasonic device.(Fig.3)

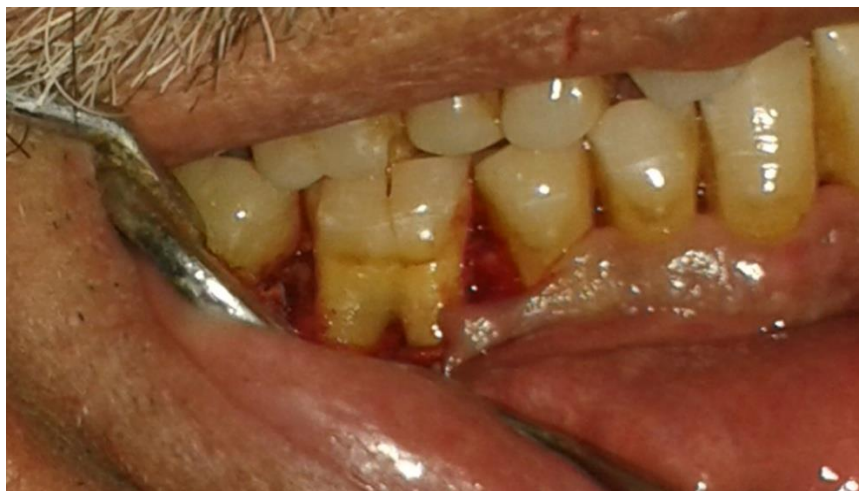

Figure 3 A sulcular incision and mucoperiosteal flaps were raised at furcation area, the tissue was reflected, preserving the maximum of interproximal soft tissue. Granulation tissue as well as the visible calculus were removed with hand curettes and with an ultrasonic device.

The bone graft was applied from the farthest end of the involved furcation until the buccal surface of the tooth was

covered with it(Fig.4).After the defect was filled with the bone graft.

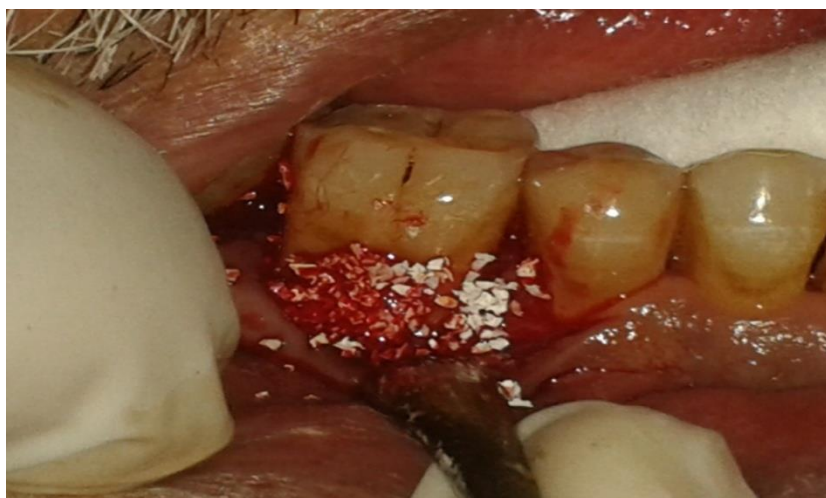

Figure 4 Placement of the bone graft was applied from the farthest end of the involved furcation until the buccal surface of the tooth was covered with it.

The membrane was removed from the sterile package and was compared with surgical area. The membrane was soaked in normal saline solution to improve its adhesion properties as recommended by the

manufacturer. It was subsequently adapted over the defect extending 2-3 mm apical to the crest of the existing bone, so as to provide a broad base during the placement. (Fig.5)

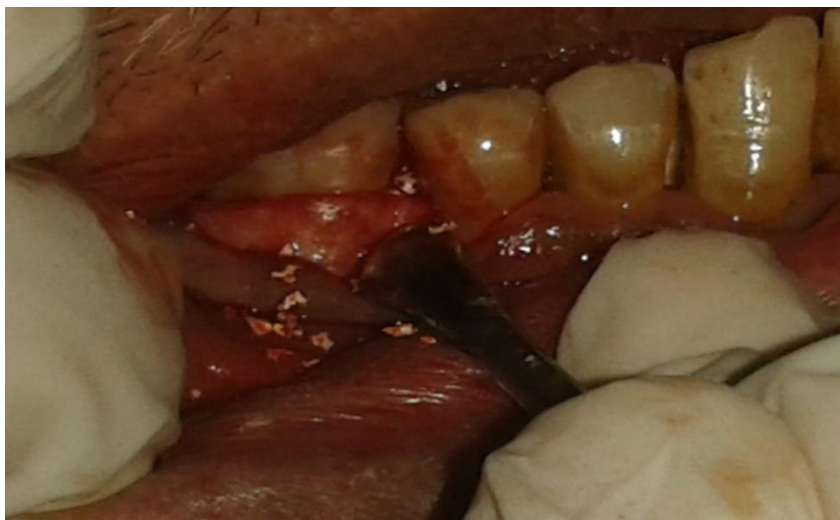


Figure 5 The membrane was subsequently adapted over the defect extending 2-3 mm apical to the crest of the existing bone,so as to provide a broad base during the placement.

The surgical flaps were then replaced at their initial position and sutured.(Fig.6) . A black silk suture(3-0) using vertical mattress or an interrupted

technique. After suturing, slight pressure on the facial and lingual flaps is applied to minimize the clot beneath the flap.

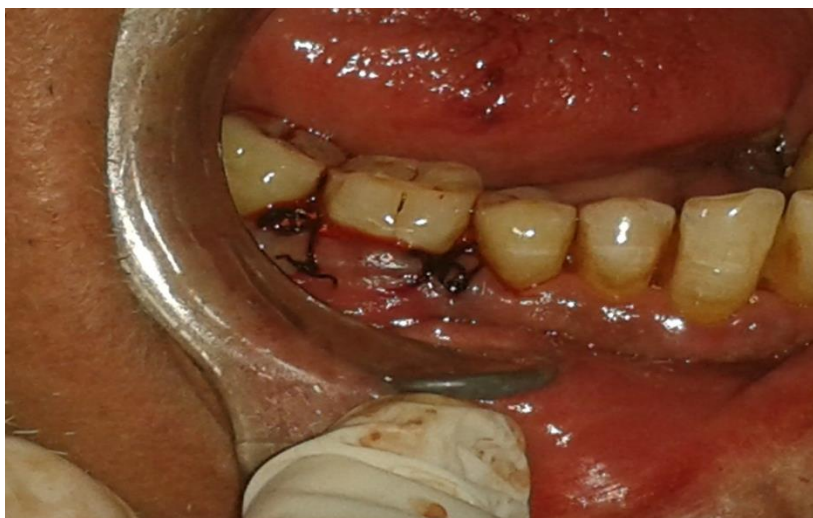

Figure 6 A black silk suture(3-0) is used to replace the flap at their initial position.

It is optional to place a surgical dressing to protect the wound. Placement of a dressing must be a completed, however, without displacement of the graft or compromise of the blood supply to the gingival flaps for a period of 7 to 10 days, at which time the dressing and sutures were removed. No further dressings were

placed unless special conditions dictated otherwise.All surgical procedures were performed by the same periodontist(Z.M)to prevent inter-operator variations.

Postoperative management / period-ontal maintenance

The administration of antibiotics beginning immediately

post-surgery is thought to aid in plaque control [33] Amoxicillin 500 mg t.i.d was prescribed for the 10-day immediate postsurgical period. NSAIDs (either 600 mg ibuprofen or 500 mg paracetamol) were begun one hour prior to surgery and continued t.i.d for 3 days postsurgically. Patients should also be kept on achlorhexidine mouthwash (0.2 %) to further aid in this process[34]. For the first 4–6 weeks, patients should refrain from brushing the surgical area to prevent disturbance of the blood clot [35]. Sutures are retained as long as they maintain closure and do not contribute to plaque accumulation and inflammation .Postoperative weekly visits include plaque removal (mechanically with hand curette), selective stain removal and reinforcement of oral hygiene. Periodontal probing should not be done

prior to 6 months, since probing force may damage the healing site, thereby diminishing the regenerative outcome.

Statistical Analyses

The changes of pretreatment and post-treatment (PII,GI ,VPD,CAL,GR and CHPD) measurements were the basis for data analysis with the use of a statistical software program. The paired-samples t-test was used to compare the mean values of presurgical and postsurgical treatment .

Results

Ten patients completed the study with clinical data collected at baseline and after 6 months post-treatment. (6 males, 4 females).

Table 1.showed patient characteristics at baseline. The mean age was 52.6±5.4 years, including a majority of males.

Table 1 Patient characteristics at baseline.

Age	52.6±5.4
Male (%)	6(60)
Female(%)	4(40)

The means of full-mouth plaque and gingival index scores at surgical site are shown in Table 2. The plaque and gingival index scores were

maintained at low throughout the study, without statistical difference from baseline to 6 months for both parameters at the surgical site.

Table 2 Changes in clinical parameters(PII. And GI.)

mean±S.D	
Plaque index	
Baseline	1.24 ± 0.66
6 months	0.82 ± 0.64
P-value	0.062(N.S)
Gingival index	
Baseline	1.24 ± 0.66
6 months	1.12 ± 0.33
P-value	0.11(N.S)

VPD,CAL,GR and CHPD means are shown in Table 3.A reduction in VPD was observed ($p < 0.05$). The vertical probing depth was significantly reduced to (2.82 ± 1.56 mm) 6 months after surgery, where it was (5.3 ± 1.35 mm) at baseline (presurgical treatment).

The amount of CAL presurgical treatment was (3.5 ± 1.4), while after 6 months was (2.3 ± 1.4 mm). It was reduced but the analysis showed that there was no significant difference in change of

means before and 6 months after surgery ($P > 0.05$).

There was decreased in GR after 6 months (0.28 ± 0.5 mm), GR was (0.3 ± 0.51) before surgical treatment. The difference between pre & post-surgery non significant ($P > 0.05$).

CHPD pre surgical treatment (Baseline) was (4.8 ± 0.99 and 2.2 ± 0.54) mm after 6 months. They showed more reduction after treatment, and there significant difference between them.

Table 3 Mean values and Standard deviations (\pm SD) For Presurgical (baseline) and Postsurgical treatment (after 6 months) of Vertical probing depth (VPD), clinical attachment level (CAL), gingival recession (GR) and closed horizontal probing depth (CHPD) and Significant Differences between them.

VPD	CAL	GR	CHPD	
Baseline	5.3 ± 1.35	3.5 ± 1.4	0.3 ± 0.51	4.8 ± 0.99
6 months	2.82 ± 1.56	2.3 ± 1.4	0.28 ± 0.5	2.2 ± 0.54
P-value	0.04 (S.)	0.12 (N.S.)	0.06 (N.S.)	0.03 (S.)

Discussion

The introduction of resorbable membrane materials brings clear advantage in the clinical management of guided tissue regeneration procedures, mainly in the avoidance of a second surgical intervention, and thus, prevention from exposure of newly formed tissue underneath the membrane. [15]

The treatment of furcation-involved teeth, however, still represents a challenge for clinicians [36]. This class of lesions presents a poor response to non-surgical treatment [37,38]. The bone graft material and the bioabsorbable collagen membrane used in the study appeared to be biocompatible and safe membrane exposure was not observed in any of cases in the study. This may be explained by the biocompatibility of collagen membrane and its hemostatic and chemotactic functions. [39]

In this study evaluation the clinical outcome (Plaque index (PII), Gingival index (GI)), Vertical probing depth (VPD), clinical attachment level (CAL), gingival recession (GR) and closed horizontal pocket depth (CHPD) and re-evaluate these clinical parameters 6 months after treatment without surgical re-entry. Other methods are needed among which, re-entry is the best, since it investigates furcation directly. In our society, it's not easy to do surgical re-entry procedure, from ethical point of view. The use of re-entry surgery for evaluation may be questioned, but such secondary revision surgery is often necessary in non-research bone graft therapy as the average response in osseous defects is defect fill. Often, this leaves a residual defect that requires further therapy (either additional grafting, debridement, or conservative osseous resection). [40].

Because a bovine-derived xenograft applications with collagen resorbable membrane have demonstrated good clinical results in grade II furcations [15,23,26,27,41].

The mean vertical probing depth values at the mid furcation area were reduced between the baseline and six months and this reduction were statistically significant. However the vertical probing depth obtained in this study was in agreement with the studies of Houser et al [23], Reddy et al [26], Taheri et al [27] and Simonpeitri et al [41]. They reported a reduction of vertical packet depth after 6 months. While these results also in agreement with the studies of Khanna et al [15], but this study demonstrated that the reductions in vertical probing depth at furcation sites were not statistically significant.

The present study also showed a significant reduction of CAL and GR compare to baseline (pre-surgical treatment) this results may be due to increase trauma to the soft tissue during surgical operation, the non-significant reduction of CAL and GR is agree with Houser et al [23], Reddy et al [26], Taheri et al [27] and Simonpeitri et al [41]. at the same time the last studies found that there is a significant reduction of CAL and GR. The improvement of CHPD indicates the resistance of the treated defect to the probe penetration. these results also agreed with the results of Houser et al [23], Taheri et al [27] and Simonpeitri et al [41]. They reported a reduction of horizontal probing depth after 6 months. While these results also in agreement with the studies of Ak. Khoshkhoo N. [42], Khanna et al [15] and [Reddy 2006] [23] found the same results. The clinical data of GTR therapy include reduction of furcation involvement from grade II to grade I. These changes reflect reduction of the horizontal inter-radicular probe

penetration. The reason for this effect can either be the formation of new connective tissue attachment or of long junctional epithelium between the root surfaces and the newly formed dense soft tissues. However, reduction in the mean horizontal probing depth suggested a considerable change from grade II to grade I in all the defects studied.

Conclusion

The use of resorbable collagen membrane with bovine derived xenograft can be a clinically useful graft material in treatment of class II molar furcation involvement.

References

- 1-Socransky, S. S. & Haffajee, A. D. (2005) Periodontal microbial ecology. *Periodontology* 2000 38, 135–187.
- 2-Huynh-Ba G, Kuonen P, Hofer D, Schmid J, Lang NP, Salvi GE. The effect of periodontal therapy on the survival rate and incidence of complications of multirooted teeth with furcation involvement after an observation period of at least 5 years: a systematic review. *J Clin Periodontol* 2009; 36: 164–176.
- 3-Goldman MJ, Ross IF, Goteiner D. Effect of periodontal therapy on patients maintained for 15 years or longer. A retrospective study. *J Periodontol* 1986; 57: 347-353.
- 4-McFall WT Jr. Tooth loss in 100 treated patients with periodontal disease. A long-term study. *J Periodontol* 1982; 53: 539-549.
- 5-Hirschfeld L, Wasserman B. A long-term survey of tooth loss in 600 treated periodontal patients. *J Periodontol* 1978; 49: 225-237.
- 6-Melcher AH, Cheong T, Cox J, Nemeth E, Shiga A. Synthesis of cementum-like tissue in vitro by cells cultured from bone: A light and electron microscope study. *J Periodont Res* 1986; 21: 592-612.

- 7-Melcher AH, McCullough CAG, Cheong T, Nemeth E, Shiga A. Cells from bone synthesize cementum-like and bone-like tissue in vitro and may migrate into periodontal ligament in vivo. *J Periodont Res* 1987; 22:246-247.
- 8-Gowda VS, Chava V, Kumara AE, An evaluation of a resorbable (semirigid) GTR membrane in human periodontal Intraosseous defects: A clinicoradiologic re-entry study. *J Indian Soc Periodontol* 2011;15:393-397.
- 9-Schallhorn RG, Hiatt WH, Boyce W. Iliac transplants in periodontal therapy. *J Periodontol* 1970;41:566-580. 1977; 48:570-576.
- 10-Mellonig JT, Bowers GM, Bright RW, Lawrence JJ. Clinical evaluation of freeze-dried bone allografts in periodontal osseous defects. *J Periodontol* 1976;47:125-131.
- 11- Melcher AH. On the repair potential of periodontal tissues. *J Periodontol* 1976;47:256-260.
- 12- Becker W, Becker BE, Berg L, Prichard J, Caffesse R, Rosenberg E. New attachment after treatment with root isolation procedures: Report for treated Class III and Class II furcations and vertical osseous defects. *Int J Periodontics Restorative Dent* 1988;8(3):8-23.
- 13- Bowers GM, Chadroff B, Carnevale R, et al. Histologic evaluation of new attachment apparatus formation in humans. Part I. *J Periodontol* 1989;60:664-674.
- 14- Bowers GM, Schallhorn RG, McClain PK, Morrison GM, Morgan R, Reynolds MA. Factors influencing the outcome of regenerative therapy in mandibular Class II furcations: Part I. *J Periodontol* 2003;74:1255-1268.
- 15-Khanna D, Malhotra S, Naidu DV. Treatment of grade II furcation involvement using resorbable guided tissue regeneration membrane: A six-month study. *J Indian Soc Periodontol* 2012;16:404-410.
- 16- Lindhe J, Thorkild K, Niklaus P. Lang. Treatment of furcation-involved teeth. Text book of clinical periodontology and implant dentistry. Third edition, Munksgard, Copenhagen 1998; PP 682-709.
- 17- Reynolds MA, Aichelmann-Reidy ME, Branch-Mays GL, Gunsolley JC. The efficacy of bone replacement grafts in the treatment of periodontal osseous defects. A systematic review. *Ann Periodontol* 2003;8:227-265.
- 18- Murphy KG, Gunsolley JC. Guided tissue regeneration for the treatment of periodontal intrabony and furcation defects. A systematic review. *Ann Periodontol* 2003;8:266-302.
- 19-Bassam Michael Kinaia, Jacob Steiger, Anthony L. Neely, Maanas Shah, and Monish Bhola. Treatment of Class II Molar Furcation Involvement: Meta-Analyses of Reentry Results. *J Periodontol* 2011; 82:413-428
- 20-Sculean A, Windisch P, Döri F, et al. Emdogain in regenerative periodontal therapy. A review of the literature. *Fogorv Sz* 2007;100(5):220-32.
- 21-Camelo M, Nevins ML, Schenk RK, et al. Clinical, radiographic and histologic evaluation of human periodontal defects treated with Bio-Oss and Bio-Gide. *Int J Periodontics Restorative Dent* 1998;18(4):321-31.
- 22-Sculean A, Stavropoulos A, Windisch P, et al. Healing of human intrabony defects following regenerative periodontal therapy with a bovine derived xenograft and guided tissue regeneration. *Clin Oral Investig* 2004;8:70-4.
- 23- Houser BE, Mellonig JT, Brunsvold MA, et al. Clinical evaluation of anorganic bovine bone xenograft with a bioabsorbable collagen barrier in the treatment of molar furcation defects. *Int J*

- Periodontics Restorative Dent 2001;21:161-9.
- 24-N.K Sowmya, A.B.Tarun Kumar, D.S. Mehta.Clinical evaluation of regenerative Potential of type I collagen collagen membrane along with xenogenic bone graft In the treatment in the treatment of intrabony defects assessed with surgical re-entryAnd radiographic linear and densitomericanalysis. J Indian Soc Periodontol, 2010;14:23-29.
- 25-Sachin S. Shivanaikar, Mohamed Faizuddin. Treatment of periodontal bony defect with bovine derived xenograft and in combination of platelet rich plasma-A case report Archives of Oral Sciences & Research AOSR 2012;2(2):98-102.
- 26- Reddy KP, Nayak DG, Uppoor AS. A clinical evaluation of anorganic bovine bone graft plus 10% collagen with or without a barrier in the treatment of class II furcation defects. J Contemp Dent Pract 2006;15;7(1):60-70.
- 27- Taheri M, Molla R, Radvar M,. An evaluation of bovine derived xenograftwith and without a bioabsorbable collagen membrane in the treatment of mandibular Class II furcation defects.Aust Dent J 2009;54(3):220-7.
- 28-Machtei EE. Outcome variables for the study of periodontalregeneration. Ann Periodontol 1997;2:229-239.
- 29-Jepsen S, Eberhard J, Herrera D, Needleman I. A systematic review of guided tissue regeneration forperiodontal furcation defects. What is the effect ofguided tissue regeneration compared with surgicaldebridement in the treatment of furcation defects?JClinPeriodontol 2002;29(Suppl. 3):103-116
- 30-Armitage, G. C. (1999) Development of a classification system for periodontal diseases and conditions. Annals of Periodontology 1999; 4 ,1-6.
- 31-Silness J. &Loe, H. Periodontal disease in pregnancy. II. Correlation between oral hygiene and periodontal condition. Acta Odontologica Scandinavica(1964)122,121-135.
- 32- Loe H.,J.Silness: Periodontal disease in pregnancy.1-Prevalence and severity.Acta Odont .Scand 1963; 21:533-551.
- 33-Sanders JJ, Sepe WW, Bowers GM, Koch RW, Williams JE,Lekas JS, MellonigJT,Pelleu GB Jr, Gambill V. Clinical evaluation of freeze-dried bone allografts in periodontal osseous defects. III. Composite freeze-dried bone allografts with and withoutautogenous bone grafts. J Periodontol 1983: 54: 1-11.
- 34-Carols Solís, Antonio Santos, José Nart, and Deborah Violant. 0.2% Chlorhexidine Mouthwash With an Antidiscoloration System Versus 0.2% Chlorhexidine Mouthwash: A Prospective Clinical Comparative Study.J Periodontol2011, 82, 80-85.
- 35-Garrett S, Bogle G. Periodontal-regeneration.A review of flap management. Periodontol 2000 1993: 1: 101-108.
- 36-Huynh-Ba G, Kuonen P, Hofer D, Schmid J, Lang NP, Salvi GE. The effect of Periodontal therapy on the survival rate and incidence of complications of multirooted teeth with furcation involvement after an observation period of at least 5 years:a systematic review.JClinPeriodontol 2009; 36: 164-176.
- 37-Del PelosoRibeiro, E., Bittencourt, S., Nociti, F. H. Jr., Sallum, E. A., Sallum, A.W. &Casati, M. Z. Comparative study of ultrasonic instrumentation for the nonsurgicaltreatment of interproximal and noninterproximal furcation involvements. J Periodontology 2007 ;78, 224-230.

38-Cristiano Tomasi and Jan L. Wennström .Locally Delivered Doxycycline as an Adjunct to Mechanical Debridement at Retreatment of Periodontal Pockets: OutcomeAt furcation Sites. J Periodontol 2011, 82, 2, 210-218.

39-Banyaratavej P,WangHL. Collagen membranes:A review. J Periodontol 2001; 72:215-29.

40-Yukna RA. Clinical evaluation of HTR polymer bone replacement grafts in human mandibular Class II molar furcations. J Periodontol 1994;65:342-349.

41-Simonpietri-C JJ, Novaes AB Jr., Batista EL Jr., Filho EJ. Guided tissue regeneration associated with bovine-derived anorganic bone in mandibular Class II furcation defects.6-month results at re-entry. J Periodontol 2000;71:904-911.

42-Ak.Khoshkhoo Nejad, SH. Mohseni SalehiMonfared, M. Rooeintan. Bio-oss in treatment of Furcation Class II Deffects and Comparison with Coronally Positioned Flap. Journal of Dentistry, Tehran University of Medical Sciences 2004; 1,26-31.