

Surgical Exposure and Orthodontic Treatment of Impacted Maxillary Central Incisors. A Case Report

Khudair A Al-Jumaili
BDS, CES, DScO (Prof)

Enas T Al-Jwary
BDS, MSc (Lec.)

Hind T Jarjees
BDS, MSc (Lec.)

Dept of Pedod, Orthod, and Prev Dentistry
College of Dentistry, University of Mosul

Dept of Pedod, Orthod, and Prev Dentistry
College of Dentistry, University of Mosul

Dept of Pedod, Orthod, and Prev Dentistry
College of Dentistry, University of Mosul

الخلاصة

الأهداف: هذا البحث وصف حالة فتاة تبلغ الحادية عشرة من العمر تعاني من انضمار القواطع الدائمة الأولى مع وجود سنين إضافيين. عملية الفتح الجراحي وسحب الأسنان المطمورة بعد رفع الأسنان الإضافية جراحياً تمت مناقشتها في هذا البحث. المواد والطرق: المتابعة السريرية والإشعاعية والعلاج أجريت في فرع التقويم وفرع جراحة الوجه والفكين في كلية طب الأسنان /جامعة الموصل. تمت عملية رفع الأسنان الإضافية وبعدها بفترة أجريت عملية الكشف عن الأسنان المطمورة وسحبها بجهاز التقويم الثابت. نتائج هذه الدراسة أظهرت نجاح سحب الأسنان المطمورة مع سلامة اللثة المحيطة بالأسنان. استنتج من هذا الدراسة إمكانية استخدام جهاز التقويم الثابت لسحب الأسنان المطمورة بعد كشفها جراحياً.

ABSTRACT

Aims: This report describes a case of eleven years old female with impacted maxillary central incisors and presence of two supernumerary teeth. The surgical exposure and orthodontic traction of bilaterally impacted central incisors after removal of impacted supernumerary teeth is presented in this report. **Materials and Methods:** Clinical, radiographic follow-up and treatment was conducted at the department of orthodontic and maxillofacial surgery in the college of dentistry, mosul university. The surgical removal of supernumerary teeth done then surgical exposure and orthodontic traction done. **Results:** The impacted maxillary central incisors were successfully positioned and presented an acceptable gingival contour after treatment. **Conclusion:** Maxillary permanent central incisors were successfully positioned in the maxillary arch by surgical exposure and orthodontic traction, which showed good stability.

Keywords: Impacted teeth, maxillary central incisor, supernumerary teeth, odontoma

Al-Jumaili KA, Al-Jwary ET, Jarjees HT. Surgical Exposure and Orthodontic Treatment of Impacted Maxillary Central Incisors. A Case Report. *Al-Rafidain Dent J*. 2013; 13(2): 259-265.

Received: 12/2/2012

Sent to Referees: 13/2/2012

Accepted for Publication: 1/4/2012

INTRODUCTION

Although impaction of a permanent tooth is rarely diagnosed during the mixed dentition period, an impacted central incisor is usually diagnosed accurately when there is delay in the eruption of the tooth.⁽¹⁾ Many patients with impacted maxillary central incisors are referred to orthodontists by general practitioners or pediatric dentists because parents are concerned about the impaction of an incisor in the early mixed dentition, even though its occurrence is less frequent.⁽²⁻³⁾ The frequency of maxillary incisor impaction ranges from 0.06% to 0.2% and the most common causes of impaction seem to be odontoma, supernumerary teeth, and loss of space. Impac-

tions caused by disturbances in the eruption path related to crowding are somewhat less common.⁽⁴⁾ alteration in the eruption path or formation of scar tissue due to trauma or premature loss of the primary incisors, and abnormal root angulation or dilaceration; Other causes are apical follicular cysts that prevent normal eruption⁽⁵⁻⁷⁾ In clinical practice, the treatment of the impaction of permanent teeth caused by supernumerary teeth is frequently prolonged. This requires the setting of certain guidelines in the treatment of tooth impaction caused by supernumerary teeth. Spontaneous eruption of the impacted maxillary incisors there are no doubt has an advantage over its surgical- orthodontic

treatment approach. But is it possible to predict spontaneous eruption of impacted maxillary incisor and its timing after removal of the supernumerary tooth? There is no clear answer yet, because a lot of factors, such as initial location and axial inclination of impacted teeth, lack of space in the dental arch and many others can influence the process.⁽¹⁾

MATERIALS AND METHODS

Case Presentation:

An 11 years old female patient was reported to the Department of Pedodontics, Orthodontics and Preventive Dentistry,

College of Dentistry, University of Mosul with the chief complaint of missing permanent maxillary central incisors. No previous history of trauma to the dental or facial region was reported and her medical history showed no contraindications to orthodontic treatment. Intraoral examination showed Patient was having Angle's class I molar relationship of right side and unilateral cross bite of left side, the permanent lateral incisors erupted in maxillary arch and the lower permanent anterior teeth erupted in the mandibular arch Figure (1).

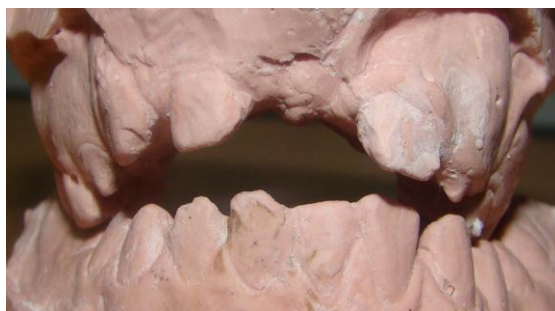

Figure (1): The Cast of the Patient Before Treatment.

Diagnosis and treatment planning

The orthopantomogram Figure (2) demonstrated both maxillary central incisors were impacted due to the presence of two impacted supernumerary teeth located in their eruption path. The impacted maxil-

lary central incisors were positioned vertically, and the supernumerary teeth were placed between the crowns of the impacted central incisors.

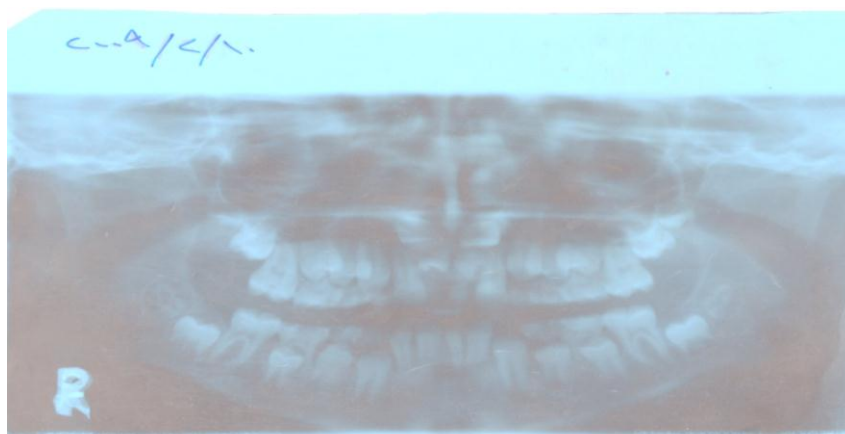


Figure (2): Orthopantomogram of the Patient Before Treatment.

To confirm the position of supernumerary teeth, upper occlusal radiograph, Figure (3) taken which showed the presence of

supernumerary and impacted permanent central incisor teeth on the labial side.

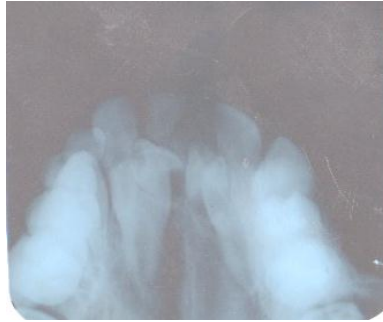


Figure (3): Occlusal View of the Patient Before Treatment.

For the treatment of impacted incisors different options were discussed. Out of which three treatment alternatives were explained to the patient and her parents.

1. Extraction of the impacted central incisor along with mesiodense and restoration with a bridge or an implant later when active growth period had ceased.
2. Surgical extraction of supernumerary teeth and wait for normal eruption of Central incisors.
3. The surgical extraction of supernumerary teeth followed by surgical exposure of

impacted central incisors and alignment of the impacted incisor into the arch using fixed orthodontic treatment.

Treatment Progress

The patient was sent to the Department of Oral and Maxillofacial Surgery to remove the supernumerary teeth. Local anaesthesia was administered and the surgeon raised a mucoperiosteal flap to remove supernumerary teeth. a sufficient amount of bone was removed with a round bur and then surgical removal of supernumerary teeth was done Figure (4).

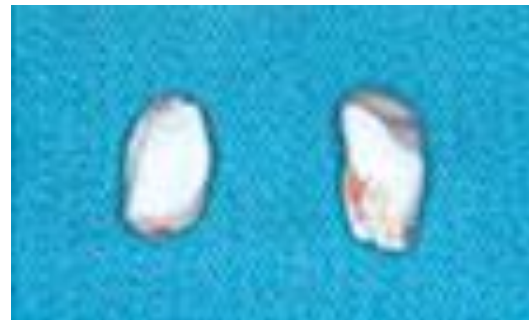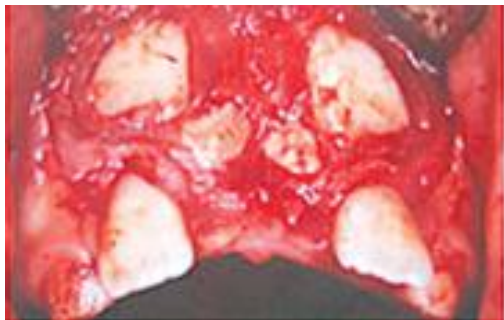


Figure (4): Surgical Removal Of Supernumerary Teeth.

After two months ,the patient recall and another orthopantomogram taken, there is no spontaneous eruption of im-

pacted central incisors .Then after eight months follow up Figure (5).

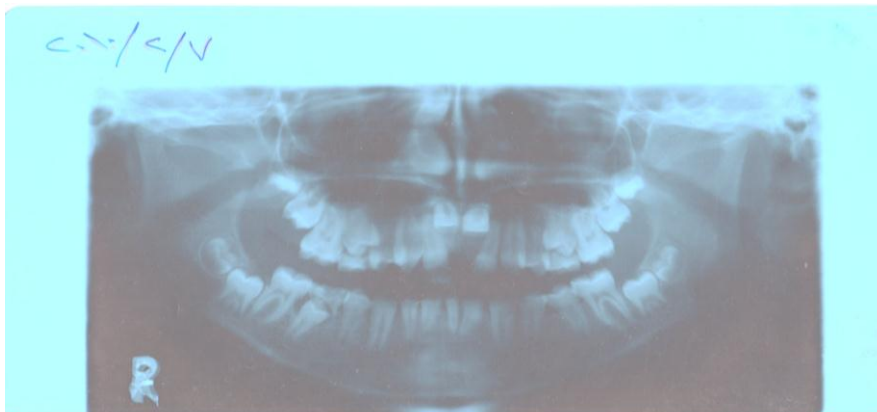


Figure (5): Orthopantomogram of the Patient Show No Spontaneous Eruption.

After eruption of all remaining permanent teeth had occurred, a fixed appliance was subsequently placed on the upper arch by the orthodontist to create adequate space for the impacted central incisors. A 0.0180*0.0250 slot straight wire appliances were placed on the two maxillary permanent lateral incisors, canines and premolars. The initial leveling was performed with a 0.016-inch Ni-Ti wire, followed by

a 0.016-inch stainless steel wire then 0.016*0.022-inch superelastic nickel titanium used for final leveling and alignment. A 0.016*0.022 inch stainless steel wire with an open coil spring between the two lateral incisors. By activating the open coil spring, adequate space for aligning the impacted incisor was obtained Figure (6), the treatment for this step take four months.

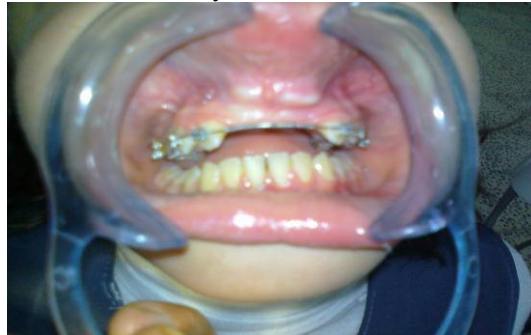

Figure (6): Orthodontic Appliance with Open Coil Spring .

The patient was transferred to the oral surgeon for exposure of the impacted incisor. Local anesthesia was administered and the surgeon raised a mucoperiosteal flap, bracket was bonded at the time of surgery to the labial surface of the crowns

of the impacted central incisors. A 0.010-inch ligature wire ligated on them. The flap was reclosed and sutured, leaving a tied ligature wire with a hook protruding through the mucosa Figure (7).

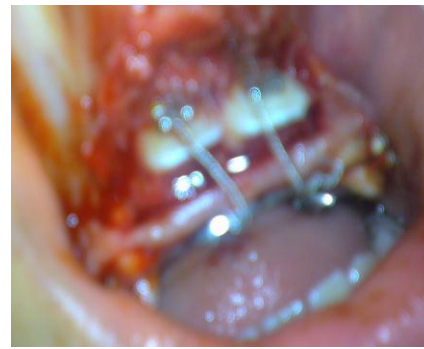
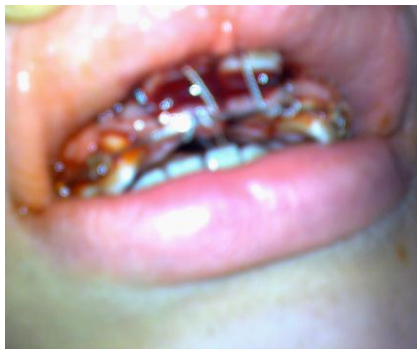
Figure (7): Surgical Exposure of Impacted Teeth.

The patient was recalled after 2 weeks and orthodontic traction was started. The extrusion force applied on the impacted central incisor in the present case was very light and measured in the range of 40-50 grams and measured by tension gauge (anthogyr, France). As the tooth moved downward, the ligature wire was cut shorter to maintain the effective force until the impacted teeth became exposed to the oral environment. When the impacted teeth exposed to the oral environment, the

bracket was then rebonded to its correct position on incisors so that the tooth could be properly positioned. The final alignment was completed with 0.014 inch NiTi arch wire followed by 0.016 x 0.022 inch NiTi wire.

The finishing and detailing of the arches was done using full dimension arch-wire after proper positioning of incisors. This treatment was taken approximately 9 months to bring the incisor in proper position. The total treatment time

from placement of the fixed appliance to it

RESULTS

The impacted maxillary central incisors were successfully positioned into proper alignment through the crown exposure and the conventional ligature traction. The exposed incisors presented an acceptable

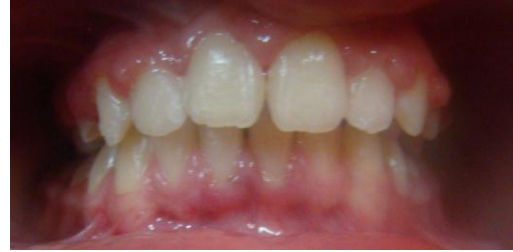
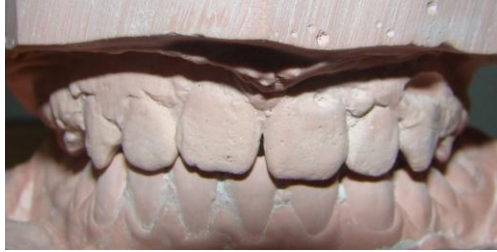
Figure (8): The Case After Treatment.

DISCUSSIONS

Supernumerary teeth can affect the normal position and eruption of adjacent teeth and often require clinical intervention, this reported by Harris and Clark.⁽⁸⁾ Rajab and Hamdan⁽⁹⁾ concluded that the most common complication due to presence of supernumerary teeth is the failure of eruption of maxillary incisors. The treatment protocol available for management of impacted permanent teeth due to supernumerary teeth are diverse. Methods of management of impaction due to supernumerary tooth are; removal of supernumerary teeth or tooth only, removal of supernumerary teeth and bone overlying impacted teeth, incision of fibrous tissue over the alveolar ridge to promote the eruption with or without orthodontic traction, this reported by Regezi *et al.*,⁽¹⁰⁾ and Bhat.⁽¹¹⁾ Spontaneous eruption of impacted maxillary incisors occurs in 54-76% of cases when supernumerary tooth is removed and if there is enough space in the dental arch, this result reported by Crawford⁽¹²⁾ and Smailiene *et al.*,⁽¹⁾ However, research data by Witsenburg *et al.*,⁽¹³⁾ and Mason *et al.*,⁽¹⁴⁾ indicate that the spontaneous eruption of impacted maxillary incisor may take up to 3 years and sometimes orthodontic treatment is necessary to achieve adequate alignment of the erupted tooth in the dental arch.

If the root of the impacted tooth is still developing, the tooth may erupt normally; but once the root apex has closed, the tooth has lost its potential to erupt, this

is removal take 14 months.

gingival contour after treatment and sufficient amount of attached gingiva Figure (8) Radiographically, the newly positioned incisor reveals an intact straight root and no apparent root resorption .

result concluded by Kokich and Mathews.⁽¹⁵⁾ In the present case the root formation was almost complete and because of its rotation and labial placement, it was not desirable to wait for spontaneous eruption.

After thorough clinical and radiographic examination, it was decided that the present case required a combination approach comprising of both surgical and orthodontic treatment to bring an un-erupted maxillary central incisor into position as done by various authors like Cangialosi,⁽¹⁶⁾ Kamakura *et al.*,⁽⁵⁾ Kocadereli and Turgut.⁽¹⁷⁾ Surgical exposures of impacted incisors or surgical repositioning have also been used to bring impacted teeth into occlusion, this method cited by Kamakura *et al.*,⁽⁵⁾ Kocadereli and Turgut⁽¹⁷⁾ and Shetty *et al.*⁽¹⁸⁾

Combination approach using conservative surgical treatment and careful orthodontic management to bring tooth into good position in the dental arch has also been reported with success by Cangialosi,⁽¹⁶⁾ Hemalatha and Balasubramaniam,⁽¹⁹⁾ Chew and Ong.⁽²⁰⁾ Hence, extraction of the impacted supernumerary tooth was done and was followed by an innovative orthodontic traction of the unerupted permanent central incisor to bring the tooth into proper position in the arch.

Three accepted ways of surgical exposure have been suggested by Becker⁽²¹⁾ as:
a. Circular excision of the oral mucosa immediately overlying the impacted tooth.
b. Apically repositioning of the raised flap

that incorporates the attached gingiva overlying the impacted tooth.

c. Closed eruption technique in which the raised flap that incorporates attached gingiva is fully replaced back in its former position after an attachment has been bonded to the impacted tooth.

The closed eruption technique has been favored by many clinicians who claim that the aesthetic and periodontal outcome is far more superior when compared with the circular excision and apically positioned flap technique like Lin⁽⁶⁾ Uematsu *et al.*,⁽³⁾ and Paola *et al.*⁽²²⁾ In the presented case closed eruption technique was used for better and esthetic gingival margin. At the end of the treatment, patient showed normal clinical crown length with acceptable gingival contour.

The extrusion force applied on the impacted central incisor in the present case was very light and measured in the range of 40-50 grams, this result cited by Chawla and Kapur⁽²³⁾ but in the present case the patient was 12 years old at the time of initiation of the treatment. In our view, forces for traction greater than 50 grams should not be applied as it may be the cause of non-vitality as reported by Uematsu *et al.*⁽³⁾ In the present case the duration of treatment was around 8-9 months and the aligned maxillary incisors remained vital and responded normally to percussion and mobility and sensitivity testing as reported by Kumar.⁽²⁴⁾

Smailene *et al.*,⁽¹⁾ cited that early diagnosis of the maxillary central incisor impactions with surgical removal of supernumerary tooth coupled with adequate space, spontaneous eruption of the impacted maxillary central incisors occurs. Bayram *et al.*,⁽²⁵⁾ reported that if the impacted tooth is diagnosed at a later stage with its root completely formed or if present in the unfavorable position, combination of surgical and orthodontic treatment has to be carried out.

CONCLUSION

Supernumerary teeth may result in the non eruption of adjacent permanent incisors. Early diagnosis of the presence and removal of supernumerary teeth is essential. Maxillary permanent central incisors were successfully positioned in the maxil-

lary arch by surgical exposure and orthodontic traction, which showed good stability.

REFERENCES

1. Smailene D, Sidlauskas A, Bucinskiene J. Impaction of the central maxillary incisor associated with supernumerary teeth: Initial position and spontaneous eruption timing. *Somatologica, Baltic Dental and Maxillofacial Journal*. 2006; 8(4): 103- 107
2. Becker A. Early treatment for impacted maxillary incisors. *Am J Orthod Dentofacial Orthop*. 2002;121:586-587.
3. Uematsu S, Uematsu T, Furusawa K, Deguchi T, Kurihara S. Orthodontic treatment of an impacted dilacerated maxillary central incisor combined with surgical exposure and apicoectomy. *Angle Orthod*. 2004; 74: 132-136.
4. Özer M, Ener I. Bilaterally Impacted Maxillary Central Incisors: Surgical Exposure and Orthodontic Treatment: A Case Report. *J Contemp Dent Pract*. 2006 September;7(4):098-105.
5. Kamakura S, Matsui K, Katou F, Shirai N, Kochi S, Motegi G. Surgical and orthodontic management of compound odontoma without removal of the impacted permanent tooth. *Oral Surg Oral Med Oral Pathol*. 2002; 94:540-2
6. Lin Y T. Treatment of an impacted dilacerated maxillary central incisor. *Am J Orthod Dentofacial Orthop*. 1999; 115: 406 – 9 .
7. Lips A R, Antunes L A , Pedro R L , Costa M C and Buchler E K . Treatment of an impacted dilacerated maxillary central incisor in mixed dentition . *Braz J Dent Traumat*. 2011; 2(2):71-74.
8. Harris EF, Clark LL. An epidemiological study of hyperdontia in American blacks and whites. *Angle Orthod*. 2008; 78:460-465.
9. Rajab LD, Hamdan M. Supernumerary teeth: review of the literature and a survey of 152 cases. *Int J Paediatr Dent*. 2002; 12(4): 244-254.
10. Regezi JA, Sciubba JJ, Jordan RCK. *Oral Pathology: Clinical Pathologic Correlations*. 4th^{ed}. Saunders: Elsevier Science. 2003. Pp: 367-384.

11. Bhat M. Supplemental mandibular incisor. *J Indian Soc Pedod Prev Dent.* 2006; (special issue): 20–23.
12. Crawford LB. Impacted maxillary central incisor in mixed dentition treatment. *Am J Orthod Dentofacial Orthop.* 1997;112:1-7.
13. Witsenburg B, Boering G, Witsenburg B. Eruption of permanent impacted incisor after removal of supernumerary teeth. *Int J Oral Surg.* 1981; 10: 423-31.
14. Mason C., Azam N., Holt R.D., Rule D.C. A retrospective study of unerupted maxillary incisors associated with supernumerary teeth. *Br J Oral Maxillofac Surg.* 2000; 38: 62-5.
15. Kokich V G and Mathews D P. Surgical and orthodontic management of impacted teeth. *Dent Clin North Am.* 1993; 37:181-204.
16. Cangialosi TJ. Management of a maxillary central incisor impacted by a supernumerary tooth. *J Am Dent Assoc.* 1982; 105(5): 812-814.
17. Kocadereli Ý, Turgut MD. Surgical and orthodontic treatment of an impacted permanent incisor: case report. *Dent Trauma.* 2005; 21:234–239.
18. Shetty R M , UDixit H. R, Shivaprakash P K, Kau B. Impaction of the Maxillary Central Incisor Associated with Supernumerary Tooth: Surgical and Orthodontic Treatment: case report. *People's Journal of Scientific Research.* 2011; 4(1): 51-56
19. Hemalatha R and Balasubramaniam R M. Cleidocranial dysplasia: A case report. *J Indian Soc Pedod Prev Dent.* 2008; 26(1): 40-43.
20. Chew MT and Ong MM. Orthodontic-surgical Management of an Impacted Dilacerated Maxillary Central Incisor: A Clinical Case Report. *Pediatr Dent.* 2004; 26(4): 341-344
21. Becker A. The orthodontic treatment of impacted teeth. Mosby; 1998. p. 53-85.
22. Paola C, Alessandra M, Roberta C. Orthodontic treatment of impacted dilacerated maxillary incisor. *J Clin Pediatr Dent.* 2005; 30: 93-97.
23. Chawla HS, Kapur A. Orthodontic management of faciolingual horizontally impacted maxillary central incisor. *J Indian Soc Pedod Prev Dent.* 2009; 27(1): 65-69.
24. Kumar S. Combined Orthodontic and Surgical Treatment of Impacted Maxillary Central Incisors allied with Impacted Supernumerary Tooth – A Case Report. *Orthod CYBER J.* 2010(January).
25. Bayram M, Özer M, Sener I. Bilaterally Impacted Maxillary Central Incisors: Surgical Exposure and Orthodontic Treatment: A Case Report. *J Contemp Dent Pract* 2006 September; (7)4:098-105.