

MANAGEMENT OF CRISES DURING ANESTHESIA AND SURGERY. PART VI: DIFFICULT INTUBATION

Salam N Asfar[@] & Jasim M Salman[#]

[@]MB, ChB, MSc, Professor of Anesthesiology, College of Medicine, University of Basrah, Basrah, Iraq.

[#]MB, ChB, DA, FICMS, Lecturer & Consultant Anesthesiologist, College of Medicine, Basrah University and ALSadir Teaching Hospital, Basrah.

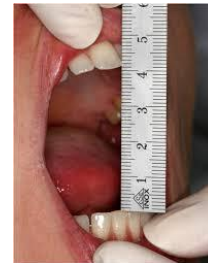Difficult intubation occurs relatively commonly in association with general anaesthesia. Its true incidence is unknown but is estimated to be 1–3%. Approximately half of all cases are not predicted¹. A difficult intubation can be anticipated in a number of circumstances including a previous history of difficulty with intubation, syndromes known to be associated with difficulty to intubate, and some pathoanatomical states involving the head and neck region. Less reliable are anatomical characteristics which may be sought at preoperative assessment including interincisor distance², Palm print³ and prayer's signs⁴, head extension degree, thyromental distance⁵ and the relative tongue/pharyngeal size⁶ (Mallampati test).

Inter-incisor distance

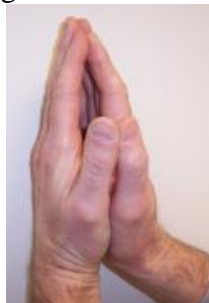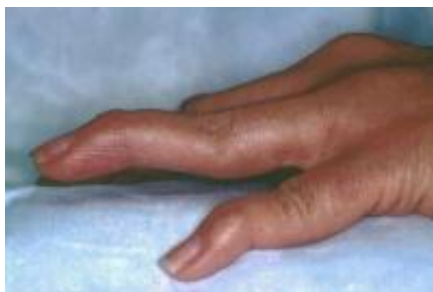Inter-incisor distance with maximal mouth opening

< 3 cm: difficult laryngoscopy

< 2 cm: difficult LMA insertion



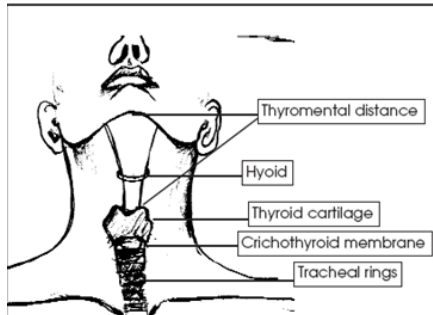
Other ways to anticipate difficult intubation in diabetics and patients with rheumatoid arthritis are the palm print and prayer signs.



Palm Print Test: The palm and fingers of the dominant hand of the patient is painted with black writing ink using a brush. The patient then press the hand firmly against a white sheet of paper on a hard surface. Scoring is done as: Grade 0: All phalangeal areas visible. Grade1: Deficiency in the inter-phalangeal areas of 4th and/or 5th digit. Grade2: Deficiency in the inter-phalangeal areas of 2nd to 5th digit. Grade 3: Only the tips of digits seen.

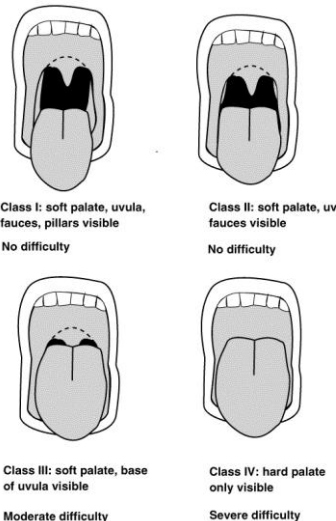
The prayer's sign: Patients with stiff joints syndrome have difficulty in approximating their palms and cannot bend their fingers backwards.

Thyromental distance: The thyromental distance is the inframental distance anterior to the larynx which determines how easily the laryngeal and pharyngeal axes will fall into line with atlanto-occipital extension. A distance of 6 cm (approximately three finger breadths) suggests laryngoscopy may be difficult.



Wilson scoring system: Wilson and colleagues⁶ found five useful risk factors, The risk factors identified were as follows: Weight; Head and neck movement; Jaw movement (mandibular protrusion, inter-incisor gap); Prominent maxillary teeth (“buck teeth”); Receding mandible.

Mallampati test: Mallampati and colleagues^{6,7} described clinical signs to predict difficult intubation in 1983: The patient sits upright, head in the neutral position. The mouth is opened as widely as possible and the tongue is maximally protruded, without phonating. The observer sits opposite at eye level and inspects the pharyngeal structures. The airway is classified according to the structures seen. Mallampati et al described three grades, but the commonly used assessment consists of four grades as modified by Samsoon and Young⁸. The four grades are as follows: (I) soft palate, fauces, uvula, pillars; (II) soft palate, fauces, uvula; (III) soft palate, base of uvula; (IV) soft palate not visible at all. It should be noted that a class I view nearly always predicts easy intubation and a class IV view a difficult intubation. Intermediate classes (II and III) are associated with a wide range of degrees of difficulty with intubation.



If the anaesthetized patient cannot breathe spontaneously or the lungs cannot be otherwise ventilated by mask, then a series of manoeuvres must immediately be undertaken ending if necessary, in gaining direct transtracheal access to the airway¹⁰.

REMEMBER, PATIENTS DO NOT DIE FROM FAILED INTUBATION – ONLY FAILED VENTILATION

Always have skilled assistance, preferably another anesthesiologist, when difficulty is expected or the patient's cardiorespiratory reserve is low.

MANAGEMENT

Call for skilled assistance. Call for the difficult intubation trolley. Maintain oxygenation at all times. Have someone feel the pulse and call out the SpO₂. If you can ventilate by face mask, consider waking up the patient OR maintaining anesthesia and trying to intubate.

Try basic maneuvers first: Optimize the head and neck position. Try glottis visualization maneuvers. Try a well-lubricated gum elastic bougie or stylet. Try different laryngoscope blades.

If these fail: Consider inserting laryngeal mask airway (LMA). Consider other techniques: Blind nasal and Retrograde Lighted stylet.

If an LMA is in place, consider whether to proceed and whether steps should be taken to secure endotracheal intubation. Confirm correct placement of endotracheal tube.

Further care: Review the situation. Exclude other complications. There is a risk of awareness. Go and see the patient in the ward. Explain again and reassure them. Advise them to warn future anesthesiologists.

Notes:

Techniques will vary with the experience and familiarity with the techniques of the individual anesthesiologist.

Avoid multiple attempts at laryngoscopy/intubation, as this may cause bleeding and laryngeal oedema, worsening the situation. This may require 2 assistants: one to apply pressure to the larynx and/or the back of the neck, the second to lift the head up.

Glottis visualization can be optimized by laryngeal manipulation which can be performed using three different maneuvers: External Laryngeal Manipulation (ELM), the Backward, Upward, Rightward Pressure (BURP) and cricoid pressure (Sellick) maneuver^{8,9}. Cricoid pressure and BURP are commonly used for airway management but several studies have showed that cricoid pressure or BURP might worsen laryngeal visualization¹⁰⁻¹², ELM is designed to improve laryngeal view with the cooperation between the anesthesiologist and the assistant during direct laryngoscopy¹³⁻¹⁶.

The most common aid to facilitate successful intubation in the AIMS series was the gum elastic bougie (46%), followed by a stylet (23%).

The LMA is easy to insert and works well in about 95% of cases. It does not provide airway protection.

Airway trauma, pulmonary aspiration, post-obstructive pulmonary oedema and cardiovascular signs and symptoms.

Provide written advice and document this in the medical record.

Document the problem in the case notes and give the patient a letter to warn future anesthesiologists. If a particular precipitating event was significant, or a particular action was useful in resolving the crisis, this should be clearly explained and documented.

Pediatric airway is grossly different from adults. They have proportionately large head, the larynx is situated more cephalad, the tongue occupies a proportionately large part of oral cavity, epiglottis is large, floppy and difficult to lift using conventional laryngoscopic technique¹⁷⁻²². The main concern during tracheal intubation in children is to use age-appropriate equipment and position for laryngoscopy in order to obtain good view of the glottis and perform safe and successful intubation²³. An optimal view of the glottis can be obtained using the anesthesiologist own left little finger for patients in whom the epiglottis could not be visualized with standard laryngoscopy to improve the laryngoscopic view²⁴.

Factors contributing to intubation difficulty

Obesity. Limited neck mobility. Limited mouth opening. Inexperience of laryngoscopist. Inadequate assistance. Drug errors. Poor/prominent dentition. Equipment deficiencies. Laryngeal tumour. Recent traumatic intubation. Neck mass. Masseter spasm. Cervical spine instability, facial carcinoma, congenital microsomia, ruptured trachea, and hair in a “bun” were also reported.

Complications of difficult intubation

Arterial desaturation. Esophageal intubation. Central cyanosis. Regurgitation. Bronchospasm. Laryngospasm. Dental damage. Endobronchial intubation. Epistaxis. Pharyngeal trauma. Awareness. lacerated tongue. oesophageal tear. Cardiac arrhythmias and electrocardiographic signs of ischaemia, bigeminy and supraventricular tachycardia. Cardiac arrest.

REFERENCES

- Otto CW. Tracheal intubation. In: Nunn JF, Utting JE, Brown BR, eds. General anaesthesia, 5th ed. London: Butterworths, 1989:533–4.
- Zawawi KH, Al-Badawi EA, Lobo SL, Melis M, and Mehta NR. An index for the measurement of normal maximum mouth opening. *J Can Dent Assoc.* 2003 Dec;69(11):737-41.
- Vani V V, Kamath S K, Naik L D. The palm print as a sensitive predictor of difficult laryngoscopy in diabetics: a comparison with other airway evaluation indices. *J Postgrad Med* 2000;46:75
- Hogan K, Rusy D, Springman SR. Difficult laryngoscopy and diabetes mellitus. *Anesth Analg* 1988; 67:1161-1165
- Patil VU, Stehling LC, Zauder HL. Fiberoptic endoscopy in anesthesia. Chicago: Year Book Medical Publishers, 1983.
- Mallampati SR, Gatt SP, Gugino LD, et al. A clinical sign to predict difficult tracheal intubation: a prospective study. *Can Anaesth Soc J* 1985;32:429–34.
- Visvanathan T, Kluger MT, Webb RK, et al. Crisis management during anaesthesia: obstruction of the natural airway. *Qual Saf Health Care* 2005;14:e2.
- Samsoon GL, Young JR. Difficult tracheal intubation: a retrospective study. *Anaesthesia* 1987;42:487–90.
- Knill, RL. Difficult laryngoscopy made easy with a “BURP”, *Can J Anaesth* 1993; 40: 279–82.
- Georgescu A, Miller JN, Lecklitner ML. The Sellick maneuver causing complete airway obstruction. *Anesth Analg.* 1992;74:457
- Snider DD, Clarke D, Finucane BT. The “BURP” maneuver worsens the glottic view when applied in combination with cricoid pressure. *Can J Anaesth.* 2005;52:100–104.
- Randell T, Maattanen M, Kytta J. The best view at laryngoscopy using the McCoy laryngoscope with and without cricoid pressure. *Anaesthesia* 1998; 53: 536–539.
- Ho AM, Chung DC. Use of external laryngeal manipulation to facilitate laryngoscopy. *Ann Emerg Med* 2003; 41:587-588.
- Knopp RK. External laryngeal manipulation: a simple intervention for difficult intubations. *Ann Emerg Med* 2002; 40:38-40.
- Harioka T, Nomura K, Mukaida K, Hosoi S, Nakao S. The McCoy laryngoscope, external laryngeal pressure, and their combined use. *Anaesth Intensive Care.* 2000;28:537–539.
- Ochroch EA, Levitan RM. A videographic analysis of laryngeal exposure comparing the articulating laryngoscope and external laryngeal manipulation. *Anesth Analg* 2001; 92:267-270.
- Stringer KR, Bajenov S & Yentis SM. Training in airway management. *Anesthesia* 2002;57:967-983.
- Cheney FW, Posner KL, Caplan RA. Adverse respiratory events infrequently leading to malpractice suits. A closed claims analysis. *Anesthesiology.* 1991;75:932–939.
- Bingham RM, Proctor LT. Airway Management. *Pediatr Clin North Am* 2008; 55: 873-886.
- Infosino A. Pediatric upper airway and congenital anomalies. *Anesthesiol Clin North America* 2002; 20: 747-766.
- Ramesh S, Jayanthi R, Archana SR. Paediatric airway management: What is new? *Indian J Anaesth.* 2012 Sep-Oct; 56(5): 448–453.
- Amir S.H., Ali Q.E., Firdaus U. and Azhar A.Z.. Lateral cheek retraction – a simple maneuver in aiding laryngoscopy and intubation in paediatric patients *Jurnalul Român de Anestezie Terapie Intensivă* 2012 Vol.19 Nr.1, 35-38.
- Achen B, Terblanche OC, Finucane BT. View of the larynx obtained using the Miller blade and paraglossal approach, compared to that with the Macintosh blade. *Anaesth Intensive Care.* 2008;36:717–21.
- Salman JM.: External laryngeal pressure by left little finger as an aid to facilitate visualization of the larynx during endotracheal intubation in children. *Journal of the Arab Board of Health Specializations* 2014, Vol.15, No.1, 8-13.